

Acute Cholangitis due to Anomaly of Right Hepatic Artery

Ramin Niknam¹, Laleh Mahmoudi², and Reza Ansari³

¹ Gastroenterohepatology Research Center, Shiraz University of Medical Sciences, Shiraz, Iran

² Department of Clinical Pharmacy, School of Pharmacy, Shiraz University of Medical Sciences, Shiraz, Iran

³ Digestive Disease Research Institute, Tehran University of Medical Sciences, Tehran, Iran

Received: 19 Jun. 2012 ; Accepted: 26 Feb. 2013

Abstract- Acute cholangitis (AC) is commonly observed in general practice with different causes. We report a case of recurrent AC caused by anomaly of the right hepatic artery, as a rare underlying condition.

© 2013 Tehran University of Medical Sciences. All rights reserved.

Acta Medica Iranica, 2013; 51(12): 910-912.

Keywords: Cholangitis, Hepatic artery

Introduction

AC may present with different underlying causes such as stone, tumor or trauma (1). We present a 35-year-old woman with recurrent acute cholangitis. After evaluation, compression of common bile duct by anomaly of the right hepatic artery was diagnosed as an underlying cause of AC in this patient.

Case Report

A 35-year-old woman presented with recurrent acute cholangitis and weight loss during last six months. She was icteric and chronically ill. Liver biochemical tests showed cholestatic pattern but CA19-9 and CEA were in normal range. Ultrasonography revealed dilatation of the intrahepatic bile ducts. In endoscopic retrograde cholangiopancreatography (ERCP), the dilatation of intrahepatic bile ducts was confirmed (Figure 1). Percutaneous transhepatic cholangiography (PTC) and therapeutic biliary drainage was performed (Figure 2).

In surgical laparotomy, anomaly of the right hepatic artery was seen which compressed common hepatic duct and cause stricture in compression site. Cholecystectomy and hepaticojejunostomy was performed. After surgery, the samples of hepatic and cystic ducts and gallbladder were sent for histopathology evaluation that showed only inflammation and fibrosis without any evidence of malignancy (Figures 3 and 4). Compression of common bile duct by anomaly of the right hepatic artery diagnosed as an underlying cause of AC in this patient.

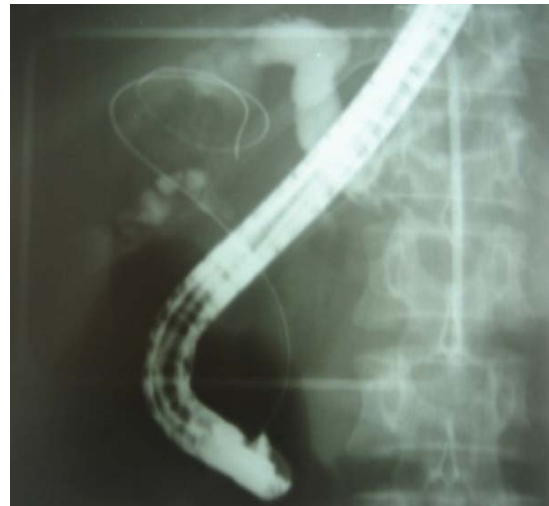

Figure 1. ERCP showed dilation of intrahepatic bile ducts.

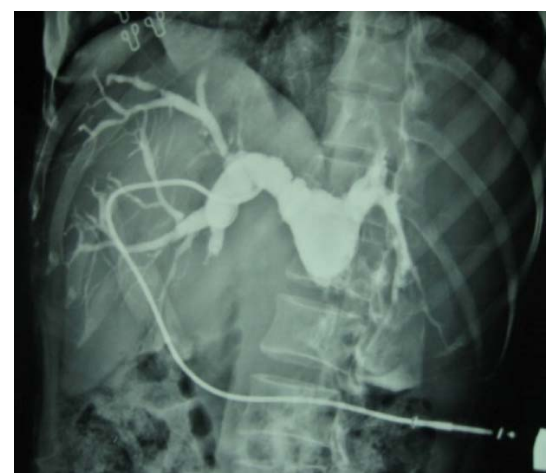


Figure 2. PTC before surgery showed dilation of intrahepatic bile ducts.

Corresponding Author: Laleh Mahmoudi

Department of Clinical Pharmacy, School of Pharmacy, Shiraz, Iran. P. O. Box 1583; 71345 Shiraz, Fars, Iran
Tel: +98 711 2424128 Ext: 292, Fax: +98 711 2424126, E-mail: Mahmoudi_l@sums.ac.ir

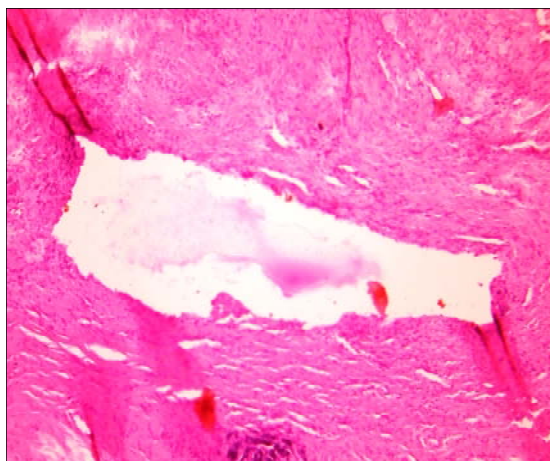


Figure 3. Histological assessment of common hepatic duct revealed the fragments of fibrotic tissue with hemorrhage and foci of bile.

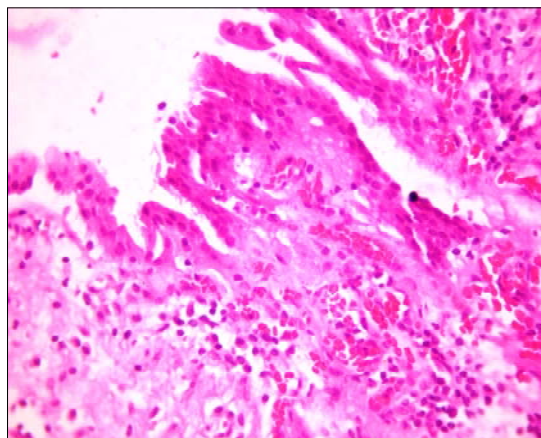


Figure 4. Histological assessment of cystic duct revealed acute on chronic inflammation.

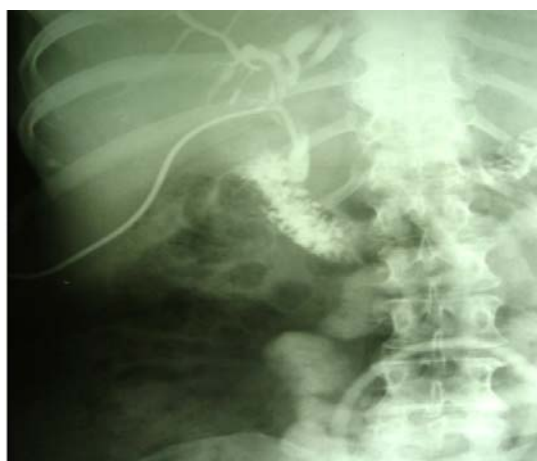

Figure 5. PTC one week after surgery showed proper biliary drainage.

Two weeks after surgery, patients' symptoms resolved and the liver function tests returned to normal values. In follow up, PTC was performed one week after

surgery that showed proper biliary drainage (Figure 5). The postoperative period was uneventful and follow-up at 12 months was excellent

Discussion

AC is a bacterial infection that occurs when the biliary tract obstructs. Choledocholithiasis is the common leading cause of acute cholangitis (1). Benign or malignant strictures, sclerosing cholangitis, Caroli's disease, biliary intervention, and oriental cholangiohepatitis are the other etiology of the attacks of AC (3,5). Oriental cholangiohepatitis, also known as, recurrent pyogenic cholangitis is a complex disease with associations with parasites, infections and nutritional deficiency (5). Although AC is usually diagnosed clinically by presence of the Charcot triad, diagnostic criteria at an international meeting held in Tokyo is also useful (1,2). Different therapeutic modality include antibiotic therapy, endoscopic or radiologic therapy, surgery, and transplantation was used for patients with AC (1,5).

A multidisciplinary approach involving gastroenterologists, interventional radiologists, and surgeons is recommended in severe case of AC (5).

Therapeutic endoscopic biliary drainage is a safe option in selected patients with AC (1,4). Hypoalbuminemia, thrombocytopenia and concomitant medical problem are risk factors of poor outcome after

therapeutic endoscopic biliary drainage (4). Although most patients with AC respond to antibiotic therapy and biliary drainage, mortality reported up to 10% (1).

References

1. Lee JG. Diagnosis and management of acute cholangitis; *Nat Rev Gastroenterol hepatol* 2009;6(9):533-41.
2. Wada K, Takada T, Kawarada Y, Nimura Y, Miura F, Yoshida M, Mayumi T, Strasberg S, Pitt HA., Gadacz TR, Büchler MW, Belghiti J Santibanes ED, Gouma DJ, Neuhaus H, Dervenis C, Fan ST, Chen MF, Ker CG., Bornman PC, Hilvano SC, Kim SW, Liau KH, Kim MH. Diagnostic criteria and severity assessment of acute cholangitis: Tokyo Guidelines; *J Hepatobil Pancreat Surg* 2007;14(1):52-8.
3. Gigot JF, Leese T, Dereme T, Coutinho J, Castaing D, Bismuth H. Acute Cholangitis Multivariate Analysis of Risk Factors; *Ann Surg* 1989;209(4):435-8.
4. Lai EC, Mok FP, Tan ES, Lo CM, Fan ST, You KT, Wong J. Endoscopic Biliary Drainage for Severe Acute Cholangitis; *NEJM* 1992;326(24):1582-6.
5. Heffernan EJ, Geoghegan T, Munk PL, Ho SG, Harris AC. Recurrent Pyogenic Cholangitis: From Imaging to Intervention; *AJR* 2009;192(1):28-35.