

Unsuspected Glomus Tumor on the Right Wrist: Case Report

Wendel dos Santos Furtado¹, Cacilda Joyce Ferreira Silva Garcia², Vitorino Modesto dos Santos³, Marcos Emanuel Alcântara Segura², Ricardo Monte Serrate Silva¹, Guilherme Dantas Roriz¹

¹ General Surgery Division from Armed Forces Hospital (HFA), Brasília-DF, Brazil

² Pathology Division of Armed Forces Hospital, Brasília-DF, Brazil

³ Department of Internal Medicine, Armed Forces Hospital and Catholic University of Brasília, Brasília-DF, Brazil

Received: 24 Apr. 2017; Accepted: 30 May. 2017

Abstract- Glomus tumor is not a rare vascular entity, which is often subungual or found in the reticular dermis of the extremities. Glomus tumors are most frequently benign and solitary. Affected patients classically complain of extremely painful episodes. Symptoms occur spontaneously or elicited by local compression and cold environment, in special if the tumor has an acral location. A 50-year-old woman was referred to our hospital due to chronic atypical episodes of wrist pain. A deep-seated subcutaneous nodule was detected in her right wrist, and a surgical biopsy was performed. Histopathology study revealed a benign glomus tumor with a solid pattern. Misdiagnoses involving glomus tumors with atypical symptoms or tumors developing in unusual sites are emphasized.

© 2018 Tehran University of Medical Sciences. All rights reserved.

Acta Med Iran 2018;56(12):807-810.

Keywords: Glomus tumor; Vascular neoplasm; Wrist

Introduction

Glomus tumors are uncommon mesenchymal neoplasms involving specialized arteriovenous shunts (glomus), which have a rich nerve supply and are related to control of blood flow and thermal regulation (1,2). They are more often solitary, small, and benign (1,3), and predominantly affect middle-aged woman (4,5). The classical location of glomus tumors is on the skin, more frequently of distal portions of fingers and toes, and at nail beds (1,2,4,5). The most characteristic feature of glomus tumor is intense local pain, which appears either spontaneously or following direct compression and exposition to cold environments (1,3-5). Typical pain is circumscribed to the tumor area, but proximal irradiation may occur (4). The vast majority of glomus tumors are found on the extremities, and the lesion commonly develops appearing like a little purple spot, which can be observed through the nail plate. Misdiagnosis involving tumors with atypical symptoms and in unusual sites is emphasized.

Case Report

A 50-year-old woman presented with a longstanding pain in the right wrist, in addition to paresthesias with

bilateral radiation to arms. In another medical service, these symptoms had been attributed to anxiety associated with a possible cervical (C5-C7) radiculopathy. She was a right-handed nurse with antecedent arterial hypertension under clinical control. Physical examination detected a subcutaneous nodule at the medial third of the right wrist, which was mobile and painful on palpation, but there was no elicited pain by flexion, extension or lateral movements of the joint. Laboratory exams showed hemoglobin: 14 g/dl, hematocrit: 43%, leukocytes: 4,000 /mm³, platelets: 330,000/mm³, glucose: 109 mg/dl, calcium: 10.7 mg/dl, sodium: 140 mmol/dl, potassium: 4.2 mmol/dl, urea: 29 mg/dl, creatinine: 0.7 mg/dl, ALT: 21 U/l, AST: 30 U/l, alkaline phosphatase: 48 U/l, GGT: 24 U/l, uric acid: 6.7 mg/dl, C-reactive protein: 7.29 mg/dl, fibrinogen: 294 mg/dl, TSH: 1.96 µU/ml, free T4 ng/dl, cholesterol 241 mg/dl, triglycerides: 178 mg/dl, HDL: 49 mg/dl, VLDL: 35.6 mg/dl, and LDL: 156.4 mg/dl. The nodule was excised, with very difficult access to the lesion, which was located very close to the flexor tendons. Six samples of yellowish elastic tissue (the major diameter 0.7x0.5x0.3 cm) were sent to histopathology study, which revealed a monotonous proliferation of small round cells around medium sized vessels (Figure 1A). These cells showed regular round nuclei and a rim of

Corresponding Author: V. Modesto dos Santos

Department of Internal Medicine, Armed Forces Hospital and Catholic University of Brasília, Brasília-DF, Brazil
Tel: + 55 61 39662103, Fax: + 55 61 32331599. E-mail address: vitorinomodestos@gmail.com

Glomus tumor

eosinophilic cytoplasm (Figure 1B), consistent with glomus cells. No tumor cell necrosis or mitotic activity was observed. The diagnosis of benign glomus tumor with a solid pattern was established. Surgical margins could not be evaluated due to accentuated fragmentation of the biopsy specimen. Therefore, a second surgery was done at the site of the biopsy, with a broader margin of resection (Figure 2) to remove residual tumor tissue. The larger samples of skin (1.5x1.0 cm) and subcutaneous tissue (2.0x1.0x1.0 cm) were submitted to immunohistochemistry examination. Immunostaining

revealed that the tumor was positive for smooth muscle actin (Figure 1C) and vimentin but negative for cytokeratins, S-100, and desmin. A chicken-wire pattern between cells was observed with type IV collagen (Figure 1D). Less than 1% of tumor cells had nuclear MIB-1 positivity demonstrating a low proliferation rate. Diagnosis of glomus tumor was characterized. Patient's immediate postoperative period was uneventful. She was discharged to home with no symptoms and referred to outpatient surveillance under rheumatology and oncology care.

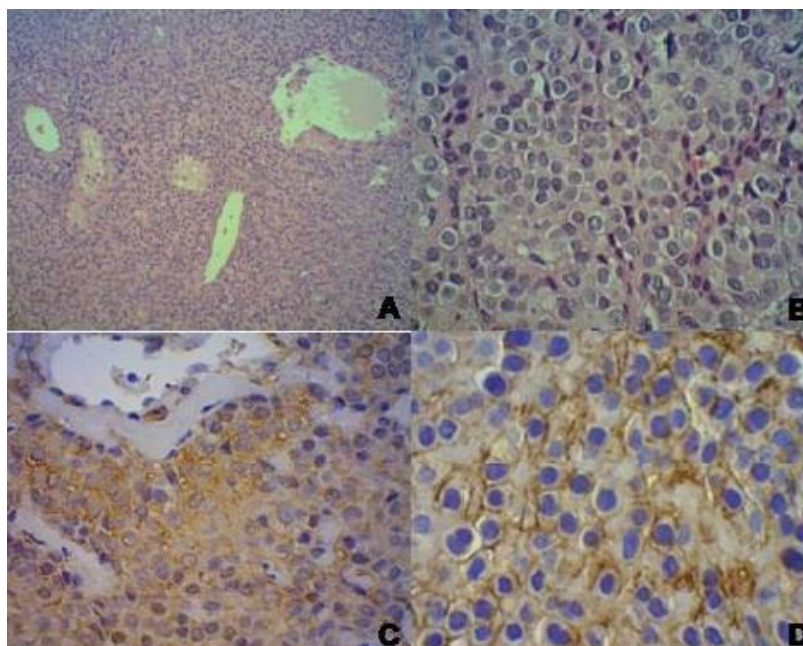


Figure 1. A: Solid proliferation of small cells around dilated vessels (HE x100); B: Small round cells with regular, monotonous nuclei and a rim of eosinophilic cytoplasm (HE x400); C: Smooth muscle actin positivity in glomus cells; D: Immunostaining for type IV collagen

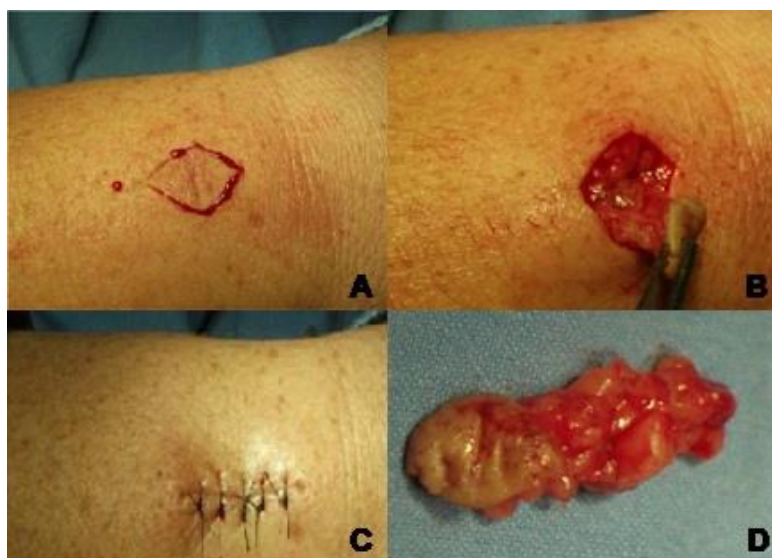

Figure 2. A to C: The main steps of the surgical procedure on the medial third of the right wrist, at the site of the previous biopsy; D: Gross feature of the excised subcutaneous glomus tumor

Discussion

In 1812, William Wood first described the characteristic features of glomus tumors (4,5). Since then, unsuspected cases of this tumor in extradigital locations have been published, emphasizing diagnostic challenges due to the absence of classical features. Glomus tumors represent 1% to 2% of all soft tissue neoplasms (2,5), and 1% to 5% of hand neoplasms (1,5) with a mean diameter of 3-4 millimeters (4). They have been also described in less common regions including nerves, gastrointestinal tract, nose, respiratory tree, eye, kidney, bones, genitalia, chest wall, and buttocks (1-8). Notably, as the wrist pain had no relationship with local compression or cold stimulation, the hypothesis of glomus tumor was not considered with due priority (4,5). The patient here reported had a deep-seated glomus tumor in an uncommon site (9-13) with local pain mimicking neuropathy, radiculopathy or rheumatic condition (4). Following the diagnostic suspicion, clinical evaluation should begin by testing local response to cold and pressure (4,5).

Multiple glomus tumors are exceeding rare, especially those with malignant features (2,6,8) and are managed as high-grade sarcomas (2). Glomus tumors of less common sites can be evaluated by imaging studies to have a better estimation of tumor extension contributing to successful surgical procedures. Nevertheless, the diagnostic specificity of images has been considered limited in this setting (1,3,4). Furthermore, definitive diagnosis should be established based on typical findings of histopathology studies. Surgical excision of tumor constitutes the management of the first choice, and postoperative complications include local relapses (1,2,4,5). Major differential diagnoses of glomus tumors include conditions like lipoma, liposarcoma, angioleiomyoma, hemangiopericytoma, neuroma, schwannoma, melanoma, eccrine spiradenoma, synovial cyst, and tumors of the tendon sheath (1,3-5,14).

Consistent with the literature, our patient was a 50-year-old right-handed woman (5), and the diagnosis of glomus tumor was not established before surgical procedure on her wrist (1). Imaging evaluations were not done like some of the reported cases (5). Accurate evaluation of free surgical margins was not achieved in our patient, because the nodule was deep-seated among tendons, and the sample was very fragmented by excision. Therefore, she underwent a second surgical intervention that was performed with success. Local

recurrence constitutes an infrequent postoperative complication, but this condition is usually related to incomplete removal of the original glomus tumor (1,2,5). Persistence of symptoms in the early postoperative period requires a new surgical exploration, while late recurrences strongly suggest the development of another lesion. Although scarcely reported, malignant glomus tumors constitute an additional concern (2); so, late diagnosis or misdiagnosis of this condition can play adverse role on the outcome (5). Moreover, cases of glomus tumor occurring in less common sites and presenting with atypical features might be under-recognized and/or under reported (5). Case studies can increase the suspicion index about this challenging diagnostic condition. In conclusion, even in the absence of classical features, glomus tumor might be included as a differential diagnosis in patients presenting with unexplained pain in the wrist region (9-13). Enhanced awareness about scarcely reported entities can minimize under-recognition or misdiagnosis and will contribute to the early adoption of the adequate surgical management.

References

1. Buendia GPP, Uribe WAJ, Facioli D, Rodriguez JMF, Gervais J. Glomus tumor: an easy or a difficult diagnosis? *Rev Bras Cir Plast* 2010;25:439-42.
2. De Chiara A, Apice G, Mori S, Silvestro G, Losito SN, Botti G, Ninfo V. Malignant glomus tumour: a case report and review of the literature. *Sarcoma* 2003;7:87-91.
3. Kang G, Park HJ, Kim JY, Choi D, Min BH, Lee JH, Kim KM, Park CK, Sohn TS, Kim S. Glomus tumor of the stomach: a clinicopathologic analysis of 10 cases and review of the literature. *Gut Liver* 2012;6:72-7.
4. Kim YD, Son JS, Lee JW, Han YJ, Choi H, Jeong YJ. Extradigit glomus tumor causing abdominal pain - a case report. *Korean J Pain* 2012;25:108-11.
5. Vanti AA, Cucé LC, Di Chiacchio N. Subungual glomus tumor: epidemiological and retrospective study from 1991 to 2003. *An Bras Dermatol* 2007;82:425-31.
6. Kiyosawa T, Umebayashi Y, Nakayama Y, Soeda S. Hereditary multiple glomus tumors involving the glans penis. A case report and review of the literature. *Dermatol Surg* 1995;21:895-9.
7. Shang Y, Huang Y, Bai C, Dong YC, Zhao LJ, Li Q. Removal of glomus tumor in the lower tracheal segment with a flexible bronchoscope: report of two cases. *Intern Med* 2010;49:865-9.
8. Uchiyama M, Kato T, Kunitani K, Kuwabara K. Multiple glomus tumors in chest wall and buttocks. *Kyobu Geka*

Glomus tumor

2011;64:116-9.

9. Chim H, Lahiri A, Chew WY. Atypical glomus tumor of the wrist: a case report. *Hand Surg* 2009;14:121-3.
10. Horn MS, Pierson DL. A glomus tumor mimicking a peripheral neuropathy. *J Dermatol Surg Oncol* 1980;6:931-3.
11. Joseph FR, Posner MA. Glomus tumors of the wrist. *J Hand Surg Am* 1983;8:918-20.
12. Koibuchi H, Fujii Y, Taniguchi N. An unusual case of a glomus tumor developing in a subcutaneous vein of the wrist. *J Clin Ultrasound* 2008;36:369-70.
13. Peretz E, Grunwald MH, Avinoach H, Halevy S. Solitary glomus tumor. *Australas J Dermatol* 1999;40:226-7.
14. dos Santos VM, de Vasconcelos RA, de Paula FH, Alves Tubino PV, Turra TZ, Gagliardi Castilho I. Coexistence of prostate cancer, gynecomastia, renal failure, melanonychia, and wrist lump. *Arch Iran Med* 2009;12:503-6.