

# Lateral Lower Face and Neck Contouring Following Burn Injury

Sadrollah Motamed<sup>1</sup>, Seyed Mehdi Mousavizadeh<sup>1</sup>, Feyzollah Niazi<sup>1</sup>, Houman Khajouei Kermani<sup>1</sup>,  
Alireza Saberi<sup>1</sup>, and Hassan Motamed<sup>2</sup>

<sup>1</sup> Department of Plastic and Reconstructive Surgery, 15 Khordad Hospital,  
Shahid Beheshti University of Medical Sciences, Tehran, Iran

<sup>2</sup> Department of Emergency Medicine, Ahvaz University of Medical Sciences, Ahvaz, Iran

Received: 7 Nov. 2013; Received in revised form: 1 Jul. 2014; Accepted: 22 Dec. 2014

**Abstract-** The neck is normally a concave and highly mobile structure. Facial and cervical skin is prone to burn scar contracture because of its thin nature. The goal of treatment is to reconstruct this region to achieve a good aesthetic outcome and also normal neck and chin mobilization. This study was conducted to compare the effect of one row of suture and three rows of suture in critical points of the neck to recreate cervicomandibular angle for better contouring of the neck. A cross-sectional study was performed from July 2006 until August 2010. A total of 65 patients underwent lower lateral face and neck burn scar contracture reconstruction. The mean age of participants was 25.5 years old. After designing a local flap, in 31 patients we applied one row of suture. In 34 patients, we used three rows of suture on each side of the neck incorporation with the recipient bed and the flap dermis or capsule to recreate a natural lower lateral face and neck contour ( $P < 0.001$ ). The standard deviation in hospitalization was  $7 \pm 2$  days for group A and  $6 \pm 1$  days for group B. In a two years follow-up, no blunting of cervicomandibular angle occurred and three rows of suture were superior according to present findings.

© 2015 Tehran University of Medical Sciences. All rights reserved.

*Acta Medica Iranica*, 2015;53(4):225-230.

**Keywords:** Cervical flaps; Neck contouring; cervicomandibular angle; Burn scar

## Introduction

Face and neck are prevalently prone to burn injury induced by flame, scald, and caustic agents (1). Contractures in these regions because of chronic burn scar are troublesome, both functionally and aesthetically, not only they restrict neck movements, but also they distort lower lip and limit mandibular movements. As these scars are located in a fairly exposed area of the body, they are easily visible and could cause much embarrassment for the patient (2,3).

The fundamental goal of surgical treatment is to replace this area with a normal skin that is a good match in color, texture and thickness (4). Local flaps from shoulder and pectoral area are good choices and have the mentioned characteristics (5). Tissue expanders are applicable in these cases and provide adequate surface area without compromising vascularity (6,7). The choice of flaps and their priorities and the technical aspects are not within the scope of this article. The important issue during transferring skin flaps to reconstruct cervicofacial scar contracture is blunting of cervicofacial angle and

creation of a web that makes the outcome less desirable aesthetically (8,9).

The neck is normally a concave and highly mobile structure. The normal contour of the neck is a result of dermal attachment to the underlying platysma and mandible that is obviously disappeared while existing scarred tissue and covering with the skin flap (10).

This study was conducted to compare the effect of one row of suture and three rows of suture in critical points of the neck to recreate cervicomandibular angle for better contouring of the neck.

## Materials and Methods

In this interventional, 65 patients with chronic burn scar in cervicofacial region were operated between July 2006 and August 2010. A total of 43 participants were female. Flame injury was the most common etiology (72.3%), followed by scald burn (27.7%).

A certain surgical team performed all the operations. The study was performed according to the protocol of the ethical guidelines of the Declaration of Helsinki.

**Corresponding Author:** S. Motamed

Department of Plastic and Reconstructive Surgery, 15 Khordad Hospital, Shahid Beheshti University of Medical Sciences, Tehran, Iran  
Tel: +98 21 88901108, Fax: +98 21 88909193, E-mail address: S\_Motamed2006@yahoo.com

## Burn injury of face and neck

This research was approved by our local institutional review board. An informed consent was obtained from each patient. The extension of burn injury was lower face to the upper neck in each group. After the reconstruction of cervical skin with a local flap, we used three rows of sutures to recreate cervicomandibular and submental angles in 34 participants and others including 31 patients, we applied just one row suture.

In the three-row suture (group A), the flap dermis or capsule was sutured to the recipient bed at three levels:

- 1- At the level of thyroid cartilage (Figure 1)
- 2- Above the first row at the level of hyoid bone (Figure 2).

- 3-Along the mandibular body (Figure 3)

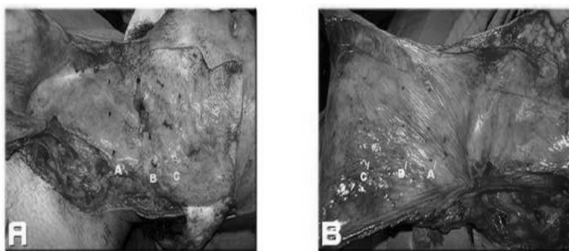


Figure 1. A (points A, B, C of sutures on the neck, lowerface)

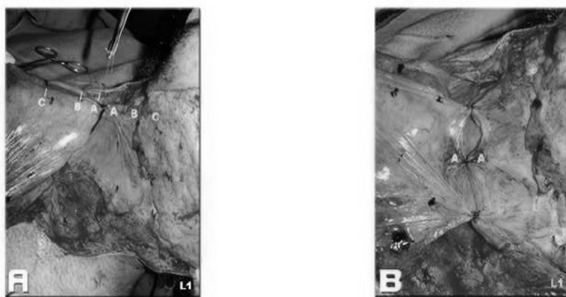


Figure 2. Sutures on the above neck  
A (one AA' suture), B (Three suture AA')

The first row of sutures should be at the level of thyroid cartilage. The second row incorporates the platysma in a recess along the hyoid bone.

Finally, the last rows of suture are applied incorporating periosteum of the mandibular body. Each row consists of multiple sutures (at least three sutures on each side of the neck) (Figure 4).

In the one-row suture group (Group B), only the sutures along the mandibular body (the highest level of sutures) were applied. The early postoperative complications such as infection, bleeding, skin necrosis, and wound dehiscence were recorded.

We used closed suction drains and noncompressive

bulky dressing in all participants. Also, we recommended to the patients to wear soft cervical collars after the operation for four weeks.

Follow up visits was scheduled in the first and second weeks postoperatively and monthly until two years after surgery then results were evaluated.

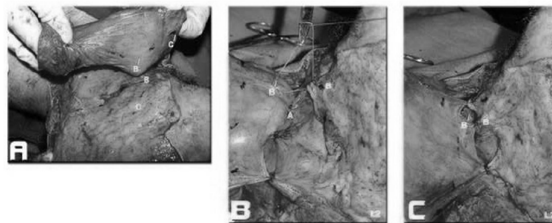


Figure 3. Below mandibular rim  
A (adjust points BB'), B,C (sutures BB')




Figure 4. Border off mandible sutures CC

## Results

A total of 65 patients with lateral lower face and neck burn scar contracture were enrolled in this study of those 43 participants (66.2 %) were female. Flame injury was the most common etiology (72.3%), followed by scald burn (27.7%). In the three – row suture group (Group A), 22 (69%) of participants were female. In the one – the row suture (group B), 21 (61.7%) participants were female. The demographic characteristics of current patients are presented in Table 1. The complications and outcomes are compared between two groups in Table 2. Hospitalization was  $7 \pm 2$  days for group A and  $6 \pm 1$  days for group B. The average cervicomandibular angle was improved by 25 degrees in group A and 10 degrees in group B.

In the follow – up visits up to two years after the operation, no blunting of the cervicofacial angles occurred in the three- row suture group and a natural appearing cervical contour were obtained and the result were gratifying (Figure 5 and 6). On the other hand, in

the one-row suture group, less than optimal aesthetic result was obtained and some residual blunting of the cervicofacial angle was observed (Figure 7 and 8), and addition of two-row suture had the greatest effect on the appearance and concavity of the neck (Figure 9).

The most complications included hematoma (7.6%) and seroma (6.1%) infection (4.6%) and in five participants distal necrosis of the flap was managed conservatively and recovered completely.

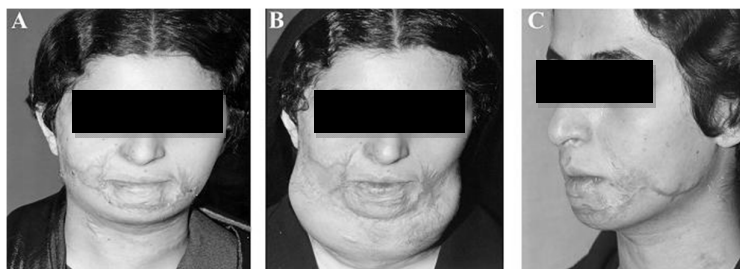


Figure 5. A) A 24-year-old woman with lower face Burn-before tissue expander implant, B) After bilateral tissue Expander implantation, C) 3-month after Reconstruction of cervicofacial angel with three row suture technique

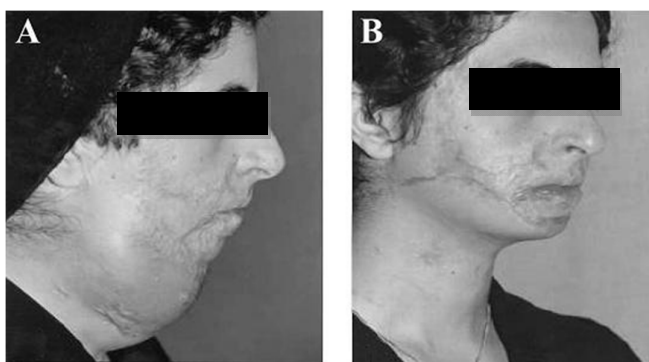


Figure 6. Comparison between before and 6 months after surgery that presents good contour of cervico facial angle with three row sutures

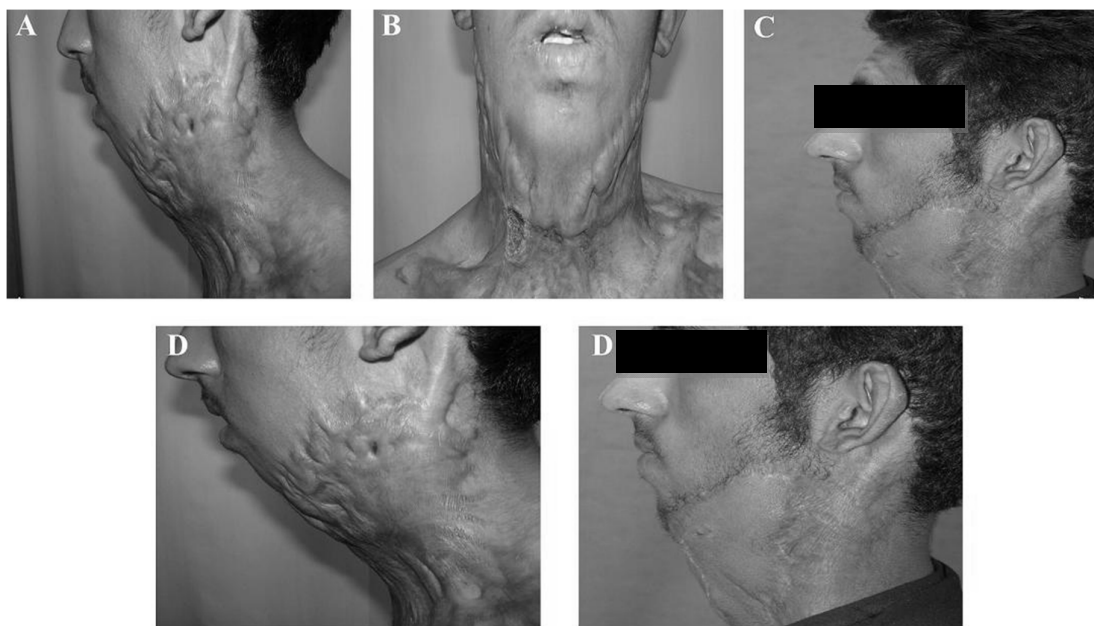
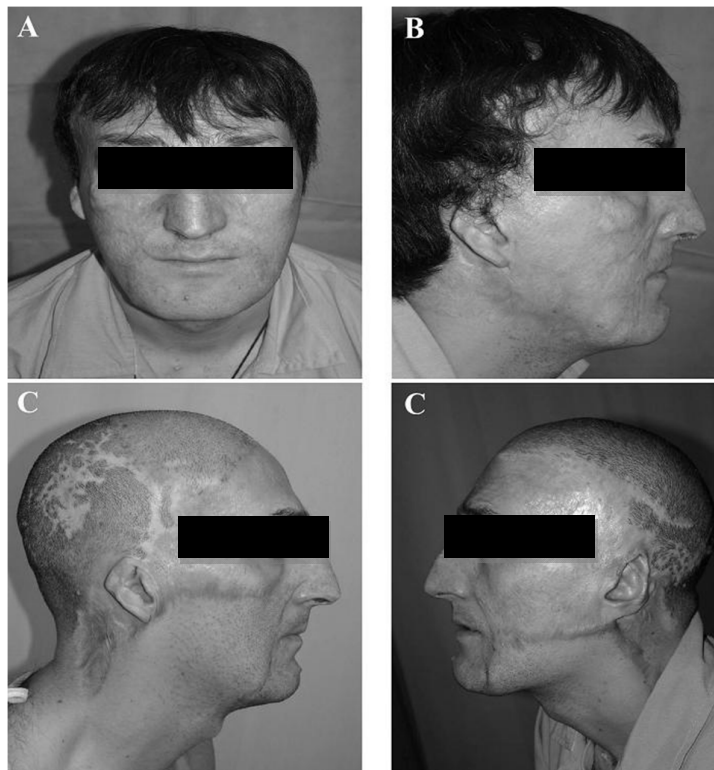


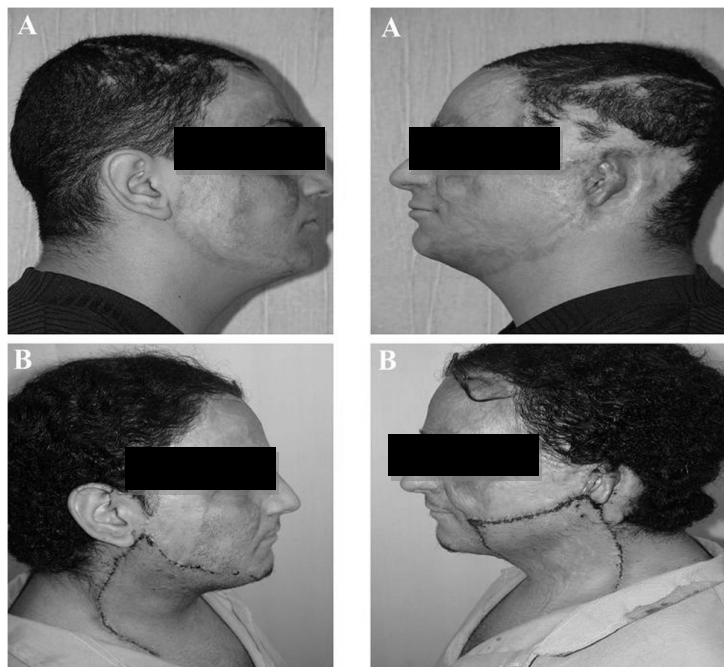Figure 7. 25 year-old man with Burn scar deformity

A )Lat view, B) Ant view, C) 3 month after Reconstruction of cervicofacial angle with one-row suture, D) This figures shows there is not a good contour change with one-row suture technique

**Burn injury of face and neck**



**Figure 8.** A) 27-year-old man with facial burn scar deformity of cervico facial angel  
B) After T.E implantation, C) 4 months after recreation of cervico facial angel with three the –row suture



**Figure 9.** A) A 20-year-old man with bilateral facial and neck burn,  
B) After the reconstruction with three –row suture the concavity and contour of the cervicofacial angles are restored

**Table 1. Preoperative demographic of both groups**

Variables	Group B	Group A	P. value
Age ( year )	30±11	33±7	0/191
Sex((M/F) [n]	10/21	12/22	0/999
Type of Burn with			
Scald injury [M/F]	7/15	8/17	0/999
Flame injury [M/F]	3/6	4/5	

Group A=Three – row anchoring suture, Group B=one – row anchoring suture,  
n = Number, m= Male, f= Female

**Table 2. Early complications and outcomes after operation in both groups**

Variables	Group A n=34	Group B n=31	P. value
Operative time (hr)	2 hr±0 /80	2 hr ± 0/50	0/999
Hematoma	Yes	2(%)	3(%)
	No	32(%)	28(%)
Seroma	Yes	2(%)	2(%)
	No	32(%)	29(%)
Infection	Yes	1	2
	No	33	29
Flap necrosis	Yes	2	3
	No	32	28
Pleasing	Yes	26	14
	No	8	17
Satisfaction	Yes	28	19
	No	6	12

## Discussion

In the literature there are a large number of studies regarding chronic burn scar reconstruction in cervicofacial region and their management, but few studies have addressed recreation of cervicofacial and cervicomandibular angle.

Most of them advocate local flaps; while others prefer full-thickness skin graft or even free flap (11). Among their locoregional flaps are more appropriate as they have better color and texture match and because of their availability (12). Also, local flaps need a less sophisticated procedure in comparison to free flaps.

For local flaps, tissue expansion or standard delaying and prefabrication are usually advised (13). In this article, we have emphasized the role of applying an anchoring suture to create a pleasing cervicofacial angle and better lower lateral neck and face contour.

Cervicofacial angle recreation has been quoted in chronic burn scar reconstruction, but little is mentioned about the key points of applying these adhesion sutures (14).

The contouring and shaping of flaps in the cervicofacial region are the key element to successful reconstruction. Anchoring or tenting suture of the flap (without tension) to the periosteum of the mandible and the underlying platysma, improves the cervicofacial

region aesthetically.

As mentioned previously normal contour can be optimized by this novel method that can highlight normal neck contour in cervicofacial angle. This modified technique adds a third dimension to neck recontouring, and it adds support and definition to the neck contour. Cervicofacial region is undoubtedly one of the most important areas to be concerned about, both functionally and aesthetically, for reconstruction following burns. In addition to color and texture match, this is still another critical issue in creating a natural looking cervical region, and it is the three dimensional anatomy of this region. The elegance of the cervical region is due to a certain balance between concave and convex surfaces, and is based on the presence of a well – defined cervicomenal angle generally between -110 degrees, the triple suture technique (3 –row sutures) for neck contouring creates a median vector of traction and preserves the neck contouring and concavity in cervicofacial angle (15).

Recreation of angles in cervicofacial region should become an integral part of burn scar reconstruction in this region. Every effort should be made to reproduce the normal convexities and concavities of the neck, otherwise, sagging of the flaps causes blunting of cervicofacial angle and patient dissatisfaction. So, we strongly recommend applying these key sutures in the

## Burn injury of face and neck

mentioned three strategic points.

Ethical approval: the ethical approval was given for our study.

## References

1. Margulis A, Agam k, Icekson M, et al. The expanded supraclavicular flap, prefabricated with Thoracoacromial vessels, for Reconstruction of post burn anterior cervical contractures. *Plastic Reconst Surg* 2007;119(7):2072 -7.
2. Laredo Ortiz C, Valverde Carrasco A, Novo Torres A, et al. Supra clavicular bilobed fasciocutaneous flap for post burn cervical contractures. *Burns* 2007;33(6):770 -5.
3. Rashid M, Zia -Ul- Islam M, sarwar S. The expansile supra clavicular arteryflap for release of post-burn neck contractures. *Plast Reconstr Surg* 2006;59(10):1094-101.
4. Motamed S, Davami B, Daghighaleh H. Trapezius musculo cutaneous flap in sever shoulder and neck burn. *BURNS* 2004;30(5):426-80.
5. Palloa N, Machens H, Rennekamplto, et al. The fasciocutaneous supraclavicular artery island flap for releasing post burn mentosternal contractures. *Plast Reconstr Surg* 1997;99(7):1878-84.
6. Yang JY, TasiF C, Chana JS, et al. Use of free thin anterolateral thigh flaps combined with cervicoplasty for reconstruction of post burn anterior cervical contractures. *Plast Reconstr Surg* 2002 ;110(1):39-46.
7. Sinsel NK, Opdebeeck H, Lesaffre E, et al. Maxillofacial growth after neck burn injury at young age: An experimental study in the rabbit. *J Plast Reconstr Surg* 1995;96(7):1588-99.
8. Hurlin Foley K, Doyle B, Paradise P, et al. Use of an improved watusi collar to manage pediatric neck burn contracture. *J Burn Care Rehabil* 2002;23(3):221-6.
9. Rose EH. Aesthetic restoration of severely disfigured face in burn victims; a comprehensive strategy. *Plast Reconstr Surg* 1995;96(7):1573-85.
10. Knipper P, Mitzv, Lemerle JP. Experimental cervicoplasty: correction of the cervicomental angle by postero-superior suspension of the hyoid bone. A study of 20 anatomical dissections. *Ann chirplast Esthet* 1996;41(1):37-44 .
11. Iwuagwu FC, Wilson D, Bailie F. The use of skin graft in post burn neck contracture release. *Plast Reconstr Surg* 1999;103(4):1198-204.
12. Achauer BM, editor. *Burn Reconstruction*. New York, Ny: Thieme Medical Pub; 1991: p. 1-12.
13. Adant JP, Bluth F, Jacquemin D. Reconstruction of neck burns. a long term comparative study between skin grafts, skin expansion and free flaps. *Acta chir Belg* 1998;98(1):5-9.
14. Iviz S. Toledo. *Refinements in facial and body contouring*. Illustrated by Arhor Baldissara. 1st ed. Sao Paulo: Lippincott-Raven; 1999: p. 251-365.
15. Stephen Prendiville, Kokoska MS, Hollenbeak CS, et al. A comparative study of surgical techniques on the cervicomental angle in human cadavers. *Arch facial Plast Surg* 2002;4(4):236-42.