

Non-Pathogenic Heterozygous Polymorphism in *RAB27A* Gene in a Case Suspicious to Griscelli Syndrome, Type II

Aziz Eghbali¹, Farzaneh Rahmani², Zahra Aryan^{2,3}, Arndt Borkhardt⁴, Parin Tanzifi⁵, Samaneh Zoghi^{6,7}, Nima Rezaei^{2,8,9}

¹ Department of Pediatric Hematology and Oncology, Arak University of Medical Sciences, Arak, Iran

² Research Center for Immunodeficiencies, Children's Medical Center, Tehran University of Medical Sciences, Tehran, Iran

³ Network of Immunity in Infection, Malignancy and Autoimmunity (NIIMA), Universal Scientific Education and Research Network (USERN), Boston, MA, USA

⁴ Pediatric Oncology, Hematology and Clinical Immunology, School of Medicine, Heinrich Heine University, Düsseldorf, Germany

⁵ Department of Pathology, Children's Medical Center, Tehran University of Medical Sciences, Tehran, Iran

⁶ CeMM Research Centre for Molecular Medicine of the Austrian Academy of Sciences, Vienna, Austria

⁷ Network of Immunity in Infection, Malignancy and Autoimmunity (NIIMA), Universal Scientific Education and Research Network (USERN), Vienna, Austria

⁸ Department of Immunology, School of Medicine, Tehran University of Medical Sciences, Tehran, Iran

⁹ Primary Immunodeficiency Diseases Network (PIDNet), Universal Scientific Education and Research Network (USERN), Tehran, Iran

Received: 04 Sep. 2017; Accepted: 13 Mar. 2018

A 3.5-year-old girl, the third child of a second-degree consanguineous marriage, was referred to the outpatient clinic of Children's Medical Center with a history of skin rash, redness and recurrent abscesses (Figure 1-A). She had two apparently healthy siblings, and her family history did not disclose atopy, chronic skin diseases or any other immunological disorders. Her birth weight, height, and head circumference were in normal range, and she had reached developmental milestones as expected.

She was doing well until 6 months of age when she developed warm skin abscesses in her axillary and crural regions and also throughout her legs and hands, which were treated with oral antibiotics. The abscess fluid culture had shown *Staphylococcus aureus* and *Escherichia coli*. She later developed erythematous follicular and papular lesions with scattered blackhead comedons on both thighs, arms, armpits, and groin, along with severe and diffuse pillar keratosis. Moreover, pigmented and scaly areas with patchy appearance were observed, distributed over her scalp, chins, and legs. Keratinization defects had been suspected, and skin biopsy specimen had revealed, irregular acanthosis, focal hypergranulosis, and elongated rete-ridges, in line with ichthyosis like features.

Myeloperoxidase (MPO) staining of skin biopsy had been performed, revealing normal strong brown staining of Azurophil granules in infiltrating neutrophils. She also had a normal Nitroblue tetrazolium test (NBT) (100%) and normal chemotaxis assay (84%) from

previous workups for her skin rash and abscesses.

On the first visit in our outpatient clinic, she appeared with an explicit silvery grey appearance of her eyebrows, eyelashes, and baseline parts of her scalp hairs (Figure 1-B). She had an unusually blonde hair shaft all throughout her scalp, contrary to dark black hair of her parents and siblings. Moreover, pigmented and scaly areas with patchy appearance were distributed over her scalp, chin, and legs. We prepared the whole mount examination of her hair. It revealed a normal variant of blonde hair microscopy with normally distributed melanin in all of the samples (Figure 1-C). Normal hair shaft which is taken from healthy individual is shown in figure 1-D.

She also had documented lymphocytosis from previous complete blood counts (WBC 14,100 per μL , lymph 43% in 9 months and WBC 18,470 per μL , lymph 41.4% at the age of 2), along with a borderline positive C-reactive protein level using semiquantitative method (6 mg/l in 9 months) (Table 1). An abdominopelvic ultrasonographic study during hospital admission in 20 months of age, had revealed mild splenomegaly (35 mm*100 mm) with numerous unspecific calcified granules of less than 3 mm in diameter, in spleen and the liver. No episode of hemophagocytic lymphohistiocytosis (HLH) had been proved for the patient prior to her workup in our clinic.

Corresponding Author: N. Rezaei

Research Center for Immunodeficiencies, Children's Medical Center, Tehran University of Medical Sciences, Tehran, Iran
Tel: +98 21 66929234, Fax: +98 21 66929235, E-mail address: rezaei_nima@tums.ac.ir

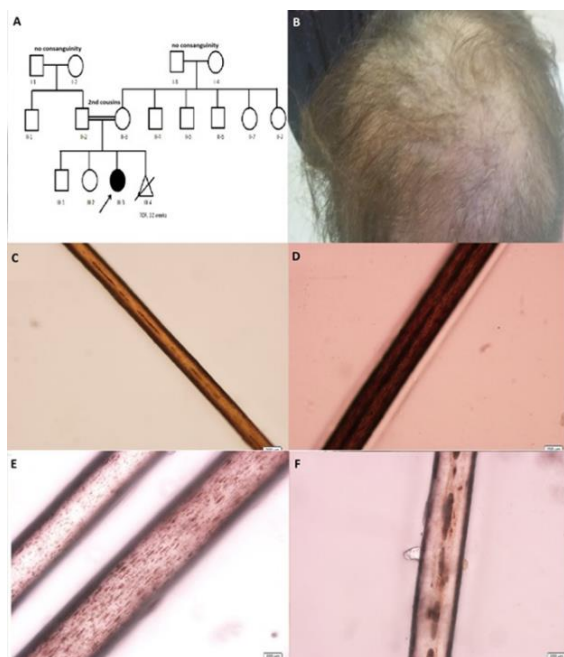


Figure 1. A) pedigree of this family, B) gross appearance of her scalp; she has blonde hair with silvery grey parts at baseline of her hair shafts, C) whole-mount examination of patient hairs, note to the absence of irregular clumps of pigmentation which resulted in apparently normal hair shaft, D) whole-mount examination normal hair shaft took from one of laboratory staff of children's medical center, E) whole-mount examination of a child with Chédiak-Higashi syndrome (CHS), note to regular distribution of small melanin granules throughout the hair shaft, F) whole-mount examination of a child with Griscelli syndrome (GS), note to irregular distribution of clumps of melanin granules around the medulla (D-E obtained from department of pathology, children's medical center)

On immunological workup, markedly elevated IgE level (IgE > 500 (<188 U/L)) had been detected only once by quantitative serum assay (Table 1). Skin Prick testing had been performed according to her non-specific skin rash and elevated immunoglobulin E level, which was negative for cow milk, egg, wheat and other common environmental allergens.

On current physical examination, she had no fever, did not appear ill and had no palpable hepatosplenomegaly or lymphadenopathy. Her lab data revealed a leukocyte count of 13,720 cells/ μ L with an absolute neutrophil count of 6,550 cells/ μ L, hemoglobin of 10.1 g/dL, and a platelet count of 273×10^9 per/ μ L. Due to the patient's persistent leucocytosis (according to all previous documents) and anemia, bone marrow aspiration, and biopsy were performed, where the results were unremarkable for hematologic malignancies or HLH. Flow cytometry of peripheral blood revealed relatively normal lymphocyte subset enumeration (Table

1).

Her history of skin abscesses and abnormal skin keratinization had led to suspicion of immune dysregulation/deficiency syndromes. Allergic dermatitis was ruled out, with negative prick test and skin biopsy results. Skin biopsy and dispersion pattern of her lesions also ruled out atopic dermatitis. MPO staining ruled out myeloid malignancies of the skin. Phagocyte defects and defect in leukocyte motility had been ruled out through NBT and chemotaxis tests, respectively. Inborn keratinization defects are unlikely the diagnosis with non-diagnostic skin biopsy results. Abnormally high IgE levels with immune dysregulation and parental consanguinity raised suspect for an autosomal recessive hyper IgE syndrome (DOCK8 deficiency). Normal T-cell count, the absence of eczema, and abscesses confined to skin with no other infection sites made DOCK8 deficiency improbable (1). In the approach to her cutaneous hypopigmentation and silvery and lighter appearance of the hair shaft and associated immune dysregulations (2) in the absence of other syndromic characteristics (bleeding tendency, psychomotor findings, ectodermal dysplasia, etc.) and a suspicious history for HLH, we suspected the diagnosis of GS. Sanger sequencing of exons of the *RAB27A* gene (plus additional 10 bp at the exon boundaries) was performed to search for possible mutations under suspect in *RAB27A* gene (Griscelli syndrome, type 2), revealing only a 3' prime UTR allelic variant (A) of exon 6, rs1050931. This was a non-pathogenic heterozygous polymorphism at chromosome 15:55497691 G/A, observed in 20-34% of the normal population (3). Also, this mutation was not among recognized susceptibility loci in *RAB27A*, for familial HLH as part of GS type 2.

She has been scheduled on prophylactic antibiotic regimens and during her four-year follow-up in our center, has not experienced skin abscesses without any prophylactic antibiotic therapy.

Partial Oculocutaneous Albinism and Immunodeficiency (OCA-ID) refer to a group of six well-defined autosomal recessive disorders that depict combined characteristics of syndromic albinisms and recurrent infections (4). Defects in lysosomal trafficking are responsible for defective cytotoxic vesicle secretion and antigen presentation in hematopoietic/immune cell lineages and thus a propensity for recurrent infections and bleeding tendency due to platelet dysfunction in these patients. Lysosomal or extra-lysosomal defects in melanosome maturation and secretion result in partial albinism (hypopigmentation) in skin, hair, and eye (5). All three types of GS, CHS, three of the nine types of

Non-pathogenic heterozygous polymorphism

the Hermansky-Pudlack syndrome (HPS) and MAPBP-interacting protein deficiency, are thereby categorized as OCA-ID (4). Defective cytotoxicity in T-cells and NK-cells confer liability for chronic respiratory and cutaneous infections in all of the above syndromes. Inborn, generalized hypopigmentation is another shared feature of these OCA-ID disorders, varying in severity and clinical features between syndromes (6).

CHS and GS may be indistinguishable early in disease course with the history of patients remarkable for recurrent *Staphylococcal* infections, and the silvery-grey hair color. Majority of patients with GS experience an accelerated phase sometime between 6-12 months of age, while HLH might take up to a decade for patients with CHS to occur (6). Analysis of hair shafts either by polarized or light microscopy reveals the regular distribution of small melanin granules in patients with CHS (Figure 1-E), while the irregular pattern of melanin clumps around the hair medulla is pathognomonic for GS (Figure 1-F). No giant granule was reported in MPO staining of skin, and our patient had no ophthalmologic findings. These along with normal whole mount microscopic examination of the hair shaft lowered potentials for CHS to be the diagnosis. Neurological features, as happen with late-onset neuropathies, balance disturbance and cognitive decline in CHS are rare in GS and usually associate with the accelerated phase of HLH.

HPS type 2 and 9 are recognizable from CHS and GS with clinical features of ocular hypopigmentation at birth including nystagmus, iris trans-illumination, and low visual acuity. In contrast, skin and hair color tone is variable in patients with HPS and HLH is rare in these patients.

Among the three types of GS, GS type 1 depicts only primary neurological deficits along with hypopigmentation and no immune dysregulation, while GS type 3 is solely characterized by skin and hair hypopigmentation (6). Based on patients history of recurrent skin abscesses, the absence of severe bleeding diathesis and the OCA-ID our patient was likely to have CHS or GS type 2.

GS type 2 is the result of defective Rab27a protein. Mutations in *RAB27A* that affect its binding sites to

GTP, Myosin 5a or MUNC 13-4, have shown pathogenic relevance to GS type 2 (7,8). What made GS type 2 a suspicious diagnosis for this patients was the vague history of HLH and absence of any accelerated phase until 3.5 years. Her lab data suggested mildly elevated ANC count, lymphocytosis and no thrombocytopenia, inconsistent with the HLH (9). Although most GS type 2 patients experience HLH syndrome, the absence of clinical HLH episodes does not rule out the diagnosis of GS, as some mutations selectively destruct the MUNC 13-4 binding site, conserving the GTPase activity of RAB27A (10). Some episodes of HLH might go undetected or present with self-limiting and mild symptoms in patients (11).

Given high IgE levels, parent consanguinity and a history of skin abscess with *S. aureus* and chronic eczema, the diagnosis of autosomal recessive hyper IgE syndrome was also postulated. The diagnosis of hyper-Immune globulin E syndrome (HIES) remained highly suspected before we ruled combined immune deficiencies associated with DOCK8. Although IgE usually peaks above 2000 IU/ml in patients with HIES (12), most patients with isolated IgE above 2000 IU/ml do not have HIES (13).

Approach to syndromic albinisms will be hard especially in children of Caucasian origin with natural blonde hair. Analysis of the hair shaft by light or polarized microscopy could be beneficial for earlier identification of the disorder and timely initiation of treatment in suspicious patients with syndromic albinism. The pitfall here is that we may face normal hair pigmentation as observed in our patient. Normal heterozygous variant in *RAB27a* also could not help the diagnosis.

As we have faced a diagnostic dilemma in this patient, whole genome sequencing might be a good approach to detect underlying gene defect in this patient.

Acknowledgements

This study was supported by a grant from Tehran University of Medical Sciences (32345).

Table 1. Summary of patient's laboratory and immunological analyses

Complete count differentiation	blood with	Immunoglobulin subtype levels	Reference range	Lymphocyte subset enumeration	%
WBC	18400 per μ L				
Lymphocyte	43%	IgG=848 mg/dL	(250-1190 mg/dL)	CD11a ⁺ /CD11b ⁺ /CD11c ⁺	71%/49%/11%
Neutrophil	55%			CD19 ⁺	26%
Eosinophil	1%	IgE >500	<188 U/L	CD4 ⁺	43%
Haemoglobin	10.2 g/dl	IgA=162 mg/dL	(10-87mg/dL)	CD8 ⁺	17%
MCV/MCH	76 (fL)/ 23(pg)	IgM=187 mg/dL	(24-167mg/dL)	CD3 ⁺	61%
C-reactive protein	6 mg/L			CD16 ⁺ /CD56 ⁺	1

References

1. Chu EY, Freeman AF, Jing H, Cowen EW, Davis J, Su HC, et al. Cutaneous manifestations of DOCK8 deficiency syndrome. *Arch Dermatol* 2012;148:79-84.
2. Vachiramon V. A Concise Approach to Childhood Hypopigmentation. *J Cutan Aesthet Surg* 2013;6:73-4.
3. Sherry ST, Ward MH, Kholodov M, Baker J, Phan L, Smigielski EM, et al. dbSNP: the NCBI database of genetic variation. *Nucleic Acids Res* 2001;29:308-11.
4. Dotta L, Parolini S, Prandini A, Tabellini G, Antolini M, Kingsmore SF, et al. Clinical, laboratory and molecular signs of immunodeficiency in patients with partial oculocutaneous albinism. *Orphanet J Rare Dis* 2013;8:168.
5. Scheinfeld NS. Syndromic albinism: a review of genetics and phenotypes. *Dermatol Online J* 2003;9:5.
6. Lee JYW, Eldeeb MS, Hsu CK, Saito R, Abouzeid SA, McGrath JA, et al. Further evidence for genotype-phenotype disparity in Griscelli syndrome. *Br J Dermatol* 2017;176:1086-9.
7. Shamsian BS, Norbakhsh K, Rezaei N, Safari A, Gharib A, Pourpak Z, et al. A novel RAB27A mutation in a patient with Griscelli syndrome type 2. *J Invest Allergol Clin Immunol* 2010;20:612-5.
8. Menasche G, Feldmann J, Houdusse A, Desaynard C, Fischer A, Goud B, et al. Biochemical and functional characterization of Rab27a mutations occurring in Griscelli syndrome patients. *Blood* 2003;101:2736-42.
9. Ménasché G, Pastural E, Feldmann J, Certain S, Ersoy F, Dupuis S, et al. Mutations in RAB27A cause Griscelli syndrome associated with haemophagocytic syndrome. *Nat Genet* 2000;25:173-6.
10. Cetica V, Hackmann Y, Grieve S, Sieni E, Ciambotti B, Coniglio ML, et al. Patients with Griscelli syndrome and normal pigmentation identify RAB27A mutations that selectively disrupt MUNC13-4 binding. *J Allergy Clin Immunol* 2015;135:1310-8.e1.
11. Wang Y, Wang Z, Zhang J, Wei Q, Tang R, Qi J, et al. Genetic Features of Late Onset Primary Hemophagocytic Lymphohistiocytosis in Adolescence or Adulthood. *PLoS One* 2014;9:e107386.
12. Freeman AF, Holland SM. The Hyper IgE Syndromes. *Immunol Allergy Clin North Am* 2008;28:277-viii.
13. Joshi AY, Iyer VN, Boyce TG, Hagan JB, Park MA, Abraham RS, et al. Elevated serum immunoglobulin E (IgE): when to suspect hyper-IgE syndrome-A 10-year pediatric tertiary care center experience. *Allergy Asthma Proc* 2009;30:23-7.