

Perineal Mass in One-Year-Old Boy: Rare Presentation of Fibrous Hamartoma of Infancy

Minoo Rostami, Pooya Hekmati, Mohsen Ebrahimnezhad, Hossein Amirzargar, Abdol-Mohammad Kajbafzadeh

Department of Pediatric Urology, Pediatric Urology and Regenerative Medicine Research Center, Tehran University of Medical Sciences, Tehran, Iran

Received: 27 Nov. 2022; Accepted: 20 Jun. 2023

Abstract- Fibrous hamartoma of infancy is a rare benign tumor that's mainly detected in the upper trunk. In this study authors report a 1-year-old case of perianal fibrous hamartoma which was successfully managed without need to orchidectomy or urethral manipulation.

© 2023 Tehran University of Medical Sciences. All rights reserved.

Acta Med Iran 2023;61(8):485-487.

Keywords: Hamartoma; Perineal; Mass; Infancy

Introduction

Fibrous hamartoma of infancy (FHI) is a mesenchymal tumor of the subcutaneous tissue which is characterized by a focal composition of rapidly growing mature cells in affected anatomical site (1-3).

Although this tumor has been generally reported in the upper torso, it hardly may occur in genital region (2). This rare tumor is usually diagnosed in males less than 2 years of age; most of them (91%) are below one (4). FHI afflicts males twice to thrice more than females (5).

Due to rare occurrences of FHI in para-testicular area and the importance of precise diagnosis and approach to it; we hereby report a case of 1-year-old boy with fibrous hamartoma of infancy in perianal region.

Case Report

An 1-year-old boy, born out of a non-consanguineous marriage and an uneventful prenatal period, turned up as an outpatient with a chief complaint of a painless, progressive swelling of right scrotum since 10 months old. He had negative history of previous inguinal trauma, swelling or edema. The patient didn't complain of fever, weight loss or other constitutional symptoms before his recent presentation. In the general appearance, he was founded as a healthy active baby. Vital signs were stable (BP=100/60, T=36.5 C, PR=90, RR=18, O₂ sat=98%),

and the patient was generally normal without lymphadenopathy or any skin lesion. Heart sounds were normal, and his lungs were clear. Abdominal examination revealed no erythematous lesion, ascites, tenderness or palpable mass. In local exam, a 10*30 mm² mass without a stuck was found in right hemiscrotum, the overlying skin was firm without tenderness, erythema or inguinal lymphadenopathy was not observed. It wasn't warm or mobile.

Hematologic assay for hemoglobin level, leukocyte count and differentials and Erythrocyte Sediment Rate were normal. The Sonogram showed a 16*23*36 ill-defined heterogeneous mass without pelvic invasion, suggestive of teratoma or hemangioma and recommended further evaluations with pelvic MRI. The (voiding cystourethrogram) VCUG reported no urethral involvement. MRI also reported a 38*20 mm² oval shaped soft tissue mass lesion with irregular margins in perineum, posterior to the root of right scrotum. The mass had heterogeneous, mainly low signal intensity in T1W and T2W images (Figure 1) and showed mild enhancement especially in periphery after contrast injection. No invasion or lymphadenopathy was seen.

Corresponding Author: A.M. Kajbafzadeh

Department of Pediatric Urology, Pediatric Urology and Regenerative Medicine Research Center, Tehran University of Medical Sciences, Tehran, Iran
Tel: +98 9121092241, E-mail address: kajbafzd@sina.tums.ac.ir

Copyright © 2023 Tehran University of Medical Sciences. Published by Tehran University of Medical Sciences

This work is licensed under a Creative Commons Attribution-NonCommercial 4.0 International license (<https://creativecommons.org/licenses/by-nc/4.0/>). Non-commercial uses of the work are permitted, provided the original work is properly cited

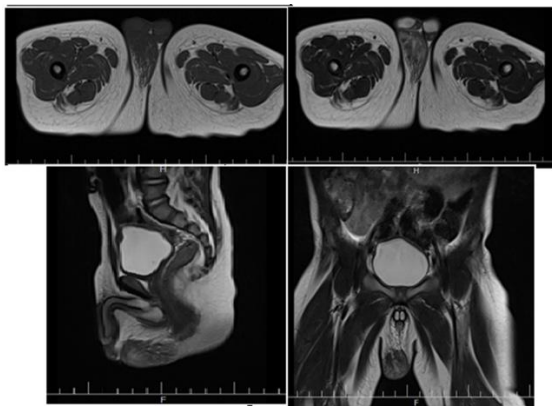


Figure 1. T1 and T2 images of MRI from scrotal mass

After obtaining the written informed consent for possible orchidectomy with the impression of scrotal mass, the patient was sent to the operating room. The patient was positioned in lithotomy and the mass was completely resected through scrotal incision. Frozen sections were also sent for histopathological evaluation from the tumor bulk and its surgical margins intraoperatively. Although urethra was involved with the tumoral tissue, it was successfully saved and as the mass was partly adhered to scrotal skin, scrotoplasty was done in the end.

Macroscopic study revealed pieces of scrotal mass with overlying skin in some areas of it. Microscopic investigation also showed bland fibrous spindle cells delimiting islands of mature fat besides immature mesenchymal cells with scant cytoplasm and bland straight and wavy nuclei with trabecular features with no mitotic figures. Final diagnosis was Fibrous Hamartoma of Infancy (FHI).

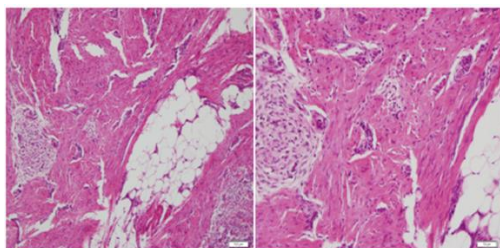


Figure 2. Micrograph showing three characteristic parts of fibrous hamartoma of infancy. Fat cells, trabecular immature mesenchymal cells with scant cytoplasm and wavy nuclei and fibrocollagenous tissue

Discussion

Fibrous hamartoma of infancy is a seldom occurring, benign soft tissue neoplasm of children under two years of age (3,6). History of the disease goes back to 1956 when Reye described it as "subdermal fibrous tumor of childhood" with consumed etiology of abnormal

regeneration after an unknown injury (7). 9 years later (1965) Enzinger introduced the term "fibrous hamartoma of infancy" as a distinctive category of pediatric soft tissue neoplasms (1). FHI is the best defined by WHO as a benign, irregular marinated superficial soft tissue proliferation, with three characteristic components; mature adipocytes, collagen bands and primitive mesenchymal cells (8).

The most common presentation of this uncommon neoplasm shows up as a firm, painless, subcutaneous lesion. While FHI grows so rapid, but it is benign in nature. It presents as a solitary mass of axillary region, upper arm, shoulder, back or inguinocrural areas in most patients (1). Synchronous or metachronous lesions have also been reported (1,4,9,10). Associated symptoms of hyperpigmentation and hypertrichosis of the overlying skin is rare (1,4,9,11) It has male tendency 2.4:1 whereas 91% of cases are under 12 months and in 23% of patients, it has existed at birth (12). The size of tumor ranges from 0.5 to 10 cm (8,13). There's no evidence of familial association or syndrome yet, but different translocations have been found (13-15).

FHI could be misdiagnosed with lymphadenopathy, rhabdomyosarcoma or neural tissue malignancies in practice (3). The histogenesis of FHI is unclear and long lists of benign or malignant tumors are in differential diagnosis regarding its pathologic features (1).

The so-called "serpentine pattern" of ultrasonography wasn't detected in our case, so for better evaluation of the extent of invasion, MRI was required.

FHI has a progressive behavior at first, but if it's left without treatment, its growing slows down and stops by age of five, although regression has never been shown. (1,5,16). Even though its first presentation may be misleading to malignant tumors, metastasis has not been reported yet and the rate of local recurrence after wide surgical excision is as low as 16% (1,4). The treatment of choice is surgical excision. There are two different approaches here, while one recommendation is combination of sub-total with second look excision (5) the other one suggests wide surgical resection with intraoperative frozen section confirmation (9), in order to ensure complete removal of the tumor. In this case, tumoral tissue was resected with clean margins confirmed by frozen sections and the nearby anatomical organs were preserved.

References

1. Enzinger FM, Martos-Cabrera L, Sampedro-Ruiz R, Pérez-González YC, Mentzel T, Llamas-Velasco M.

- Fibrous hamartoma of infancy: a series of 21 cases and review of the literature. *Actas Dermo-Sifiliográficas (English Edition)* 2021;112:520-7.
2. Kilitci AK, Yimaz F, Yanik S, Ozturk H. Testicular fibrous hamartoma: A case report. *Pediatr Urol Case Rep* 2015;2:5-5.
 3. Sengar M, Mohta A, Manchanda V, Khurana N. Paratesticular fibrous hamartoma in an infant. *Singapore Med J* 2012;53:e63-5.
 4. Kapatia G, Chatterjee D, Gupta K, Trehan A. Fibrous hamartoma of infancy with sarcomatous transformation: an unusual morphology. *Autops Case Rep* 2022;12:e2021380.
 5. Carretto E, Dall'Igna P, Alaggio R, Siracusa F, Granata C, Ferrari A, et al., Fibrous hamartoma of infancy: an Italian multi-institutional experience. *J Am Acad Dermatol* 2006;54:800-3.
 6. Zhang L, Wei JG, Zhang XW, Xu M, Li BC, Xu ZG, et al. Fibrous hamartoma of infancy: a clinicopathological and molecular genetic analysis of 33 cases. *Zhonghua bing li xue za zhi* 2022;51:530-5.
 7. Mocellin S. Fibrous Hamartoma of Infancy. In: *Soft Tissue Tumors*. Springer, Cham; 2021:341-2.
 8. Godkhindi VM, Meshram DP, Deshpande SA, Suvernekar SV. Fibrous Hamartoma Of Infancy-Case Report. *J Dent Med Sci* 2013;5:58-61.
 9. Imaji R, Goto T, Takahashi Y, Akiyama T, Yamadori I. A case of recurrent and synchronous fibrous hamartoma of infancy. *Pediatr Surg Int* 2005;21:119-20.
 10. Baek SH, Kim S, Lim K. CT and MRI Features of Middle Ear Fibrous Hamartoma of Infancy: A Case Report. *Taehan Yongsang Uihakhoe Chi* 2022;83:420-4.
 11. Kapatia G, Chatterjee D, Gupta K, Trehan A. Fibrous hamartoma of infancy with sarcomatous transformation: an unusual morphology. *Autops Case Rep* 2022;12:e2021380.
 12. Harris CJ, Das S, Vogt PJ. Fibrous hamartoma of infancy in the scrotum. *J Urol* 1982;127:781-2.
 13. Saab ST, McClain CM, Coffin CM. Fibrous hamartoma of infancy: a clinicopathologic analysis of 60 cases. *Am J Surg Pathol* 2014;38:394-401.
 14. Lakshminarayanan R, Konia T, Welborn J. Fibrous hamartoma of infancy: a case report with associated cytogenetic findings. *Arch Pathol Lab Med* 2005;129:520-2.
 15. Rougemont AL, Fetni R, Murthy S, Fournet JC. A complex translocation (6;12;8)(q25;q24.3;q13) in a fibrous hamartoma of infancy. *Cancer Genet Cytogenet* 2006;171:115-8.
 16. You J, Wang J, Li S, Li G, Guo H, Cheng Y, et al. Fibrous hamartoma of infancy in the scrotum: a case report. *Chin J Urol* 2021;12:873-4.