

# The Left Ventricular Intra-Myocardial Dissecting Hematoma Presented as a Rare Complication of the Neglected Myocardial Infarction

Fatemeh Moodi<sup>1</sup>, Mahmood Hosseinzadeh Maleki<sup>2</sup>, Afsaneh Mohammadi<sup>3</sup>, Reza Ghasemi<sup>4</sup>, Mohsen Yaghubi<sup>5</sup>

<sup>1</sup> Department of Echocardiography, Razavi Hospital, Mashhad, Iran

<sup>2</sup> Department of Cardiac Surgery, Imam Reza Hospital, Mashhad University of Medical Sciences, Mashhad, Iran

<sup>3</sup> Department of Cardiology, Razavi Hospital, Mashhad, Iran

<sup>4</sup> Department of Cardiology, 9 Dey Educational Hospital, Torbat Heydariyeh University of Medical Sciences, Torbat Heydariyeh, Iran

<sup>5</sup> Department of Extra-Corporeal Circulation (ECC), Razavi Hospital, Mashhad, Iran

Received: 28 Jan. 2023; Accepted: 27 Jul. 2023

**Abstract-** An intramyocardial dissection hematoma is a rare event usually caused by hemorrhagic dissection among the spiral myocardial. Herein, we reported a senile man with Intramyocardial dissection hematoma who presented with neglected myocardial infarction.

© 2023 Tehran University of Medical Sciences. All rights reserved.

*Acta Med Iran* 2023;61(10):635-638.

**Keywords:** Cardiac surgery; Cardiopulmonary bypass; Myocardial infarction

## Introduction

An intramyocardial dissecting hematoma (IDH) is a rare event that may result from myocardial infarction, chest trauma, and even percutaneous intervention (1).

It may be due to decreased infarcted area's tensile strength, intra-myocardial vessels rupture into the interstitial space, and an acute increase of coronary capillary perfusion pressure (2).

Herein, we present an old man with neglected myocardial infarction presented with intramyocardial dissecting hematoma with successful management.

## Case Report

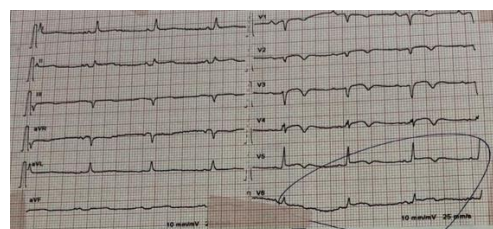
A 79-year-old man weighing 83 kg was admitted to the Emergency Department (ED) with a complaint of progressive exertional dyspnea and recurrent palpitations. He was in Class 3 functional class. He did not have any history of hospitalization. There was no significant past medical history or family medical history of cardiac disease.

He mentioned one episode of typical chest pain that was neglected for 20 days before hospitalization in the first history taking.

On admission, he was in stable condition; his blood pressure was 89/61 mmHg with a low-volume pulse, his heart rate was regular sinus tachycardia and 102 beats per minute, and his respiratory rate was 22 breaths/min, and he was afebrile. Oxygen saturation, with a finger pulse oximeter on the index finger at rest, was 95%.

In the primary physical examination, cardiac auscultation revealed an S3 gallop at the right and left sternal border and a systolic murmur.

The electrocardiogram had a sinus rhythm accompanied by poor R-wave progression, low voltage pattern, negative T-wave, and ST-segment elevation in V1-V5 leads that were suggestive of prior anterior myocardial infarction (Figure 1).



**Figure 1.** The patient's electrocardiogram demonstrated the probable neglect of anterior myocardial infarction characteristics

Based on the probability of acute coronary syndrome

**Corresponding Author:** M. Yaghubi

Department of Extra-Corporeal Circulation (ECC), Razavi Hospital, Mashhad, Iran  
Tel: +98 9367780472, E-mail address: n.m.yaghubi@gmail.com

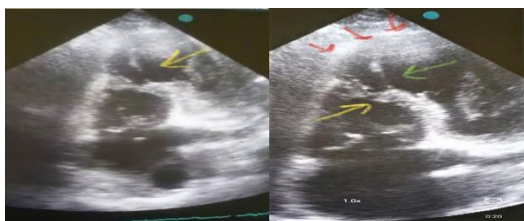
Copyright © 2023 Tehran University of Medical Sciences. Published by Tehran University of Medical Sciences

This work is licensed under a Creative Commons Attribution-NonCommercial 4.0 International license (<https://creativecommons.org/licenses/by-nc/4.0/>). Non-commercial uses of the work are permitted, provided the original work is properly cited

### Left ventricular intra-myocardial dissecting hematoma

because of his history of chest pain three weeks earlier, the primary differential diagnosis was decompensated heart failure due to acute coronary syndrome.

Then, the patient was referred to the echocardiographic study unit; transthoracic echocardiography (TTE) showed mild left ventricular enlargement with severely reduced systolic function, EF=25%. The findings accompany akinesia of mid-intro-septal, apical-septal, apical-lateral, inferior-apical, and Antro-apical with thinning wall and apical aneurysmal formation. Meanwhile, a ventricular septal rupture (VSR) with a left to right shunt appeared (defect size by CFD=9 mm, and PPG=50 mmHg). Also, disruption of the left ventricle internal layer at the distal septum created an apical cavity with communication to the right ventricular via VSR (Figure 2). Severe right ventricular enlargement with moderately reduced systolic function was found. Other findings included severe tricuspid regurgitation and significant pulmonary arterial hypertension (PASP=60 mmHg).



**Figure 2.** the four-chamber TTE showed the apical aneurysmal formation with a ventricular septal rupture (VSR) and a left-to-right shunt

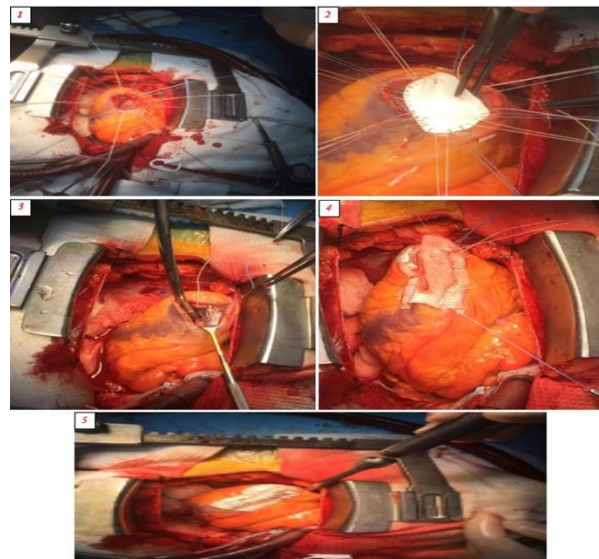
Based on these findings, he was transferred emergently to cardiac catheterization. The catheterization report revealed a significant proximal portion lesion and diffuse lesions in the mid-portion of the left anterior descending (LAD) artery. Also, there was a significant lesion at the ostio-proximal of Diagonal 1. Another significant finding showed that the right coronary artery was diminutive and had total occlusion at mid-portion with a good run-off.

The patient was scheduled for emergent open-heart surgery.

Before surgery, based on compromised hemodynamic status, the Intra-Aortic Balloon Pump (IABP) was inserted via the right femoral artery. General anesthesia was performed for median sternotomy. A mild hypothermia strategy (33.0° C) was established. Then, systemic heparinization (3 mg/kg) was performed. After cannulation, cardiopulmonary bypass (CPB) was established (considering ACT over 480 seconds). The aortic cross-clamping was performed, and infusion of

cold blood cardioplegia was followed by cardiac arrest.

Then, an Antro-apical ventriculotomy was done. The large VSR, 35 mm, was noted in the Antro-apical position, partially covered with necrotizing tissue (endocardium and myocardium). The large VSR was repaired with a Gortex patch, and the Antro-apical ventriculotomy was repaired with a Dacron patch (Figure 3).



**Figure 3.** The antro-apical ventriculotomy was done (1), The large VSR in the antro-apical position was repaired with a Gortex patch (2-3), and the antro-apical ventriculotomy was repaired with a Dacron patch (4-5)

The aortic cross-clamp was removed, and the patient was successfully weaned from CPB. The heart was de-aired, followed by patient re-warming. He was transferred to the ICU in good hemodynamic condition at the final surgery.

After 12 hours of the ICU entrance, the patient was weaned from mechanical ventilation and extubated. Immediately, the TTE was done and showed that the VSR patch in the antroapical wall of the left ventricle was compatible without significant residual.

He was in ICU with Milrinone infusion (0.3-0.7 mcg/kg/min) and epinephrine (0.01 mcg/kg/min) to day three after ICU entrance. On day 4, after the tapering and stopping of the epinephrine infusion, the IABP was removed. The Milrinone infusion was continued at 0.3 mcg/kg/min. On day 5, the Milrinone infusion was stopped, and the patient was transferred to the post-ICU three days later; he was discharged from the hospital in good condition. The patient was advised to continue anticoagulation medications, closely monitor coagulation status, and follow his situation by referring him to a heart

clinic approximately 40 days after discharge. He was referred to our center on day 42 after discharge. TTE showed a reduced PASP=40 mmHg and mild LV enlargement with accelerated systolic function (EF=35-37%), with no obvious residual VSR by CFD and contrast study.

## Discussion

Intramycardial dissecting hematoma (IDH) is a rare complication of the acute phase of myocardial infarction or may occur during remodeling (3-4).

The underlying mechanism is a hemorrhage dissecting among the helical myocardial fibers, resulting in a new lumen surrounding the myocardium. This process is initially contained within the myocardial wall and may cause the hematoma to expand and rupture into other cardiac structures (5). The differential diagnoses for IDH include pseudoaneurysm, intracardiac thrombosis, and prominent ventricular trabeculations (6).

Due to multimodal noninvasive cardiac imaging advancements, IDH can be managed earlier and highly reliably diagnosed (7). Despite the advent of techniques in IDH diagnosis, the mortality and morbidity of this life-threatening event seem high (6).

Meanwhile, familiarity with echocardiography and other cardiac imaging techniques is crucial. For precise diagnosis and successful patient management, a multidisciplinary team involving cardiologists, radiologists, and cardiac surgeons should perform all these techniques (8).

Our patient's echocardiographic diagnosis of septal without free wall IDH encompasses a thinned endomyocardial border surrounding the cavitory defect. Also, this finding is followed by the blood content of the neo-cavitation that changes in the echogenicity. On the other hand, there was communication between the two ventricular chambers through the myocardial dissection, and the Doppler recording revealed a flow within the dissected myocardium. Other echocardiographic studies noted that these criteria imply the precise IDH diagnosis by echocardiography (4).

Many factors, such as the patient's age, hemodynamic situation, hematoma size, ventricular septal defect, LV ejection fraction, and even other complicated conditions (pericardial effusion), can be affected by managing patients with IDH. However, the independent risk factors for the high chance of mortality were compromised LV function by the ages above 60 years, concomitant with anterior myocardial infarction (9).

These characteristics showed the rarity and good

management of our patient. In our case, he was 79 years old with a reduced ejection fraction and a large VSR that caused a compromised hemodynamic situation.

The surgical repair approach should be considered in patients with rapid progression of hematoma, invasion to cardiac rupture, or the need for surgical revascularization. A high mortality rate accompanies this process due to the complexity of the surgery with post-operative comorbidities such as the risk of thromboembolism, progression of the dissection, and bleeding into the pericardial space (10).

The probable surgical treatment of this patient may be due to the rapid approach to this method before the incidence of other complicated conditions. Also, serial echocardiographic management after surgery is a critical factor affecting cardiac function trends through close monitoring and preventing life-threatening structural events. So, frequently evaluating the status of the IDH by echocardiography to provide appropriate treatment is recommended. Also, follow-up studies in patients with the surgical approach to IDH for high morbidity and mortality events such as cardiac dysrhythmias due to scarred myocardium, recurrence of congestive heart failure, low cardiac output syndrome, and LV remodeling (10-12) seem necessary.

## References

1. Agarwal G, Kumar V Jr, Srinivas KH, Manjunath CN, Prabhavathi B. Left Ventricular Intramycardial Dissecting Hematomas. *JACC Case Rep* 2020;3:94-8.
2. Hosseinzadeh-Maleki M, Valizadeh N, Rafatpanah N, Moezi SA. Survival after left ventricular free wall rupture due to acute myocardial infarction. *ARYA Atheroscler*. 2015;11:310-3.
3. Dias V, Cabral S, Gomes C, Antunes N, Sousa C, Vieira M, et al. Intramycardial dissecting hematoma: a rare complication of acute myocardial infarction. *Eur J Echocardiogr* 2009;10:585-7.
4. Tanabe J, Okazaki K, Endo A, Tanabe K. Left Ventricular Intramycardial Dissecting Hematoma. *CASE (Phila)*. 2021;5:349-53.
5. Vargas-Barrón J, Roldán FJ, Romero-Cárdenas Á, Vázquez-Antona CA. Intramycardial dissecting hematoma and postinfarction cardiac rupture. *Echocardiography* 2013;30:106-13.
6. Polito MV, Hagedorff A, Citro R, Prota C, Silverio A, De Angelis E, et al. Loeffler's endocarditis: an integrated multimodality approach. *J Am Soc Echocardiogr* 2020;33:1427-41.
7. Roslan A, Aktifanus ATJ, Hakim N, Samsudin WMN,

## Left ventricular intra-myocardial dissecting hematoma

- Khairuddin A. Intramyocardial dissecting hematoma in patients with ischemic cardiomyopathy: role of multimodality imaging in three patients treated conservatively. *CASE (Phila)* 2017;1:159-62.
8. Ghasemi R, Gharaee R, Nazari S, Sadri S, Tehrani Zadeh F, Yaghubi M. Apical Hypertrophic Cardiomyopathy Presenting as Peripheral Cyanosis on Exertion and Paroxysmal Nocturnal Dyspnea: An Atypical Case Report. *J Kerman Univ Med Sci* 2021;28:306-10.
  9. Leitman M, Tyomkin V, Sternik L, Copel L, Goitein O, Vered Z. Intramyocardial dissecting hematoma: Two case reports and a meta-analysis of the literature. *Echocardiography* 2018;35:260-6.
  10. Spinelli L, Stabile E, Giugliano G, Morisco C, Giudice CA, Imbriaco M, et al. Intramyocardial dissecting hematoma in anterior wall ST-elevation myocardial infarction: impact on left ventricular remodeling and prognosis. *Int J Cardiovasc Imaging* 2018;34:201-10.
  11. Yaghubi M, Dinpanah H, Ghanei-Motlagh F, Kakhki S, Ghasemi R. Trifascicular block as primary presentation of the cardiac amyloidosis; A rare case report. *ARYA Atheroscler* 2018;14:101-4.
  12. Fathi M, Valaei M, Ghanbari A, Ghasemi R, Yaghubi M. Comparison of Patient's Kidney Function Based on Kidney Disease Improving Global Outcomes (KDIGO) Criteria and Clinical Parameters in Isolated Coronary Artery Bypass Graft (CABG) Surgery in On-Pump and Off-pump Methods in Patients with Low Cardiac Output Syndrome (LCOS) After Surgery. *Anesth Pain Med* 2020;10:e100517.