

A Metallic Skewer Penetrating the Skull

Arash Mansoori^{1,2*}, Yousef Rezaei^{2,3,4**}

¹ Department of Neurosurgery, Vali-e-Asr Hospital, Meshgin Shahr, Iran

² Medical School, Ardabil University of Medical Sciences, Ardabil, Iran

³ Heart Valve Disease Research Center, Rajaie Cardiovascular Institute, Iran University of Medical Sciences, Tehran, Iran

⁴ Behyan Clinic, Pardis New-Town, Tehran, Iran

Received: 03 Sep. 2025; Accepted: 11 Jan. 2026

Abstract- A 35-year-old man was admitted to the emergency department complaining of skewer penetration into his head. He had stable hemodynamics and intact neurological examinations upon admission. The imaging evaluation by computed tomography (CT) showed a metallic skewer penetrated into the left temporal associated with a subdural bleeding, contusion, and depressed bone fracture. In an emergency operation, the pterional approach was implemented, and the skewer was extracted. After six months follow-up, the patient had an intact neurological outcomes and CT angiography demonstrated no vascular complications. The metallic skewer penetration into the brain as a low-velocity penetrant can be safely managed by the implementation of imaging studies, prophylactic drug prescriptions, and planned surgical interventions.

© 2026 Tehran University of Medical Sciences. All rights reserved.

Acta Med Iran 2026;64(2):98-101.

<https://doi.org/10.18502/acta.v64i2.21536>

Keywords: Brain trauma; Penetrating brain injury; Skull; Foreign body

Introduction

Penetrating brain injury (PBI) is considered as a life-threatening condition, and it is mainly caused by gunshot bullet (1). The low-velocity penetrants such as knives or nails can lead to tissue damage less than the high-velocity ones such as gunshots (2,3); however, both of them can damage to the critical parts of the brain and result in mortality and life-long disabilities (4). The prognosis of PBI is mainly mediated by the features of penetrants, being a civilian- or military-based trauma, the extent of brain tissue injuries, and an expeditious evaluation upon admission to the emergency department (3,5).

Case Report

A 35-year-old man was admitted to the emergency department complaining of skewer stabbed in his skull after an assault at his restaurant within past 2 hours (Figure 1A). He only had a headache and a local pain at

the penetration site, while he had stable hemodynamics and intact neurological examinations with clear consciousness. The patient's Glasgow Coma Scale was 15 upon admission. He underwent imaging evaluation using an X-ray and a computed tomography (CT) scan taken from his head. The CT imaging showed a metallic skewer penetrated into the left temporal as long as 4 cm associated with subdural bleeding, contusion, and depressed bone fracture in the entrance hole (Figure 1B and C). Due to the lack of early access to the CT angiography, we could not evaluate intracranial vascular involvements. The prophylactic regimen of ceftazidime 1 g every 8 hours, vancomycin 1g twice daily, and phenytoin 125mg three times a day was initiated before transferring into the operation room. During an emergency operation using a general anesthesia, the pterional approach was implemented at the left side of his skull to explore the entrance site of the skewer. Then, we performed a craniotomy sized 5×5 cm at the penetration site. The skewer was extracted during a complete visualization of the brain tissues (Figure 1D, E, and F).

Corresponding Authors: A. Mansoori* and Y. Rezaei**

*Department of Neurosurgery, Vali-e-Asr Hospital, Meshgin Shahr, Iran
Tel: +98 4532530600, E-mail address: s.arash.mansoori@gmail.com

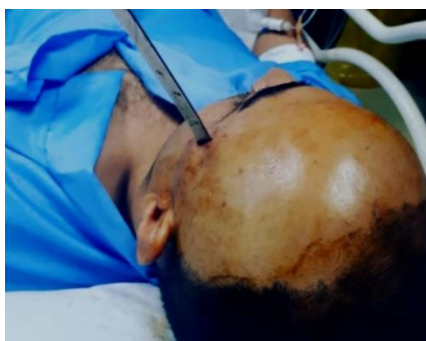** Behyan Clinic, Pardis New-Town, Tehran, Iran
Tel: +98 2176274539, E-mail address: yousefrezaei1986@gmail.com

Copyright © 2026 Tehran University of Medical Sciences. Published by Tehran University of Medical Sciences

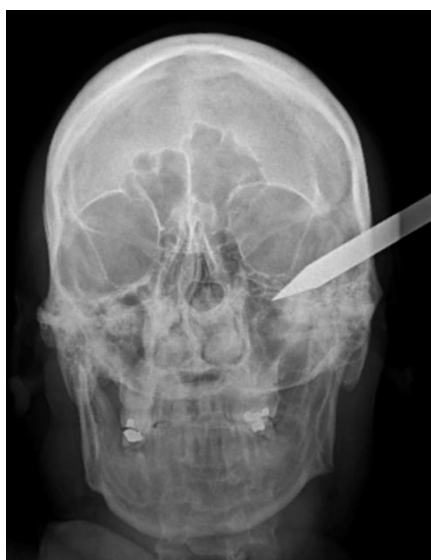This work is licensed under a Creative Commons Attribution-NonCommercial 4.0 International license (<https://creativecommons.org/licenses/by-nc/4.0/>). Non-commercial uses of the work are permitted, provided the original work is properly cited

He postoperatively received parenteral antibiotic and antiepileptic regimens. He discharged home after receiving postoperative cares and returned his work with an uncomplicated postoperative course. After six months

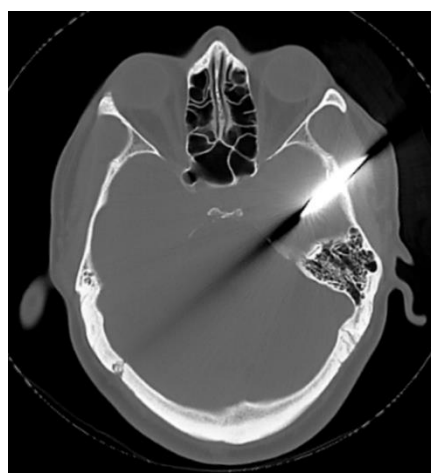
follow-up, he underwent a CT angiography and it demonstrated no intracranial vascular injuries. He also had a stable condition with intact neurological outcomes during follow-up period.



a

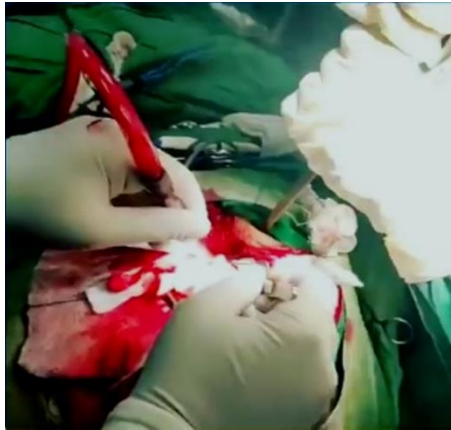

b

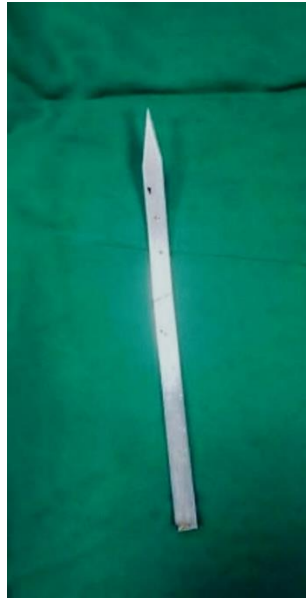

c

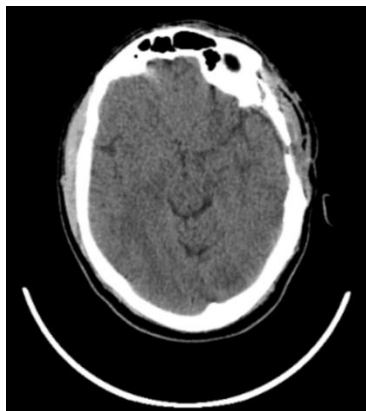
Metallic skewer penetrating the skull



d



e



f

Figure 1. Skewer penetrated into the brain demonstrating in (a) patient calvarium, (b) skull radiograph, (c) CT imaging without contrast, (d) visualization of the entrance site, (e) extracted skewer, and (f) CT imaging after successful removal of the skewer

Discussion

The main objects penetrating into the skull included shotguns' bullets, nailguns, pencil, arrows, scissors, iron rods, chopsticks, and screwdriver (6-10). All penetrating objects have been reported as a punishment for criminals, a self-inflicted injury, or a suicidal attempt (8). Initial evaluation included x-ray and CT scan imaging that is implemented for identifying the location of injuries and planning surgical management. Moreover, CT angiography and magnetic resonance imaging are also applied during follow-up (5). Patients can be managed using a surgical removal of foreign bodies under local or general anesthesia (8). Of noting, the prognosis of PBI can range from an early mortality to no complications (5). The type of penetrants, the location of entrance, and peri-operative prophylactic drug influences on follow-up outcomes (11,12). Therefore, a prompt evaluation of injuries upon admission and a timely implementation of interventions are essential to improve outcomes. In our case, the metallic skewer did not pass the midline and none of intracranial vessels were involved. The prompt evaluation of condition and a timely surgical intervention with a concomitant prophylactic regimen of antibiotics and antiepileptic resulted in good prognosis. The patient was stable perioperatively and during 6-month follow-up period.

This case highlights the management of PBI caused by a low-velocity penetrant object. Metallic skewer penetration into the brain is a rare phenomenon which can be managed expeditiously by the implementation of imaging studies, prophylactic antibiotic and antiepileptic prescriptions, and a planned surgical intervention.

References

1. Joseph B, Aziz H, Pandit V, et al. Improving survival rates after civilian gunshot wounds to the brain. *J Am Coll Surg* 2014;218:58-65.
2. Karger B. Penetrating gunshots to the head and lack of immediate incapacitation. II. Review of case reports. *Int J Legal Med* 1995;108:117-26.
3. Marhold F, Scheichel F, Ladisich B, et al. Surviving the Scene in Civilian Penetrating Brain Injury: Injury Type, Cause and Outcome in a Consecutive Patient Series in Austria. *Front Surg* 2022;9:923949.
4. Aghabiklooei A, Molahoseini R, Khajoo A, Shiva H. Multiple nails in the brain: an unusual suicidal attempt. *Am J Forensic Med Pathol* 2012;33:88-9.
5. Vakil MT, Singh AK. A review of penetrating brain trauma: epidemiology, pathophysiology, imaging assessment, complications, and treatment. *Emerg Radiol* 2017;24:301-309.
6. BouHaidar R, Lunyova ZM. A screwdriver in the skull. *Forensic Sci Med Pathol* 2005;1:61-63.
7. Cvetković D, Živković V, Damjanjuk I, Nikolić S. "The pen is mightier than the sword" – suicidal trans-orbital intracranial penetrating injury from a pencil. *Forensic Sci Med Pathol* 2018;14:221-224.
8. Shaukat S, Zaidi SMF, Khatri A, et al. Self-inflicted penetrating brain injuries with preserved neurological function: a case series. *Chin Neurosurg J* 2023;9:15.
9. Lee YC, Kwan HH, Wong T, Pan NY, Lai HY, Ma KF. Self-inflicted transorbital brain injury by chopsticks in a patient with acute psychosis. *Hong Kong Med J* 2017;23:313-4.
10. Zima LA, Srinivasan S, Budde B, Kitagawa R. Thirty-two nails injected into the head: An operative report and review of the literature. *Surg Neurol Int* 2022;13:377.
11. Bayston R, de Louvois J, Brown EM, Johnston RA, Lees P, Pople IK. Use of antibiotics in penetrating craniocerebral injuries. "Infection in Neurosurgery" Working Party of British Society for Antimicrobial Chemotherapy. *Lancet* 2000;355:1813-7.
12. Cook R, Zima L, Khazaal J, Williams J. Low-velocity penetrating brain injury: a review of the literature and illustrative case. *Brain Inj* 2024;38:668-674.