

The Role of the Crico-Thyroid Muscle in Abductor Paralysis of the Larynx

J. HEDAYATY, M.D., M.Sc., F.I.C.S.*

TEHERAN

Much interest has been aroused in the past and great deal of work done on paralysis of the vocal cords. The interest has been more focused particularly on a special variety of it where the paralyzed cords stay in the midline of the larynx.

The subject has been widely studied from clinical standpoints. The striking fact in this study is the peculiar behaviour of the vocal cords after accidental injuries to the recurrent laryngeal nerves during neck procedures such as thyroidectomy and pharyngeal diverticulectomy. Some cords take a paramedian position, somewhere between the midline and the intermediate position, some shift gradually to the midline and stay there indefinitely, and some others return, reportedly, to the intermediate position.

If the recurrent laryngeal nerve, as it is well known, contains both abductor and adductor fibers for innervation of the laryngeal muscles, then why the vocal cord, after injury to the recurrent nerve, very often stay in the midline or in the adduction position and not in the intermediate or so-called cadaveric position?

* Master of Science in Laryngology and Bronchoesophagology, Temple University, Philadelphia.

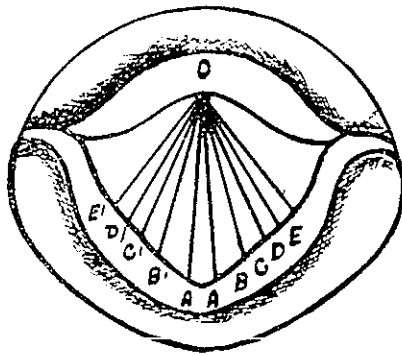


Fig. 1- Different positions of the vocal cords.
 A) Median or midline position. B) Paramedian position.
 C and D) Cadaveric or intermediate position.
 E) Deep respiratory position.

I- Clinical observations: New and Childrey have published a report on 217 cases of vocal cord paralysis in which the recurrent nerves have been often severely damaged during the thyroid surgery and that the paralyzed cords stayed about 90% of cases in the median line. It may be at the intermediate position at first, but later it almost always stays in the median line. In another group of 123 of vocal cord paralysis, following thyroid operations reported by these authors, the position of the affected cord was noted in 97 cases and in these it was in the median line in 88 and cadaveric position in only 9 cases. This is just about the same percentage (90%) reported also by others for midline position of the vocal cords.

In a case of total interruption of the recurrent nerves by thyroid surgery clinically reported by Menzel and anatomically studied thoroughly by E.A. Spiegel after autopsy, the cords were in the midline position instead of the expected cadaveric position.

Louis Clerf is more explicit in his opinion and not only repeats the same observation, but also has mentioned a case in whom the transitional period between injury to the nerve (paramedian position) and its complete shift to the midline took only three weeks.

In the other hand in a series of 270 cases of paralysis reported by Suehs and 235 cases reported by Smith A. B., Lambert and

Wallace from the Statistical Research Department of the Royal Infirmary of Edinburgh, the percentage of midline positions of the vocal cord paralysis is not in conformity with those reported previously. This is due to the fact that the percentage of the midline position of the vocal cords reported by these authors is drawn from all the vocal cord paralysis produced by great variety of etiologic factors, whereas the 90% of the midline positions reported by previous authors is the percentage of positions occupied by vocal cords after severe injuries to the recurrent laryngeal nerves following thyroid surgery or other means of trauma to the recurrent nerves.

As we can see the behaviour of the vocal cords following an irreversible injury to the recurrent laryngeal nerve is problematic and raises many questions for which there are no unanimous answers.

However, few theories have been proposed among which three are the most plausible explanations:

II. Theories:

1 - Explanation through Semon's Law. — Felix Semon in 1881 published his famous article «On the Abductor Fibers of the Recurrent Laryngeal Nerve», later on known as Semon's Rule or Law. In this article he formulated that the function of abduction of the glottis has a proclivity to disease over the function of adduction.

Many authors have tried to explain the behaviour of the vocal cords in the recurrent laryngeal paralysis through this law.

2- Explanation through bifurcation theory of the recurrent nerve: — Briening, Gregg and Morisson have drawn attention to the bifurcation of the recurrent nerve at its terminal course before entering the larynx. Morisson has extended his investigation to the dissection of 100 cadavers and 200 recurrent nerves and has found that bifurcation of the recurrent nerve occurs in about 42% of adult humans at or near the lower border of the cricoid cartilage on its posterior surface.

This anatomical fact has been taken as a basis to explain that if during thyroidectomy the anterior or posterior branch of the recurrent nerve is severed the result would be paralysis of adductor or abductor muscles.

In subsequent articles we may go into further details and discussions concerning the Semon's Law and the Bifurcation theory. But in this article it is our intention to show our own experimental

works concerning the influence of the superior laryngeal nerve and particularly the role of the crico-thyroid muscle in the midline paralysis of the recurrent laryngeal nerve.

3 - EXplanation through the influence of the superior laryngeal nerve — :

It has been accepted for long that the crico-thyroid muscle, considered as tensor of the vocal cord is innervated by the external branch of the superior laryngeal nerve and all the remaining muscles of the larynx are innervated by the recurrent nerve

This includes the posterior crico-arytenoids as the abductor muscles; and the lateral crico-arytenoids, the thyro-arytenoids and the interarytenoids as adductor muscles of the vocal cords.

However, the most recent experimental works done by Todd and Philip Vogel in the United States of America have proved that in man (being different from the dog) the internal laryngeal nerve is not purely sensory as established before, but contains also motor fibers which innervate the interarytenoid muscle. This muscle receives also innervation from the recurrent nerves. Therefore, not only it is innervated by both sides, but in each side it receives double innervation from both the superior and the inferior laryngeal nerves.

Crico-Thyroid Muscle as an Adductor: — The thesis that the crico-thyroid muscle is an adductor muscle in addition of being the tensor of the vocal cord has been under consideration for sometime by authors such as Wagner, Onodi, Iglauer, Lemere, New and Childrey.

Lemere has proved this fact experimentally and expresses the opinion that complete paralysis of the recurrent nerves produces a partially adducted position of the vocal cords. The cords may be in any position from the cadaveric to the midline depending upon the time interval and degree of tension of the non paralyzed crico-thyroid muscle, which stretches the cord anteroposteriorly and adducts it.

A strong support has also been given by Murtagh: «There is evidence that the crico-thyroid is a strong adductor. This adductor action of the crico-thyroid leads to some speculations on the role that this muscle plays in the laryngeal picture presented in the recurrent nerve paralysis.»

Our own experimental works have strongly supported those observations and photographic evidences (see plates 1 and 2) show that

THE ROLE OF THE CRICO-THYROID MUSCLE IN ABDUCTOR 73
PARALYSIS OF THE LARYNX

stimulation of the crico-thyroid muscle produces tension and marked adduction of the vocal cords. If both crico-thyroids are stimulated and the stimulation is sufficiently strong, the cords may even meet each other in the midline and completely close the glottic chink (Plate 2:XI)

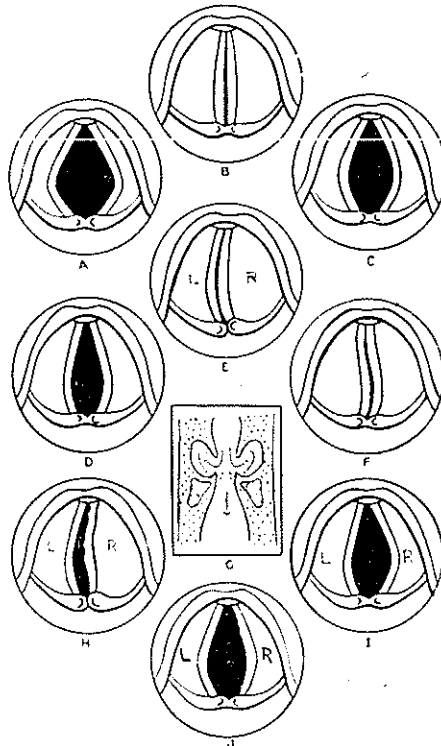


Fig. 2 (After Lemere): A, full abduction of the vocal cords on deep inspiration. B, full adduction of the vocal cords as in phonation. C, cadaveric position of the vocal cords as in complete paralysis of the cords, quiet respiration or death. D, partially adducted position of the vocal cords accompanying bilateral paralysis of the recurrent laryngeal nerves. E, unilateral paralysis of the recurrent nerve on the left, with the right cord crossing the midline on attempted phonation. F, bilateral paralysis of the external rami of the superior laryngeal nerves with relaxation of the vocal cords on attempted phonation due to paralysis of the crico-thyroids. G, approximation of the vocal cords during inspiration. H, paralysis of the left recurrent laryngeal and the right external branch of the superior laryngeal nerves. I, paralysis of both recurrent laryngeal and the right external laryngeal nerves. The left cord is in paramedian and the right cord in cadaveric position. J, bilateral paralysis of the external laryngeal nerves plus paralysis of the left recurrent laryngeal nerve. The left cord is in the cadaveric position, with relaxation of the cord on the right

III - Our Own Experimental Works:— Our experiments concerning this article have been concentrated mainly on the function of the crico-thyroid muscle and particularly its role in the recurrent nerve paralysis.

Although certain reports on the function of the crico-thyroid as an adductor have been presented before, none of them has given a clear and definite demonstration of it.

All our experimental works have been performed in the Research Department of Temple University Medical School, Philadelphia in 1953 under auspices of Pr. Chevalier L. Jackson for which we are very thankful. Although the results were reported to the Faculty of Temple University as a thesis for a Master of Medical Science Degree in 1953 they have not been published yet.

A- material and Method:— Our work has been performed on a group of 14 dogs, 2 cats and 2 rabbits. There was no gross difference in the pattern of laryngeal innervation in the last 2 species. However, because of the minute anatomy and small mouths for laryngoscopic measurements, cats and rabbits were dismissed later and we limited our work to dogs only.

B-Anesthesia:—We used thiobarbiturate or surital, sodium pentothal and sodium nembutal. For short and very light anesthesia 2.5% solution followed by a 0.3% sodium pentothal solution were given by intravenous injections and were found very satisfactory. This light anesthesia allowed us to inspect the position and movements of the vocal cords with a laryngoscope at any time.

C-Techniques:— Our techniques were limited to dissection, nerve sectioning and faradic and galvanic current stimulation methods. During these experiments systematic glottic chink measurements were performed with a right angle narrow ruler through a Jackson laryngoscope. Also different movements of the vocal cords were recorded by koda-chrome pictures taken on a roll of 16 mm. film in a movie camera mounted on Clerf laryngeal photographic apparatus.

Through a median incision of the neck the strip muscles were retracted and recurrent nerves exposed from the lower part of the neck to their entrance into the larynx just below the cricoid cartilage.

THE ROLE OF THE CRICO-THYROID MUSCLE IN ABDUCTOR 75
PARALYSIS OF THE LARYNX

If there were any difficulty in locating the recurrent nerve, we located the thyroid lobe first, and then easily found the recurrent lying in a thin layer of its capsule. In the dog there is no thyroid isthmus and each lobe is separately located on the lateral aspect of the trachea. Although it was relatively easy to visualize and dissect the superior laryngeal nerve and its two branches when the stimulation and division of the external laryngeal nerves was desired (rather than its anatomy or its relations) we preferred instead to stimulate or section the crico-thyroid muscle itself. This required much less dissection and brought more simplicity to the operations with same results.

In many instances one or both recurrent nerves were divided and about 3 cm. of their lengths were removed. In 2 cases recurrences were tightly ligated with heavy silk instead of division.

Systematic measurements of the glottic chink were performed on each dog before surgery, after division of the recurrent nerves and following sectioning of the crico-thyroid muscle, at the time of recovery from anesthesia and also periodically for many weeks during the observation period. We usually measured the diameter of the glottic chink at the posterior extremity of the vocal cord, just at its attachment to the vocal process of the arytenoid cartilages when the dog was under anesthesia. At this point the glottis has its widest diameter.

D-Results: —

1—Stimulation of one recurrent laryngeal nerve with faradic current produces immediate and simultaneous contraction and adduction of both vocal cords and complete closure of the glottis (Plate 1, II).

Our observations are in agreement with those of Lemere and Murtagh and we have never noticed abduction of the vocal cord in such nerve stimulation experiments. However, we fail to confirm Murtagh's contention that abduction will occur by rubbing a thread back and forth under the recurrent nerve.

The reason for bilateral adduction of the cords upon a unilateral nerve stimulation is not known, at least to us. However, the answer does not seem to lie in the theory that the contralateral side stimula-

tion is exercised through the afferent recurrent nerve fibers and meddullary or other central communications. If it were so, the stimulation of the central end of the divided nerve in one side would produce a contralateral stimulation of the vocal cord for which the recurrent nerve was intact. Our experiments in this line failed to produce such results. However, it is possible to believe that the stimulation of the opposite recurrent nerve is effected through the bilateral innervation and communications inside of the interarytenoid muscle.

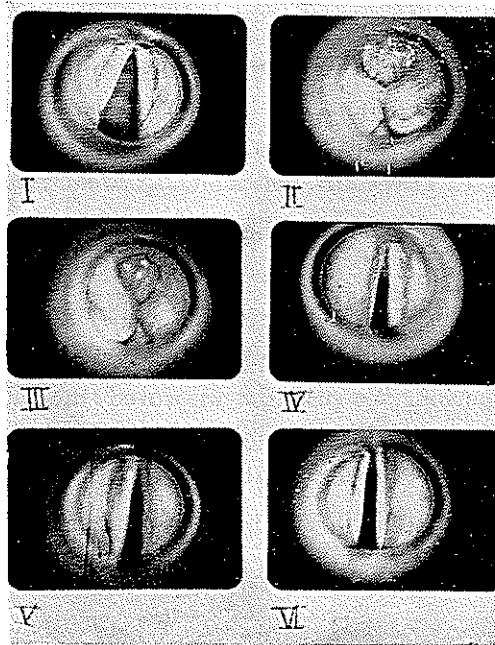


Plate 1- Positions and relations of vocal cords in a dog under general anesthesia. Original kodachrome pictures were taken by a movie camera mounted on a Clerf laryngoscopic apparatus. These black and white reproductions have been made according to the actual diameters.(J.H.).

- I- Position of vocal cords during quiet respiration
- II- Stimulation of the right recurrent laryngeal nerve.
- III- Stimulation of the left recurrent laryngeal nerve.
- IV- Stimulation of the right crico-thyroid muscle.
- V- Stimulation of the left crico-thyroid muscle.
- VI- Simultaneous stimulation of both crico-thyroid muscles.

2- Stimulation of the external laryngeal nerve or direct stimulation of the crico-thyroid gives marked tension and elongation of the vocal cord and gives also certain amount of adduction depending on the amount of the stimulus. If both muscles are stimulated at the same time and the stimulus is strong enough, the glottis may partially or even completely close up. This adductor function of the crico-thyroid muscle is very striking and unquestionably, as shown in our photographic evidences is present (plates 1 and 2).

3- Sectioning of both recurrent laryngeal nerves in the dog will produce paralysis of all the laryngeal muscles except the crico-thyroids. While vocalization is not impossible, there may be some dyspnea particularly on exertion. The dyspnea on exertion or deep inspiration is due to the opposition of the vocal cords when the incoming air goes to the ventricular cavity behind them. There may also be some difficulty in swallowing, due to the unopposed action of the crico-thyroid muscles, which stretch the cords antero-posteriorly.

The vocal cords being under constant contraction of the cricothyroids, will be tensed and adducted. Therefore, following bilateral division of the recurrent nerves the position of the vocal cords will be neither extreme abduction or adduction, nor the cadaveric position, but in a paramedian position. This is a partially adducted position at the beginning. Gradually after a certain length of time, the crico-thyroid contraction will be increased and the cords pull to the midline. The paramedian position could be anywhere between the median and cadaveric position.

In 6 of our cases, the initial measurement of the glottis before surgery was recorded as being 8 mm. A few minutes following bilateral division of the recurrents this diameter was reduced to 4-5 mm. This narrowing of the diameter is very insidious and hardly noticeable. When looking at the cords through a laryngoscope during the sectioning of the nerves by an assistant, no abrupt motion of the vocal cords was noticed. Nevertheless, careful measuring will show a noticeable narrowing of the glottis (Plate 2 VIII and IX)

The time interval needed for a vocal cord to make a complete shift to the midline is not known exactly and varies considerably. In

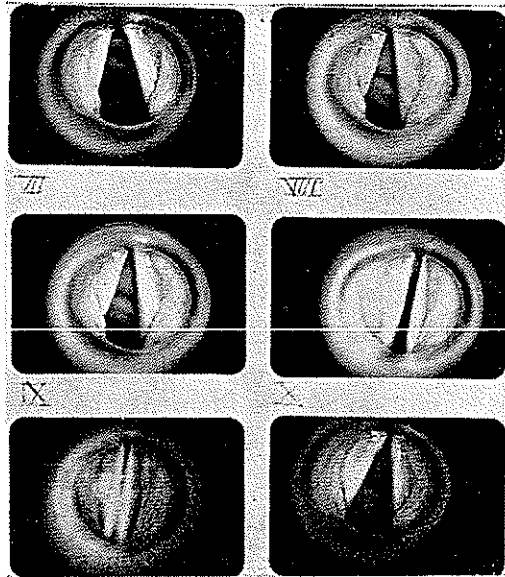


Plate 2- Positions and relations of vocal cords in a dog under general anesthesia. Original kodachrome pictures were taken by a movie camera mounted on a Clerf laryngoscopic apparatus. These black and white reproductions have been made according to the actual diameters (J.H.).

VII- Positions of the vocal cords in forced inspiration.

VIII- Vocal cords just at the time when the right recurrent nerve was being sectioned.

IX- Vocal cords just at the time when the left recurrent nerve was being sectioned.

X- Simultaneous stimulation of both crico-thyroid muscles under minimum faradic current intensity.

XI- Simultaneous stimulation of both crico-thyroid muscles under higher current intensity.

XII- Vocal cords on quiet respiration at the end of the experiments.

our own series the shift of the position, during 6 to 8 weeks post-operative observation was not considered enough to bring asphyxia.

All our dogs had an adequate airway about 4 mm. or more and none of them was suffocated.

In man this period of transition has not clearly been reported, but it probably is faster than in the dog. The reason is the factor of

added contraction of the interarytenoidus to that of the crico-thyroids. Clerf has reported a case in which the cord moved to the midline 17 days following the injury to the nerve. But generally, while there are a few reports that the cords moved gradually to the midline in 8-10 weeks, there are other reports that they never came to the midline and stayed in a paramedian position even after a long period of observation. (Fig. 2)

4- Sectioning of one recurrent laryngeal nerve will produce the unilateral phenomenon described above with some dyspnea on exertion. There is moderate or no hoarseness on phonation, because of the contralateral cord compensation crossing the midline.

5- Bilateral sectioning of the external laryngeal nerves, does not produce a striking effect on the glottic picture. There is no difficulty in swallowing or breathing. However, since the crico-thyroids are the tensor muscles of the vocal cords, their paralysis produce hoarseness and wrinkling of the cords on phonation. Unilateral sectioning of this nerve has not produced any substantial effect.

6- Sectioning of both recurrent and the external laryngeal nerve on one side, in the dog, will produce complete paralysis of the vocal cord on that side with a marked aphonia. The glottis is asymmetrical in appearance. (Fig. 2)

The vocal cord on the side where the recurrent and the external laryngeal nerves were severed, will be in a cadaveric position, whereas in the opposite side the cord will have a paramedian position. This was proved in 3 of our dogs. The vocal cords of these animals on the side where the external laryngeal nerve was not severed, were almost $1/2$ to $3/4$ of mm. closer to the midline than on the opposite side.

7- Bilateral sectioning of the external laryngeal nerves and the recurrents results in complete paralysis of all the muscles of the larynx. The cords will stay in the cadaveric position and there is a complete aphonia (Fig 2).

IV-Practical and therapeutic results of this work: —

As we have seen following bilateral injury to the recurrent laryngeal nerves during surgical procedures, the vocal cords gradually shift to the midline and the patient goes into stridor and dyspnea, which may some-

times become serious and result to asphyxia and death.

The current treatment for this condition has so far been first a tracheotomy to relieve dyspnea and stridor. Then this will be followed by various technics of laryngoplastic procedures, such as described by Rethi in Europe and Brien king, Kelly, etc. in the United States. These procedures, although satisfactory to certain extent, are rather complicated and not always successful.

From what has been studied here, one can easily realize, that in the bilateral midline paralysis of the vocal cords since the chief reason for midline positioning is the contraction of the crico-thyroid and the interarytenoid muscles, elimination of the former's action could be used as a prophylactic and therapeutic method to handle these patients with very little amount of surgery and intervention.

In fact a unilateral or bilateral crico-thyroid myomectomy through a small incision could produce cosmetic and satisfactory results.

V- Conclusions:—

1—When a recurrent laryngeal nerve is traumatized, cut or ligated during some surgical procedure, both the abductor and adductor functions of the vocal cord will be simultaneously eliminated and it first seems logical that the vocal cord should stay in the cadaveric position.

2— However, clinical observations have proved that, under such circumstances, the vocal cords very often stay first in a paramedian position and then gradually shift to the midline and produce dyspnea and stridor which sometimes necessitates tracheotomy followed by laryngoplastic procedures.

3— Very recent experimental works in man and in the dog have shown that the innervation of the interarytenoid muscle is different in these two species:

In the dog this muscle receives its innervation only from the recurrent laryngeal nerve. In man the interarytenoidus has a double innervation: It is not only innervated from both sides, but in each side it receives double innervation from both the superior (the internal laryngeal) and the inferior (recurrent) laryngeal nerves.

4— Our experimental works, as well as those of others, prove that the

crico-thyroid muscle is not only a tensor of the vocal cord, but it is also an adductor.

5-The Semon's Law does not seem to us a satisfactory explanation for the peculiar behaviour of the vocal cords following an irreversible traumatic injury to the recurrent laryngeal nerve.

6-The answer should be searched in the adduction function of the crico-thyroid as well as in the double innervation of the interarytenoid muscle. The continuous tension and adduction brought to the vocal cord, by the crico-thyroid, will place it first in a paramedian position and then, if the pull is strong enough, into a final median position.

7-When the recurrent nerves are irreversibly traumatized, a prophylactic crico-thyroid myomectomy could prevent gradual shift of the vocal cord to the midline, and therefore no more necessitate eventual tracheotomy and uncosmetic laryngoplastic procedures for such patients.

369 Raazi Avenue, Chabar-Rah Bahrami, Teheran.

Conclusions:—

1- Quand le nerf récurrent du larynx est traumatisé, coupé ou suturé pendant une intervention chirurgicale, telle qu'une thyroïdec-tomie ou une diverticuléctomie de l'œsophage, les fonctions d'abduction et d'adduction de la corde vocale correspondante seront simultanément interrompues.

2- D'abord il semble naturel que la corde vocale paralysée doit occuper une position cadavérique. Mais, les observations cliniques nous ont montré que la corde vocale, dans une circonstance pareille, occupe très souvent d'abord une position paramédiane et plutard graduellement elle se déplace à la position médiane. Alors, si la paralysie est bilatérale, il peut se produire de dyspnée marquée et des bruits striduleux et par conséquent quelquefois nécessiter une trachéotomie suivie par des interventions laryngoplastiques

3- Les travaux expérimentaux récents chez l'homme et le chien ont montré que l'innervation du muscle interaryténoïdien est différente chez ces deux espèces: chez le chien, ce muscle reçoit son innervation seulement du nerf récurrent. Chez l'homme le muscle interaryténoïdien

a une double innervation. Il est non seulement innervé par des deux côtés du larynx; mais aussi chaque côté est innervé doublement et par le nerf récurrent et par la branche interne du nerf laryngé supérieur.

4- Nos travaux expérimentaux, aussi bien que ceux des autres, ont prouvé que le muscle crico-thyroïdien du larynx est non seulement un tenseur de la corde vocale, mais aussi il est un adducteur.

5- La Loi de Semon ne nous semble pas une explication satisfaisante pour la conduite péculière des cordes vocales et leur positions médianes suivant un traumatisme irréversible du nerf récurrent.

6- Il nous semble qu'il faut chercher la réponse dans la fonction adductrice du muscle crico-thyroïdien; aussi bien que dans la double innervation du muscle interaryténoïdien. La tension et l'adduction continues venant de la part du muscle crico-thyroïdien sur la corde vocale, la placeront d'abord dans une position paramédiane, et finalement, si la force est suffisamment forte, dans une position médiane.

7- Quand les nerfs récurrents sont irréversiblement traumatisés, une myoméctomie crico-thyroïdienne prophylactique peut empêcher le déplacement graduel des cordes vocales à la ligne médiane, et par conséquent ne pas nécessiter la trachéotomie éventuelle aussi bien que d'autres interventions compliquées et inesthétiques de nature laryngoplastiques.

BIBLIOGRAPHY

- 1- Berlin, D.: «The recurrent Laryngeal Nerve in Total Ablation of the Thyroid Gland», *Surg., Gyn. and Obs.* 60: 19, 1935.
- 2- Clerf, L. H. «Paralysis of the Larynx—A Study of 270 cases», *Annals of Oto., Rhin., and Laryn.* 50: 762, 1941.
- 3- Fisher, N. D. «Preliminary Report on an Application of the Function of the Superior Laryngeal Nerve», *Annals of Oto., Rhin and Laryn.* 61: 352, 1952.
- 4- Hedayaty, J.: «Paralysis of the Vocal Cords. Some Experimental Works on the Role of the Crico-Thyroid Muscle Concerning Bilateral Midline Paralysis». Master of Medical Science Degree Thesis, (Unpublished) Temple University, Philadelphia, May 1953.
- 5- King, Brien T., and Gregg, R. «Annals of Oto., Rhin., and Laryn», 51: 925, 1948.

- 6- Lemere, F.: «Innervation of the Larynx. III-Experimental Paralysis of the Laryngeal Nerves». Arch. of Oto., 18: 413, 1933.
- 7-Menzel, K.M.: «Zur Frage Der Recurrenslahmung». Arch. Fur Laryn. U. Rhin. 34: 65, 1921.
- 8- Morisson, L. F.: «Recurrent Laryngeal Nerve Paralysis. A Revised Conception Based on the Dissection of one Hundred Cadavers» Ann. of Oto., Rhin., and Laryn., 61: 567, 1952.
- 9-Negus, V. E. «Observations on Semon's Law» Journal of Laryn., and Oto., 46 : 1, 1931
- 10- New, G. B., and Childrey: «Paralysis of the Vocal Cords. A Study of 217 Medical Cases »,Arch. of Oto., 16: 143: 1932.
- 11- Semon, Felix: Proclivity to Disease of the Abductor Fibers», Arch. Laryn., 2: 197, July 1881.
- 12- Smith, A. B., Lambert and Wallace: «Paralysis of the Recurrent Laryngeal Nerves «Edinb. Med. Journal, 40: 344, 1933.
- 13- Suehs. «Paralysis of the Larynx. A Study of 270 Cases» Ann. of Oto., Rhin., and Laryn., 50: 762, 1941.
- 14- Terracol, J.: «Les Paralysies Laryngées Périphériques», Rev. de Laryn. Paris, 52: 231, 1931.
- 15- Todd, H. H.: «Innervation of the Larynx», Unpublished Master's Thesis, Loyola University, Chicago, 1938.
- 16- Vogel, P. H.: «The Innervation of the Larynx of Man and the Dog», Am.J. of Anatomy, 90: 427, 1952.
- 17 -Ziegelman, E. F. : «Laryngeal Nerves-Surgical importance in Relation to the Thyroid Arteries, Thyroid Gland and Larynx».Arch. of Oto. 18: 793, 1933.