

A RARE CASE OF ORIGIN OF THE SUPERIOR THYROID ARTERY  
FROM THE RIGHT COMMON CAROTID ARTERY.

Y MOHAMADI

INTRODUCTION

A number of authors, including ARNUF(2), KIRCHMAIR(7), and others, on the basis of analysis of autopsy materials, call the attention of clinicians to variations in the origin of the superior and inferior thyroid arteries. In the surgical literature, CATTELL, PHILLIPS(4) and GORSKI (6) have discussed the danger of injuring atypically originating large cervical arteries during operations on the thyroid gland. Accordingly, we report the following case, which appears to be unique in the combination of sex and side of origin.

CASE REPORT

In the course of an anterior neck dissection of an about 60 years old male, a rare type of an extremely low origin of the right superior thyroid artery from the right common carotid artery was encountered. No other variations were found in this body. The artery arose 31 mm

---

Associate Professor of Department of Anatomy, University  
of Tehran, Faculty of Medicine

---

proximal to the bulbe of the right common carotid at the level of one-third of the height of the right lobe of the thyroid gland. From this origin, the artery runs inferiorly and medially over a distance of about 15 mm, and after giving a small branch to the sterno-cleidomastoid muscle, disappeared posterior to the superior belly of the omohyoid muscle. Upon reflecting the omohyoid, the artery was discovered to continue medially, passing posterior to the sternothyroid muscle and entering the anterior aspect of the right lateral lobe of the thyroid gland as two branches. The first thinner branch ramified in the thyroid lobe in typical fashion. The second much wider branch descended between the lobe of the thyroid gland and isthmus, penetrating the parenchyma of the gland and forming numerous anastomoses with the arterial branches of the contralateral side.

#### DISCUSSION

Vascular variations of arteries supplying different organs are a frequent subject of published case reports, constituting the basis for the elaboration of an arterial schema in man. It is generally believed that the thyroid arteries may arise:

a) from the external carotid artery, b) from the site of division of the common carotid artery, and c) from the common carotid artery. Frequency of low origin of the superior thyroid artery varies considerably depending upon the population being studied, or perhaps upon what one chooses to define as a low origin of the artery. Some of the variability is, no doubt, due to observational

bias as to what constitutes the region of the bifurcation. One of the most comprehensive studies on this subject is that by ADACHI (1). There is also considerable sexual dimorphism in the appearance of this variation. ADACHI presents data demonstrating a greater frequency in females than males. He also discovered that the variation occurs more commonly on the left than on the

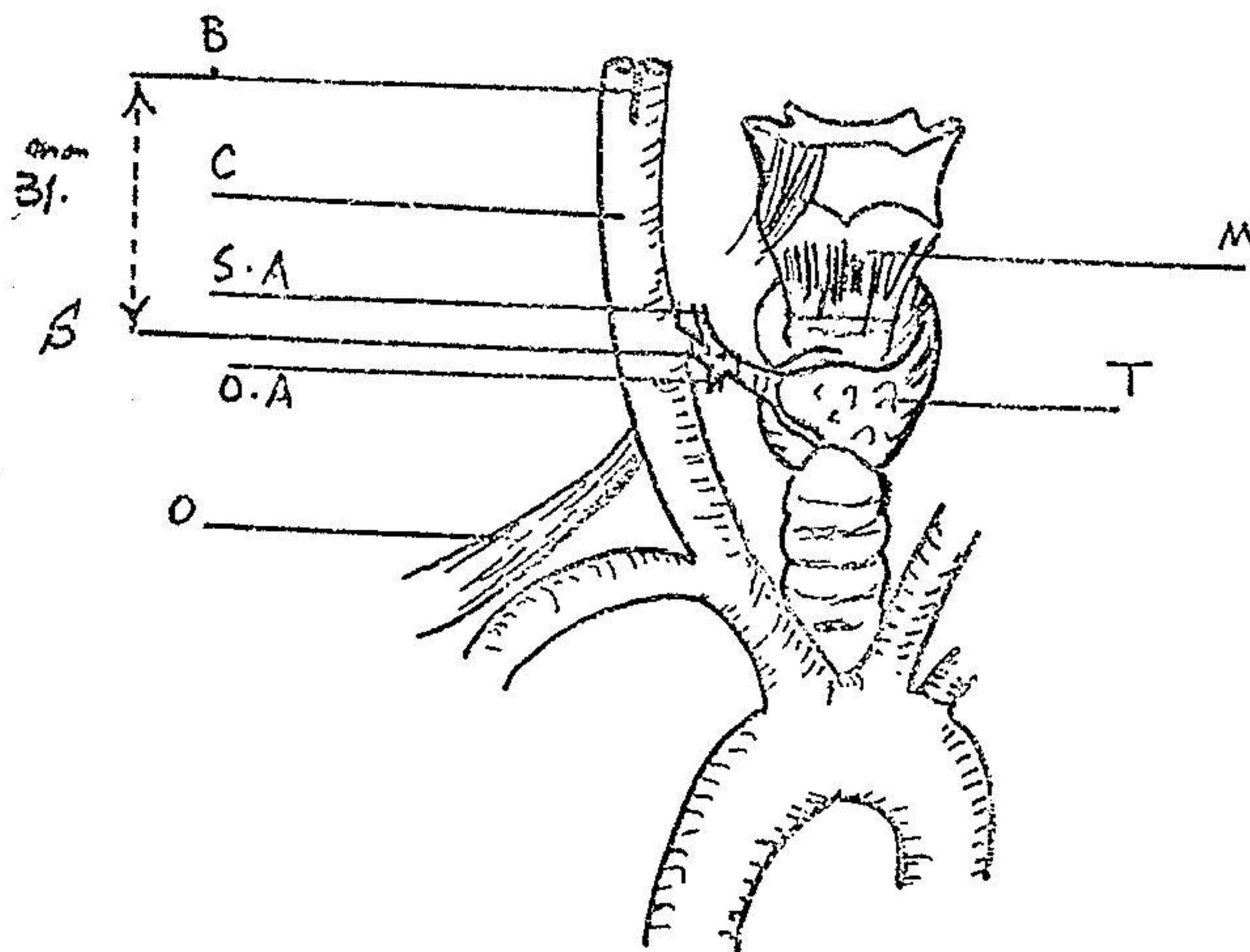


Fig.1- Variation of the superior thyroid artery. B- Bifurcation. C-Common carotid artery. M-Sternothyroid muscle. O-omohyoid muscle. O.A- Omohvoid artery. S-Superior thyroid artery. S.A-sternocleidomastoid artery. T-Thyroid gland.

right. ADACHI found only 4.7% of superior thyroid arteries arising from the common carotid on the right, but 22.0% from it on the left. The same is true for arteries springing from the bifurcation: 19.3% on the right and 35.3% on the left. Thus, it is clear that the origin of the superior thyroid artery is shifted proximally on the left side. The same trends were observed by BRAINE (3), FALLER, (5) POISEL and GOLTH. (8)

The above discussion demonstrates that a low origin of the superior thyroid artery is hardly rare. However, there are only three previous reports in the literature of origins 2 cm-2.7 cm proximal to the bifurcation and they have all been on the left side (KUKWA and ZBRODWSKI (9), ADACHI, BRAINE and FUNCK-BRENTANO).

So the present case is only the first report in the literature of a superior thyroid artery arising from the common carotid more than 2.7 cm proximal to the bifurcation. Moreover, so far as we can ascertain, it is the only case arising so far proximally on the right side. Considering ADACHI'S data, it is more remarkable still by being found in a male.

#### SUMMARY

Recently in a classroom dissection we found an anomalous superior thyroid artery in a 60-year-old man. The artery originated from the common carotid 31 mm proximal to its bifurcation. Regarding to the sex, the side and place of origin, this could be a unique case, suggesting a need for more awareness of any unpredictable anomaly which may be seen in this artery to avoid serious problems during surgery on the thyroid gland.

## REFERENCES

1. ADACHI, B. A.: DAS Arteriensystem der JAPANER, Vol.1 (MARUZEN, Kyoto 1928).
2. ARNULF, G.: Pathologie et Chirurgie des Carotides, MASSON et CIF, ed. 8. PARIS 1957.
3. BRAINE, J. et FUNCK, BRENTANO, P.: Les Variations des Arteres du Corps Thyroide. Etude d'Anatomie Chisurgical. Annls Anat. Path. 11:125-155(1934)
4. CATTELL, R.B., PHILIPS, E.S.: Posgrad, Med., 1949,5, 137.
5. FALLER, A. und SCHARER, O.: Ubr die Variabilitat der Arteriae Threvideae. Acta anat. 4: 119-122 (1947)
6. GORSKI, M.: PRZEGL. LEK., 1970, 7, 271.
7. KIRCHMAIR, H.: WIEN KLIN. WSCHR., 1973., 65, 197.
8. POISEL, S. und GOLTH, D.: ZUR Variabilitat der Gros-sen Anterien im Trigonum Caroticum. Wien Med WSCHN. 124:229-232 (1974).
9. ZBRODOWSKI, A. KUKWA: A. Rare Case of the Superior Thyroid Artery. FOLIA Morph. 25:600-602 (1966).