

# RADIATION-INDUCED SARCOMA OF CHEST WALL FOLLOWING BREAST CANCER THERAPY

Yousef Valizadeh, \* MD and Hooshang Mohammadi, \*\* PhD

*Abstract—A woman patient who had received external radiotherapy for breast cancer developed secondary tumor in the irradiated area after nine years. We offer our observation on this case which seems to be radiation-induced sarcoma.*

*Acta Medica Iranica 33 (1&2): 43-46; 1995*

*Key words: breast cancer; radiotherapy; sarcoma*

## INTRODUCTION

There are established reports in the literature concerning a small risk of post-irradiation of soft tissue sarcomas. The long-surviving cancer patients with history of radiotherapy face maximum risk of developing secondary sarcomas, which is approximately 0.5% for five years after irradiation. Of the 1,310 patients of breast cancer who were irradiated in Cancer Institute, during the past 15 years, this is the first case of established secondary soft tissue sarcoma, following radiotherapy.

## CASE HISTORY

In November 1990, a 58-year-old woman admitted to Cancer Institute, complaining of burning pain in the left anterior chest wall.

She had a history of left breast cancer in 1981. Medical reports showed that her primary lesion was a tumoral mass in the upper outer quadrant of the left breast with nipple retraction and axillary adenopathy. Radical mastectomy was done and pathology report revealed infiltrating duct cell carcinoma (Fig. 1) of stage

III (T3 N1). There was no evidence of any distant metastasis (MO). She received post-operative external radiotherapy to her left chest wall and regional nodes with <sup>60</sup>Co machine, in 25 fractions, totalling 50 Gy. She was well for the next nine years and her clinical follow-up revealed no problem until 1990 when she noted a burning sensation on the left chest wall near the previous surgical scar in the irradiated field. Later, she noticed a soft tissue nodule in the same region. Whole body bone scan revealed an increased uptake in the mid left ribs. Chest x-ray was normal. Thorax CT showed a suspicious small soft tissue mass next to the left sixth rib.

In November 1990, the nodule was excised completely and pathology report showed "Spindle cell sarcoma suggestive of osteosarcoma." Slide review in Cancer Institute was reported as "Sarcoma with osteoblastic activity" (Figs. 2 and 3). Then, the patient was referred to Cancer Institute and for wider excision of soft tissue with mid portion of anterior arches of 5th, 6th, and 7th ribs. The chest wall was also repaired. The pathology report showed no residual tumor. Now, the patient is in good condition and all her physical and paraclinical reports are normal.

## DISCUSSION

There is no way to relate a secondary malignancy to previous radiotherapy, with certainty, as a cause and effect relation. But there are established reports of developing sarcomas in the previously irradiated fields, suggestive of consequence of earlier radiotherapy. There are no direct estimates of radiation induced sarcomas; the estimate of risk is an overall judgement.

Cahan's criteria which roughly estimate radiation-induced sarcomas are as follows:

1. Previous radiotherapy with a dose range of 20

\*Associate Professor, Department of Surgery, Cancer Institute, Imam-Khomeini hospital; \*\*Associate Professor, Research Institute for Nuclear Medicine, Faculty of Medicine, Tehran University of Medical Sciences, Tehran, Iran.

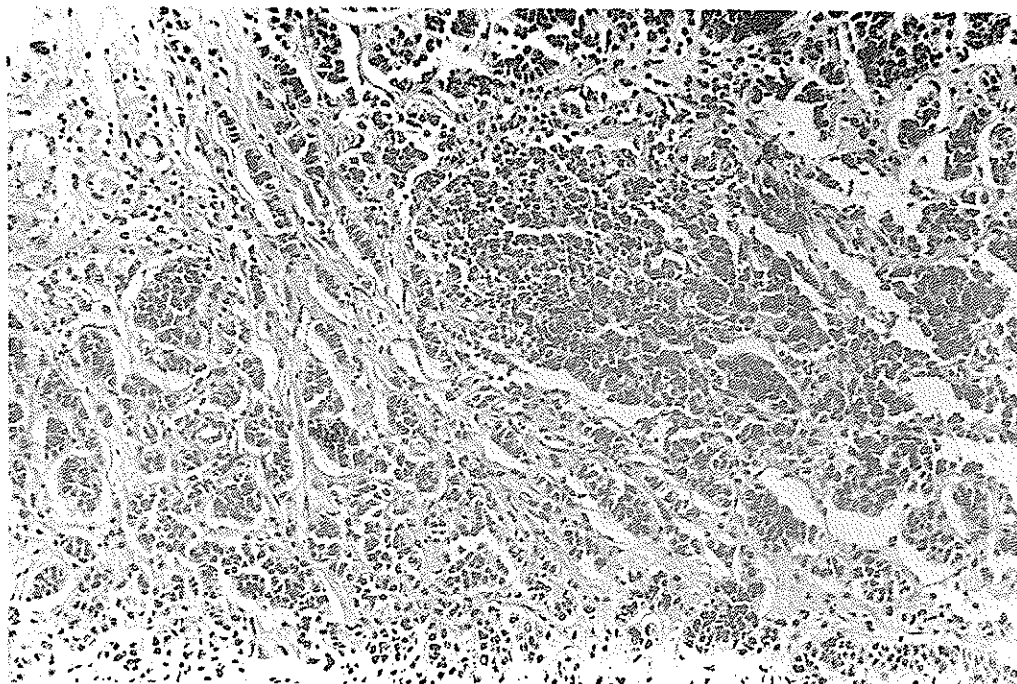


Fig. 1. Infiltrating ductal carcinoma. Nests of atypical epithelial cells, in fibrotic stroma.

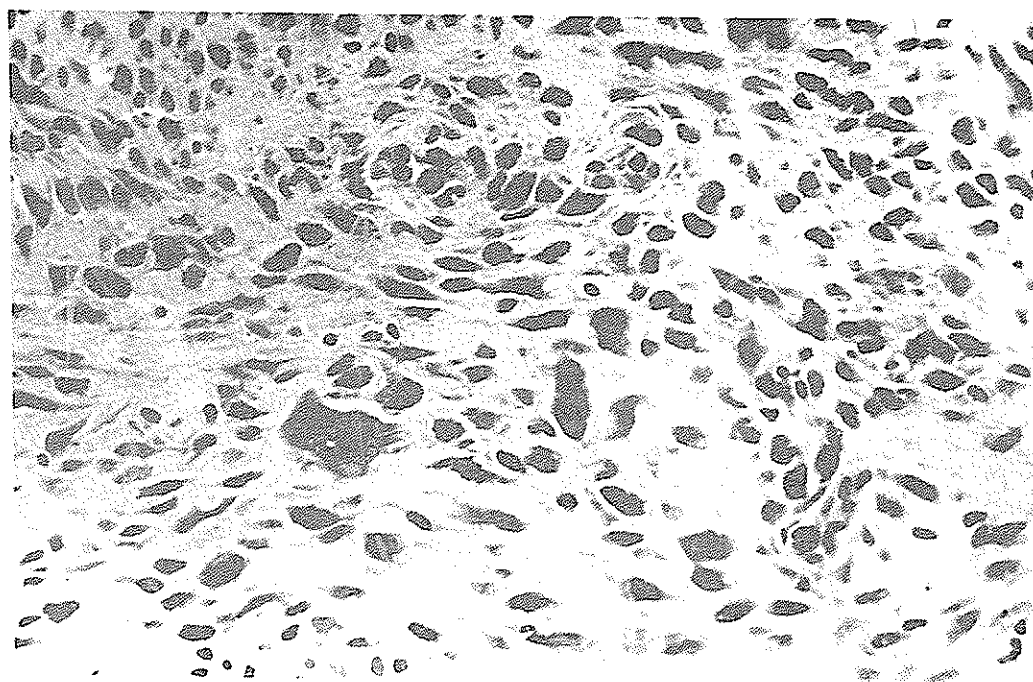


Fig. 2. Sarcomatous tissue with cellular pleomorphism.

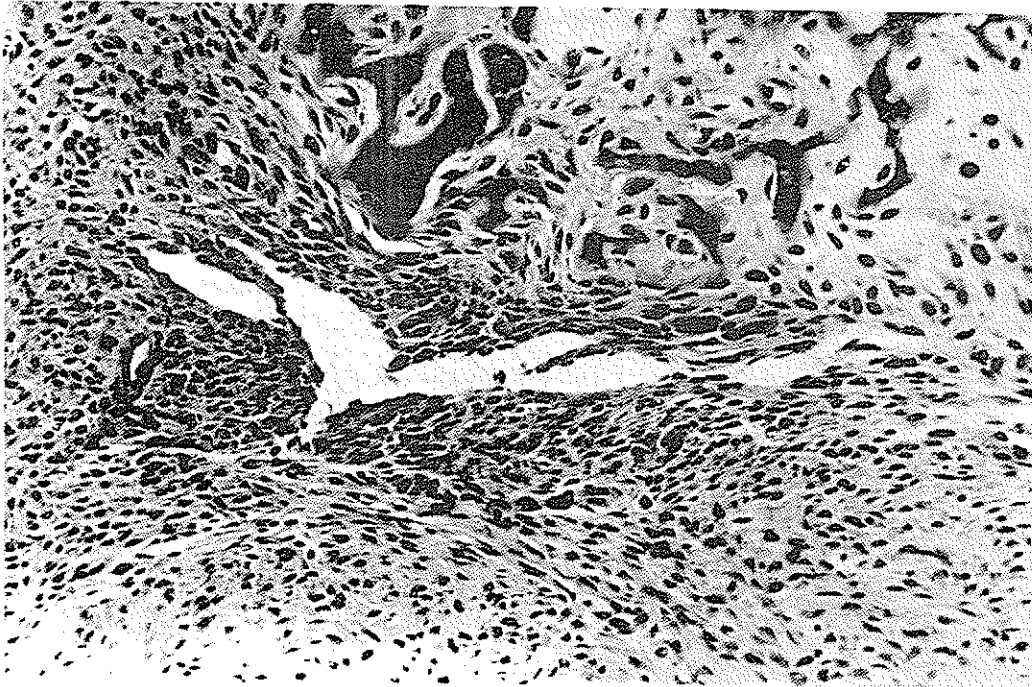

Fig. 3. Sarcomatous tissue produced bony trabeculae.

Gy to 100 Gy;

2. Relative long term latency (at least 3-5 years);
3. New tumor with different pathology;
4. New tumor in previously irradiated field.

Prior radiotherapy as a potential risk factor for induction of secondary sarcomas has frequently been reported for bone and soft tissues (6). Overall incidence rate of secondary malignancies is difficult to quantitate, but is probably less than 1-2% (7). Souba and associates (8) reported that 5% of sarcomas of the chest wall occurred in patients who had received prior chest wall irradiation.

A review carried out by Weatherby et al (3) on 6800 patients with primary neoplasms of bone, who were seen at the Mayo Clinic, revealed that post-irradiation sarcomas constituted 1.5%. Of his 78 cases, 35 arose in bone that was normal at the time of radiation therapy and 43 in irradiated pre-existing lesions.

Oncogenes could be activated by radiation but the exact mechanism is not understood. Because of variable and long-latent period (5 to 28 years), it is advisable to consider radiation as an initiator in inducing these malignancies. It seems that different gene loci are associated with fibroblast malignant transformation. The process takes a long time. Radiation induces chromosome aberrations both with a low energy transfer (LET) and in dose-dependent manner (4); association of

the breakpoints and human cellular oncogenes suggests a possible mechanism of radiation-induced cancer (5).

Despite rarity of this late complication of radiotherapy, it is important to pay more attention to appropriate indications and computer-planned radiotherapy for cancer patients. Any physician who knows the history of cancer and therapy of patient should be aware of elevated risk of developing a secondary malignancy. Careful examination of the skin in the irradiated region should be routinely carried out, especially in long-surviving cancer patients. Any abnormal findings must be taken very seriously.

It is important to emphasize the rarity of this process and keep in mind that the benefit of radiotherapy exceeds the risk of secondary tumors.

## REFERENCES

1. Gunko RI. Radiation induced sarcoma following Hodgkin's disease. *Eur Surg Oncol.* 16 (6): 512; 1990.
2. Wlodzimierz R et al. Induced sarcomas following radiation treatment for uterine carcinomas. *Eur Surg Oncol.* 17 (6): 585; 1991.
3. Carlos A, Perez B. Principles and practice of radiation oncology, 2nd edition. Philadelphia: Lippincott; 1992: 512.

4. Lloyd DC, Pur O, Dolphin GW. Chromosome aberrations induced in human lymphocytes by neutron irradiation. *Int J Radiat Biol.* **29**: 169; 1986.
5. Le Beai MM, Rowley JD. Chromosomal abnormalities in leukemia and lymphoma. *Adv Hum Genet.* **15**: 1;1986.
6. Davidson WH. Radiation induced soft tissue sarcoma. *Br J Surg.* **73**: 308-309; 1986.
7. William TM, Cox JD. Radiation oncology, 6th edition. New York: Mosby Co. ; 1994: 685.
8. Souba et al. Radiation-induced sarcomas of the chest wall. *Cancer* **57**: 610; 1986.
9. Sawey MJH. Activation of C-my and C-X-Ras oncogenes in primary rat tumor induced by ionizing radiation. *Mol Cell Biol.* **7**: 932; 1987.

