

# EARLY (SUPERFICIAL) ESOPHAGEAL CARCINOMA AND REPORT OF TWO CASES

Farokh Tirgari,\* MD and Siamak Granmayeh,\*\*MD

*Abstract— Early esophageal carcinoma defined as carcinoma with invasion limited to the mucosa or submucosa, is being increasingly recognized. Timely diagnosis of this early form of esophageal neoplasia provides the opportunity for curative resection. We found 2 cases of this entity among 533 cases of esophageal squamous cell carcinomas resected between 1989 and 1993 in the Cancer Institute of Tehran University of Medical Sciences.*

*Acta Medica Iranica 33(1&2):52-54; 1995*

*Key words: Esophagus, squamous cell carcinoma*

## INTRODUCTION

Iran is one of the high risk areas for esophageal carcinoma in the world; the northeast part is located on esophageal cancer belt extending from northern China.

In areas of China in which large-scale screening is performed, EEC accounts for nearly 90 percent of all esophageal carcinoma, but in Europe and Japan, it constitutes 0.75% and 20% of all resected cases, respectively (1,2).

## MATERIALS AND METHODS

The surgical pathology files of Cancer Institute were reviewed for the years 1989 through 1993 for cases of squamous cell carcinoma (SCC) of the esophagus in which tumor invasion was limited to the mucosa or submucosa. We encountered only two cases of early esophageal carcinoma (EEC), one in 1991 and the other in 1993.

\*Associate Professor, Department of Pathology, Cancer Institute, Imam-Khomeini Hospital; \*\*Resident-in-Training, Faculty of Medicine, Tehran University of Medical Sciences, Tehran, Iran.

The clinical, radiographic and endoscopic findings were determined. The pathology reports and histopathologic slides were reviewed to determine the gross and microscopic characteristics of the resected specimens. Follow-up data were obtained through contact with the patients.

## RESULTS

From 1989-1993, 533 patients with SCC of the esophagus underwent resection. Two patients were recorded (0.04%) as follows:

### Case one

A 57-years-old male from Amol presented with a 10-year history of heart burn; his symptom was aggravated 7 months before admission.

On endoscopy, an esophageal mass was found in the middle third of and esophagus biopsy, which was done twice, showed severe dysplasia of mucosa. Subsequently, the patient underwent distal esophagectomy and macroscopically, a small 0.5-cm ulcerative lesion was found in the mucosa. Microscopic examination showed multifocal SCC in situ with a focus of microinvasion (Fig. 1). Deeper layers showed only inflammation. Now, after about 3 years the patient is well and tumor free.

### Case two

A 57-year-old female from Sanandaj with a 2-month history of dysphagia.

Barium meal showed irregularity of lower third of esophagus with some mucosal defects. Endoscopic examination revealed a mass in lower third of esophagus, 31 cm from incisor, and with irregular and friable surface. Biopsy showed squamous cell carcinoma and distal esophagectomy was performed. On gross examination of

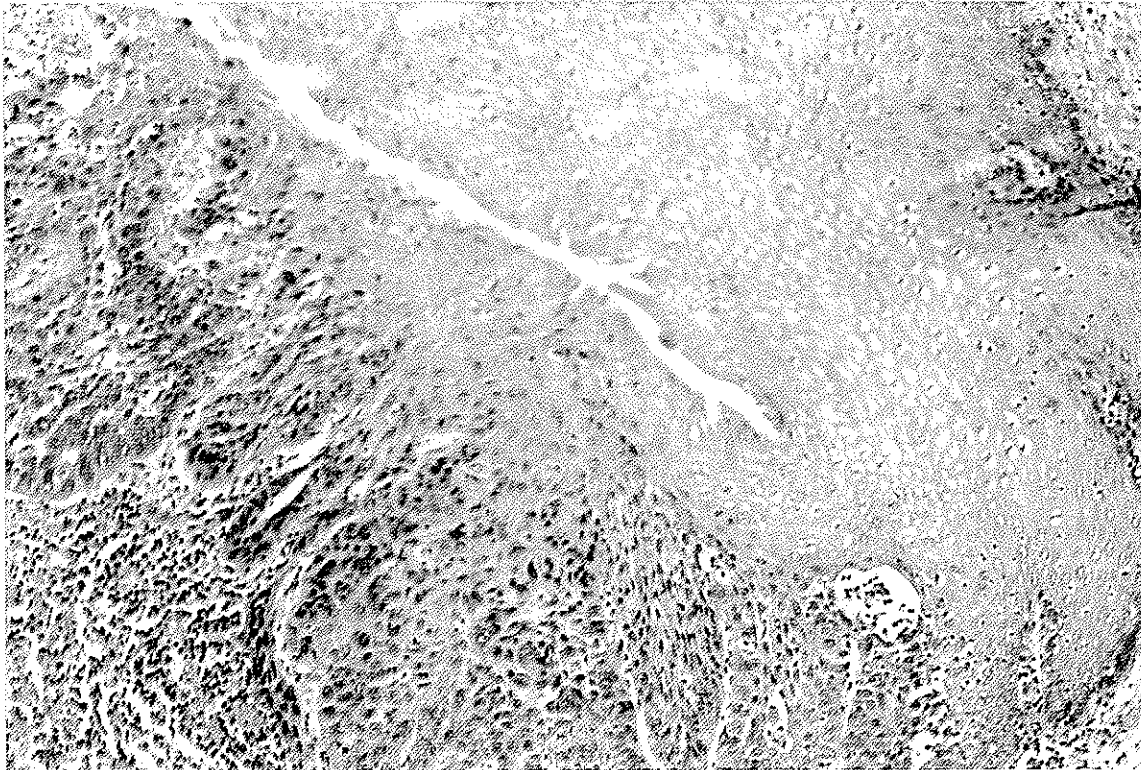


Fig. 1. (Case I) Severe dysplasia of esophagus. The lesion borders on carcinoma in situ (H & E, HPF).

the specimen, a plaque-like tumor, 1cm in diameter was found. Microscopic examination of multiple sections from the whole lesion showed SCC limited to mucosa and submucosa (Fig. 2.). Muscularis propria and adventitia were intact. Now, after about one year the patient is well and tumor free.

## DISCUSSION

There are remarkable geographic variations in the incidence of esophageal cancer worldwide, suggesting that environmental factors are important in the induction and progression of this tumor (1,3,4).

EEC is extremely difficult to detect because the patient may have no complaints and neither could it be revealed by x-ray. It is reported to cause no symptoms in 16 to 34 percent of patients, especially in intraepithelial and mucosal carcinoma, the type of disease which was discovered by coincidence (2,5).

EEC may be missed in routine barium meal and esophageal endoscopy. The use of dyes during endoscopy may aid in identifying neoplastic foci. However, false positive and false negative results can occur (2,6). Radiologic features of mucosal carcinoma appeared as a well-defined smooth or nodular protrusion or as a

feathered flat mucosa with tiny nodulations and barium pooling. Submucosal carcinoma showed a mound-like defect. Since flat lesions are not easy to recognize, attention must therefore be paid not only to mucosal pattern but also the contour of the esophageal wall (6). The entire segment of the involved esophagus may be narrowed to prevent passage of the endoscope, thus it is potentially impossible to obtain tissue biopsy specimens in some cases. Therefore, positive cytologic results in the face of a negative biopsy should not be ignored, but should be followed with repeat biopsies and cytologic studies (1,7).

Four macroscopic types were recognized: plaque like, erosive (ulcerative), papillary (protuberant), and flat (occult). The latter, is usually limited to epithelium and may be missed during routine radiologic and endoscopic examination.

Although there is still controversy whether patients with positive lymph nodes should be considered in this category, survival rates appear to be markedly affected by lymph node metastasis. Therefore, the term EEC should be reserved for lymph node negative cases, in contrast to early gastric cancer (1,8). In one study, tumours limiting the mucosa are reported to metastasize to lymph nodes in 2.2% of cases, while those extending into submucosa demonstrate such metastases in 32.5% of cases.

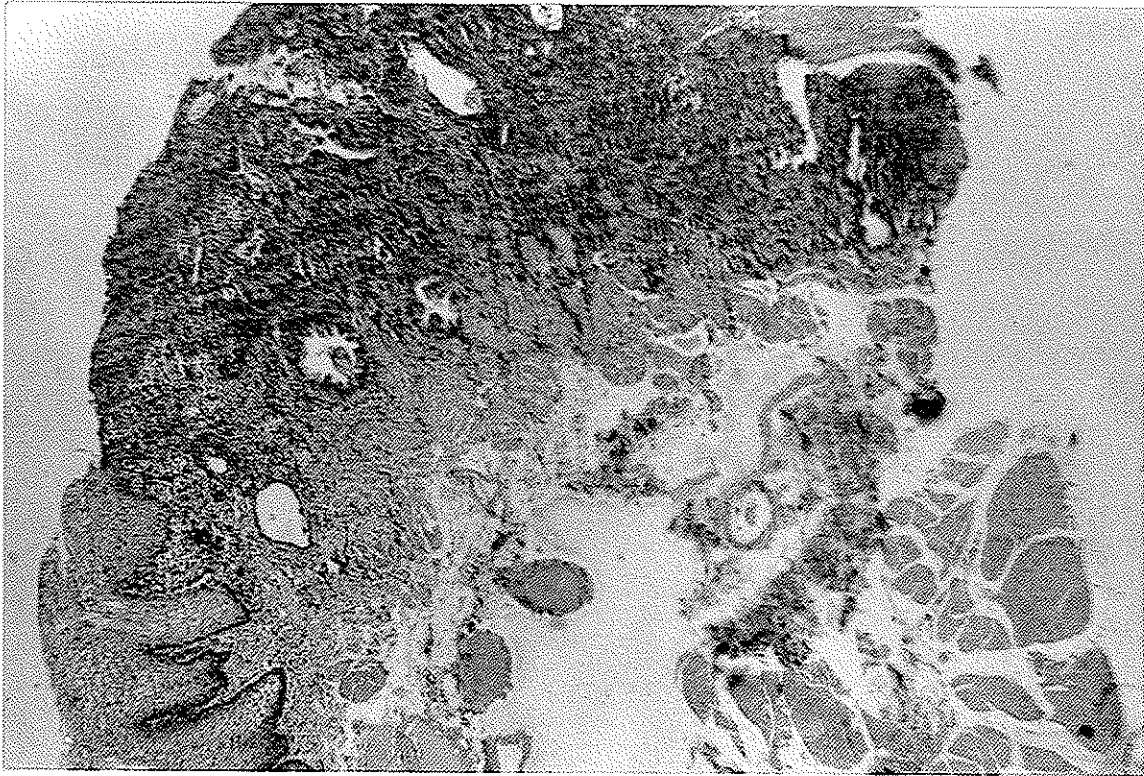


Fig. 2. (Case II) Squamous cell carcinoma of esophagus, invading muscularis mucosa (H & E, I.Pf).

Esophageal carcinoma has a very poor prognosis and despite therapy, only 5 to 10 percent of all patients are alive after 5 years. This poor prognosis is attributed to its advanced stage at the time of diagnosis. Hence, major efforts have been made, particularly in high-incidence regions, to detect the tumor at a relatively early stage. Five-year survival after resection of EEC is reported to be 60 to 90 percent (5). With regard to the high frequency of esophageal carcinoma in Iran, early diagnosis of this lesion with modern endoscopic and cytologic techniques seems warranted.

## REFERENCES

1. Saul S, Enterline H, Thompson J. Early esophageal carcinoma. In: Silverberg SG (ed). Principles and practice of surgical pathology, 2nd ed. New York: Churchill Livingstone; 1990: 1055-1057.
2. Sugimachi K et al. Endoscopic diagnosis of early carcinoma of the esophagus using Lugol's solution. *Gast Endoscopy* 38: 657-661; 1992.
3. Correa P. Precursors of gastric and esophageal cancer. *Cancer* 50: 2554-2560; 1982.
4. Mandard AM. Carcinoma of the oesophagus. In: Whitehead R (ed). *Gastrointestinal and oesophageal pathology*. Edinburgh: Churchill Livingstone; 1989: 632.
5. Harum K et al. Superficial esophageal carcinoma: Report of 27 cases in Japan. *Am J Gastroenterol.* 86 (12): 1723-1728; 1991.
6. Sato T, Sakail K et al. Radiographic microstructure of early esophageal carcinoma. *Gastrointest Radiol.* 1: 12-19; 1985.
7. Wang HH et al. Brushing cytology of the upper GI tract. *Acta Cytologica* 34 (6): 581-586; 1990.
8. Jass R. Early oesophageal cancer. In: Morson BC (ed). *systemic pathology*, 3rd ed. Edinburgh: Churchill Livingstone; 1987: 142.

