

IMMUNOHISTOCHEMICAL DETERMINATION OF TUMOR-ASSOCIATED ANTIGENS IN AMELOBLASTOMA AND ODONTOGENIC CYSTS*

B.K.H. Moghadam¹, I. Yazdi², B. Barker³, C. Cob⁴ and C. G. Cumming⁵

(1) Department of Diagnostic Sciences, School of Dentistry, University of Missouri - Kansas City, USA (2) Department of Oral Pathology, School of Dental Medicine, Tehran University of Medical Sciences, Tehran, Iran (3) Department of oral pathology University of Missouri - Kansas City, USA (4) Department of Oral Biology and Periodontics, University of Missouri - Kansas City USA (5) Department of Diagnostic Sciences, University of Missouri - Kansas city, USA

Abstract — Transforming growth factor alpha (TGF- α), parathyroid hormone-like proteins (PTHLP) and oncogene p53 proteins have all been demonstrated in a variety of human tumors and have been implicated as causes of tumor cell aggressiveness. The present study determined the existence of these peptides and their immunohistochemical profiles in ameloblastomas. Odontogenic keratocysts and dentigerous cysts were included for comparison. Formalin fixed paraffin embedded sections of 22 ameloblastomas, 18 odontogenic keratocysts and 17 dentigerous cysts were examined immunohistochemically. Results showed that 14/22 ameloblastomas demonstrated a very strong positive staining for TGF- α in approximately 95% of the ameloblasts. Staining intensity in the remainder of the ameloblastomas was moderate in 2/22, weak in 1/22 samples and was focal in distribution in 5/22 sections. Immunoreactivity for PTHLP was demonstrated in 20/22 ameloblastomas with variable levels of staining intensity ranging from very strong in 9/22, to moderate in 5/22 and weak in 3/22 specimens. The most intense staining for both antigens was demonstrated at the peripheral margins of invading tumor cells. The staining intensity in the majority of odontogenic cysts was weak or absent. Occasional focal staining with approximately 5% cell positivity and variable staining intensity was found in some specimens. Positive immunoreactivity for p53 oncogene was not demonstrated in any odontogenic lesion types examined in this study. In conclusion, the apparent *in situ* immunolocalization of TGF- α and PTHLP in ameloblast tumor cells indicates that these peptides were produced locally in ameloblastomas. Secondly, their expression were independent of ameloblastoma sub-types and were not altered by fixation methods used to process the formalin fixed paraffin embedded sections. Finally, the original assumptions that ameloblastomas are benign but locally aggressive tumors was supported in this study by showing that these tumors lack p53 oncogene proteins which are indicative of potential malignancies. *Acta Medica Iranica* 35 (1 & 2): 1-7; 1997

Key words: Immunohistochemical determination; tumor-associated antigens; ameloblastomas; odontogenic cysts

INTRODUCTION

Ameloblastoma is a benign, locally invasive odontogenic neoplasm with several morphological variants (1,2). The origin and the exact molecular mechanisms involved in the pathogenesis of the tumor remains unclear. One theory is that the neoplasm may originate from immature epithelial cells of a growing enamel organ which fails to develop into terminally differentiated

ameloblasts (1,2). Other speculated sources of origin include remnants of the enamel organ, the epithelium lining of an odontogenic cyst, and the epithelium of the fetal oral mucosa (2).

Studies on the pattern of normal tooth morphogenesis have shown that some growth promoting agents such as transforming growth factor alpha (TGF- α) are required for the initial development and completion of tooth buds *in vitro* (3). TGF- α is a member of a growth factor family which is synthesized by embryonic cells (4). TGF- α synthesis is upregulated in many human solid tumors (4) including oral squamous cell carcinoma (SCC) (4-8). TGF- α is also over produced in sites of acute and chronic inflammation and in cutaneous wound healing (9).

Other factors such as parathyroid hormone-like proteins (PTHLP) (10-14) and activation of p53 (15,16) oncogenes may also alter the process of normal cell growth and development, and may play an important role in the initiation and promotion of tumor cells.

PTHLP is a protein with potent parathyroid hormone-like bioactivity found in many fetal and adult tissues and is produced by both normal and malignant keratinocytes (10-14). A higher level of PTHLP is expressed by a wide range of squamous cells carcinomas including oral SCC (11,14). Increased expression of p53 proteins has been demonstrated in oral SCC (15,16) and in some odontogenic keratocysts with a recurrent tendency (17).

In addition to their effects on tumor cell proliferation, TGF- α (4,18) and PTHLP (10-12,14) possess a potent osteolytic capabilities causing bone metastasis and hypercalcemia in many malignancies. Ameloblastomas and odontogenic cysts both are harbored within the bone and grow by inducing resorption and erosion in involved bone tissues. This homing property of odontogenic lesions requires an active production and elaboration of

* This study was supported by the NIDR grant NO IR 15DE 9023-01A2

a variety of growth stimulating factors and boneresorbing agents. TGF- α and PTHLP synthesis is fairly common in solid tumors (4,14) and is especially increased in ectodermally derived tumors (4,14).

The purpose of the present study was to determine whether or not these proteins were produced locally by ameloblastomas or odontogenic cysts. The endogenous production and the precise cellular localization of these proteins and of p53 was determined immunohistochemically in paraffin-embedded sections obtained from these lesions.

MATERIALS AND METHOD

Five micron sequential sections from twenty-two ameloblastomas, eighteen odontogenic keratocysts, and seventeen dentigerous cysts were examined immunohistochemically. Ameloblastoma samples included were representative of all ameloblastoma subtypes with variable sizes. They were from both maxillary and mandibular regions of different patient age and sex groups. odontogenic cysts also had variable representatives regarding their sizes, involvement sites and patient sources.

The following three primary monoclonal antibodies were used in this study: anti-TGF- α (Ab-2), anti-PTHLP (Ab-1), and anti-p53 oncogenes (Ab-6). Antibodies were obtained from Oncogene Science Inc. (Cambridge, Massachusetts, USA). Each section was deparaffinized by heating for 24 hours at 56°C and subsequently immersing in xylenes and graded alcohol changes two times each at 10 minute intervals. The deparaffinized sections were then sequentially treated first with 0.1% hydrogen peroxide to suppress endogenous peroxidase activity, next with 0.05% Saponin (Sigma), and finally with a protein blocking agent (10% normal goat serum) to reduce nonspecific background staining. Incubation period for each layer was twenty minutes.

The initial step of immunohistochemical staining involved incubation of sections with 1:10 dilution of each primary monoclonal antibody overnight in a humidified chamber. The next step involved incubation of sections first with multilink biotinylated secondary antibodies and then with peroxidase conjugated streptavidin lable (Bio Genex Supersensitive Multilink Kit, San Ramon, California, USA) for twenty minutes each. Between each step sections were washed in two changes of phosphate-buffered saline (PBS; PH 7.2) for five minutes. Staining was accomplished by incubating the sections with AEC chromogen for five to ten minutes. Following a five-minute washing in distilled water, the sections were counterstained with hematoxylin and mounted for microscopic examination.

Controls

Parallel control sections were processed with each batch of tissues. Sections of normal skin served as positive tissue control for expression of TGF- α (4-8) and PTHLP (11,14) and oral SCC used for expression of p53 (15,16). The nuclear binding of p53 proteins in oral SCC sections also served as a control for specific cytoplasmic staining of TGF- α and PTHLP. Negative controls were non-immune sera and PBS in place of primary antibodies.

The intensity of the staining was assessed by using a semiquantitative scoring in each example. no staining (-), weak staining (+), moderate staining (+2), and highly strong staining (+3). Cell counts performed using an eyepiece graticle ($\times 10$ ocular and $\times 40$ objective) in five randomly selected views in each section.

RESULTS

Immunoreactivity of TGF- α and PTHLP

Positive cytoplasmic staining for TGF- α was demonstrated in individual ameloblast tumor cells in all (n=22) ameloblastoma subtypes examined in this study (Table 1). Immunoreactivity in 14 ameloblastomas was very strong (+3) and was demonstrated in approximately 95% of ameloblasts distributed throughout the tumor section. The staining intensity was particularly strong (+3) at the peripheral margins of the invading strands of tumor cells (Fig. 1). Ameloblasts in one sample with a prominent squamous pattern of growth had strong (+3) positive reaction for TGF- α (Fig. 2). Moderate staining intensity (+2) was detected in 2 ameloblastomas and weak staining intensity (+) in one specimen. The staining distribution in five ameloblastomas was patchy with a variable staining intensity ranging from strong to very weak reaction in a given section.

Immunoreactivity for PTHLP was demonstrated in the cytoplasm of ameloblasts in 20/22 ameloblastomas examined in this study. The diffuse cytoplasmic staining for PTHLP (Fig. 3, Fig. 4) was detected in approximately 95% of the ameloblasts of the follicular and columnar types of ameloblastomas, in most nests of acanthomatous types and in ameloblasts of mural ameloblastomas. Nine ameloblastomas stained very strongly (+3), 5 samples demonstrated a moderate level of staining intensity (+2) and 3 ameloblastomas had a weak staining intensity (+). The staining pattern in three ameloblastomas was patchy in distribution with some strong and weak staining of approximately 30% - 50% ameloblasts distributed across the specimens. Two samples did not stain.

The staining intensity and distribution of TGF- α and PTHLP in odontogenic epithelium of dentigerous cysts and odontogenic keratocytes is summarized in Table 2. In the majority of these lesions, the odontogenic

epithelium demonstrated a weak staining for TGF- α and PTHLP. Some sections had occasional patchy staining with approximately 5% of the positive cells and a variable staining intensity ranging from (+) to (+3).

Table 1. Distribution and staining intensity of TGF- α , PTHLP and p53 in ameloblastomas (total n=22)

	Number of samples stained	Staining intensity	Distribution/Positive Cells
TGF- α	14	(+++)	Approximately 95%
	2	(++)	Approximately 95%
	5	variable (+),(+++)	Patchy (20-30%)
	1	(+)	100%
PTHLP	9	(+++)	Approximately 95%
	5	(++)	Approximately 65%
	3	variable (+++),(+)	Pachy (30-50%)
	3	(+)	100%
	2 didn't stain		
p53	none		

Table 2. Distribution and staining intensity of TGF- α , PTHLP and p53 in dentigerous and odontogenic

	Dentigerous Cysts (Total n=19)	Odontogenic Keratocytes (Total n=18)
	Number of samples/staining intensity and distribution	Number of samples/staining intensity and distribution
TGF- α	2 (+) (all*)	3 (++),(+++)
	13 (+) patchy**	6 (++) patchy
		8 (+) patchy
PTHLP	2 (-) (all)	1 (-) (all)
	4 (+) patchy	2 (+) (all)
	13 (-) (all)	7 (-) (all)
p53	None	None

* all : represents 100% of the odontogenic epithelial cells

** patchy : represents approximately 5% of the odontogenic epithelial cells

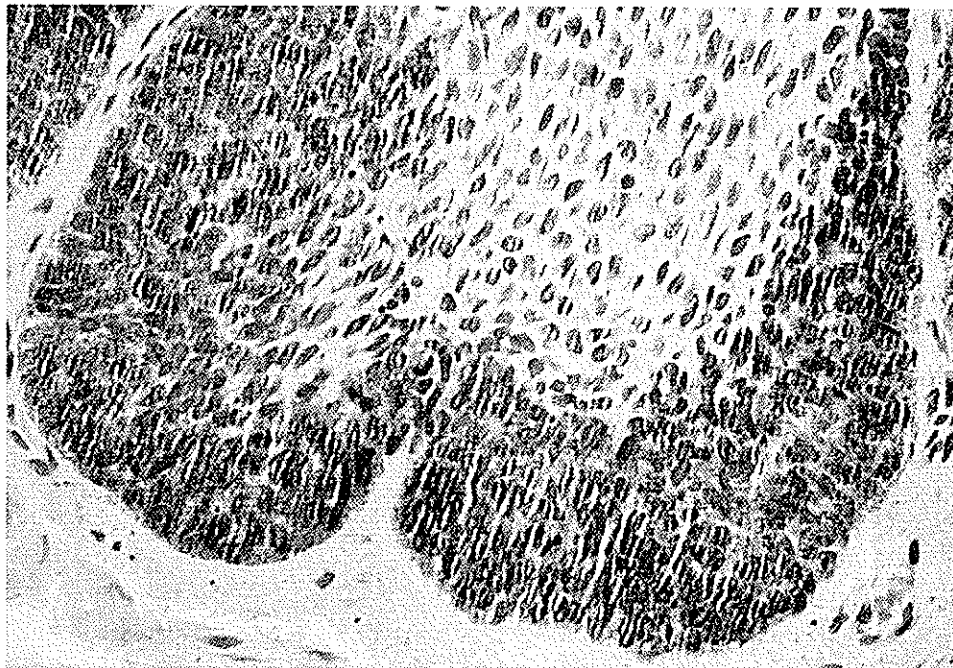


Fig. 1. Ameloblasts at the tumor periphery are strongly positive for TGF-alpha ($\times 400$)

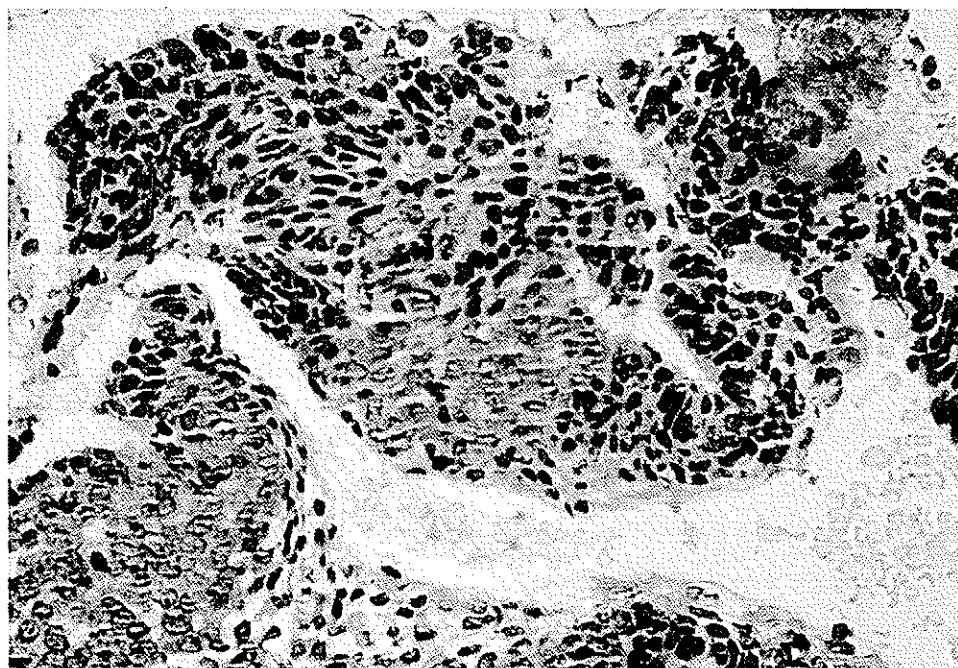


Fig. 2. Ameloblastoma with squamous pattern of differentiation are positive for TGF-alpha ($\times 400$)

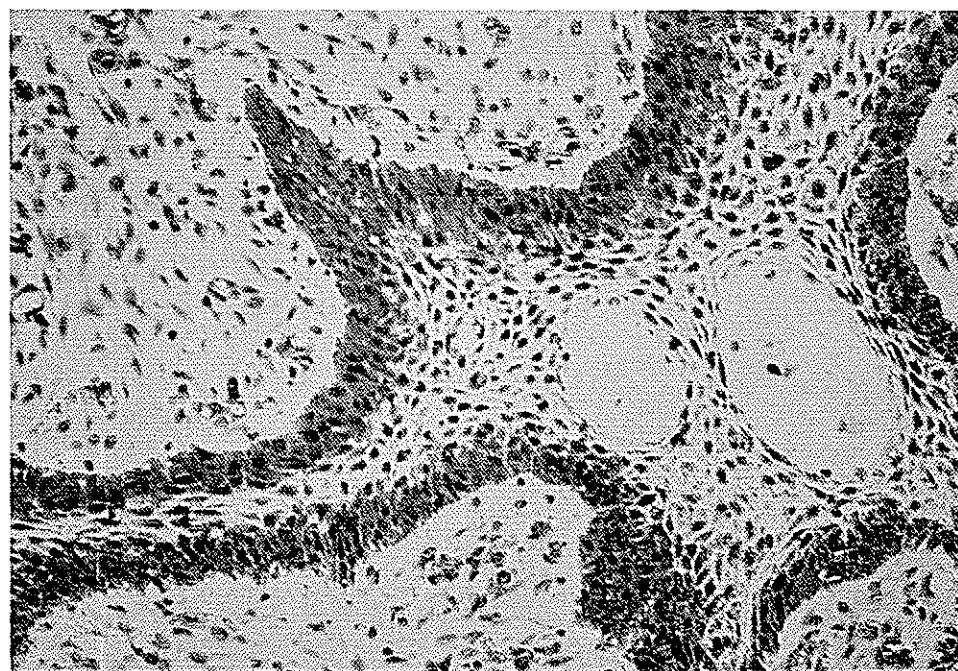


Fig. 3. Immunohistochemical staining of PTHLP at the peripheral margin of an invading island of tumor cells ($\times 200$)

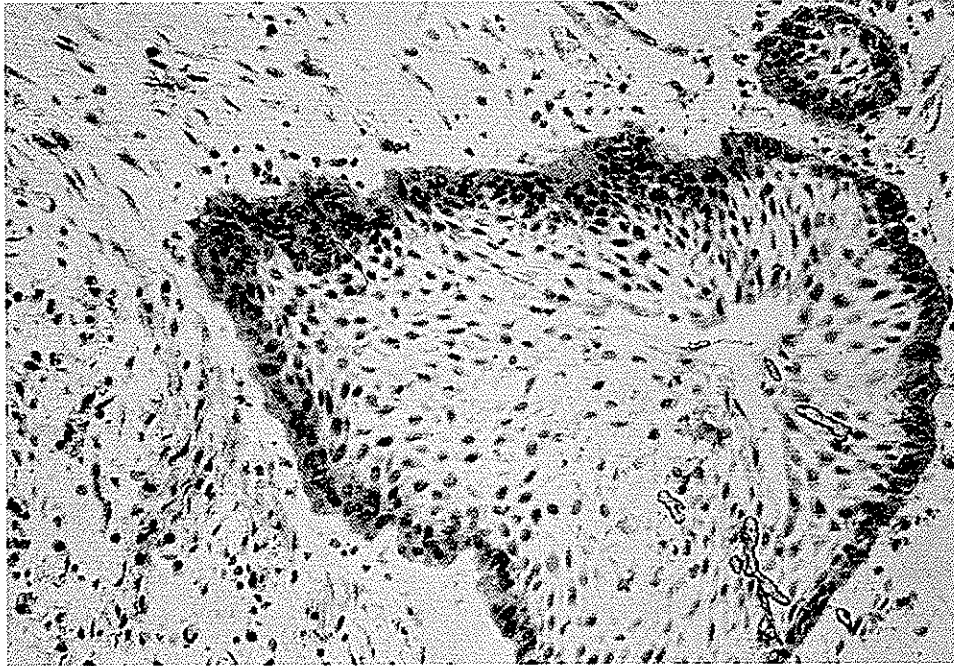


Fig. 4. Intense PTHLP reactivity in ameloblasts located at the border of the tumor ($\times 200$)

Immunoreactivity of p53

Expression of p53 oncogenes was not demonstrated in any section of odontogenic lesions examined in this study but was strongly expressed in all oral SCC samples examined. (positive control).

Control Sections

The staining pattern of positive tissue controls treated with anti-p53 antibodies were precisely nuclear and were detected in all ten samples of oral SCC (s) examined. These sections had a variable number of p53 positive cells distributed throughout the tumor specimen. This particular nuclear staining also served as a control for specific cytoplasmic binding of TGF- α and PTHLP.

The staining intensity of TGF- α and PTHLP in normal skin taken from the palm of the hand (positive control for expression of TGF- α and PTHLP) was moderate (+2). The cytoplasmic staining was demonstrated in all cutaneous keratinocytes throughout the specimen. Staining was not demonstrated in any negative control sections treated with non-immune sera or with PBS in place of primary antibodies.

DISCUSSION

Under normal condition, the process of histogenesis and morphogenesis of tooth buds follows a complex pattern of histodifferentiation accomplished in several

steps (19). This process is influenced by some distinct molecular events (19) of which many remain undetermined to date. Some principle participating factors include induction of genetic information (19), epithelial-mesenchymal interactions (19), and the effects of growth promoting agents such as TGF- α (3,4). These peptides have been shown to participate in the regulation of odontogenic cell morphology and differentiation. In addition, TGF- α has a growth promoting effect on human solid tumors (4,8) and causes local bone resorption thus facilitating penetration of tumor cells (4,9).

Results of the present study with TGF- α indicate that the peptide is present in the majority of ameloblasts in all ameloblastoma subtypes examined. Specially, the more peripheral ameloblasts stained more strongly (Fig. 1). The wide-spread presence of TGF- α in ameloblastomas suggests that this peptide is synthesized endogenously by tumor cells and may contribute to the proliferation of ameloblasts within an established lesion. Moreover, TGF- α may initially stimulate the formation of an early ameloblastoma because it is actively involved in the development of the enamel organ (3,4). Under certain abnormal conditions, the TGF- α alone or in conjunction with other agents can alter the normal process of odontogenesis and stimulate the formation of more aggressive ameloblasts reflective of an ameloblastoma (4,20).

In this study, the majority of ameloblasts in many

ameloblastoma samples examined reacted positively for PTHLP expression, indicating that the peptide is produced in this odontogenic neoplasm (Fig. 3,4). Since PTHLP has the ability to stimulate the growth capacity of many tumors (10,14), it is likely that the peptide may also serve to modulate the proliferation of ameloblastoma tumor cells. In addition, the potent bone resorbing effects of PTHLP (10-14) can contribute to local bone erosion allowing the ameloblastoma tumor cells to invade aggressively within the surrounding bone.

The lower level of TGF- α and PTHLP detected in some odontogenic cysts does not exclude a possible role of these peptide in development of odontogenic cysts.

Ameloblasts in all of the ameloblastoma samples reacted negatively for expression of p53 oncogene proteins. Since the over-expression of p53 proteins have been found principally in malignant tumors (15,16), their absence in ameloblastomas support the original concept that the ameloblastoma is essentially a benign odontogenic tumor with a locally invasive pattern (1,2).

The immunoreactivity of p53 was also absent in all odontogenic cysts examined in this study. These results are different from those reported in a recent study (17) showing that 5/12 odontogenic keratocysts were p53 positive. This study, however, reported that among different keratocysts removed from the same patient, some cysts were p53 positive and some were p53 negative indicating that keratocysts could behave differently.

In conclusion, ameloblastomas share some general characteristics of other human solid tumors and commonly synthesize TGF- α and PTHLP which may contribute to their aggressive growth behavior. Secondly, the immunohistochemical expression of these bioactive peptides is not a reflection of ameloblastoma subtypes or other variables such as patient age, sex and the involvement site. Finally, the absence of p53 immunoreactivity in current study indicate that the aggressive clinical behavior of ameloblastomas is unrelated to the activation of oncogene proteins. Further investigations at the molecular levels are required to evaluate the immediate contribution of TGF- α and PTHLP to the growth and development of ameloblastomas and odontogenic cysts. Such investigations may help to better predict the behavior of some recurrent odontogenic lesions and may lead to some therapeutic applications in addition to the surgical excisions.

Acknowledgment

We thank Ann Marie Corry, Harry W. Muller for providing references and checking citations. We also thank Lisa Cabra for her word processing preparation and Jim Thomas for preparation of illustration.

REFERENCES

1. Regezi JA and Sciubba J. Oral Pathology. Clinical-pathologic correlations. Philadelphia: W. B. Saunders, 1993; 362-374.
2. Neville BW, Damm DD, Allen CM and Bouquot JE. Oral Maxillofacial Pathology. Philadelphia: W.B. Saunders, 1995; 362-397.
3. Tam JP. Physiological effects of transforming growth factor in the newborn mouse. Science 1985; 229: 673-675.
4. Derynck R. The Physiology of Transforming Growth Factor Alpha. Adv Cancer Res 1992; 58:27-52.
5. Granids JR and Tweardy DJ. Elevated levels of transforming growth factor-alpha and epidermal growth factor receptor messenger RNA are early markers of carcinogenesis in head and neck cancer. Cancer Res 1993; 53:3579-3584.
6. Prime SS, Game SM, Mathews JB, Stone A, Donnelly MJ, Yeudallwa, et al: Epidermal growth factor and transforming factor alpha characteristics of human oral carcinoma cell lines. Br J Cancer 1994; 69: 8-15.
7. Wong DT. TGF- α and Oral Carcinogenesis. Eur J Cancer B Oral Oncology 1993; 29B (1): 3-7.
8. Kannan R, Gautam NB, Mallery SR, Beck FM, Sabourin CL, Jewell SD, et al: Transforming Growth Factor - alpha Overexpression in Proliferative Verrucous leukoplakia and Oral Squamous Cell Carcinoma. Oral Surg, Oral Med, Oral Path Oral Radiol, Endol 1996; 82: 69-74.
9. Todd R, Donoff RB, Chiang T, Chou MY, Elovic A and Gallagher GT, Wong DT. The Eosinophil as a Cellular Source of TGF- α in Healing Cutaneous Wound. Am J Pathol 1991; 138:1307-1313.
10. Burtis WJ, Brady TG, Orloff JJ, Ersbak JB, Warrell RP, Olson BR, et al: Immunochemical characterization of circulating parathyroid hormone-related protein in patients with humoral hypercalcemia of cancer. N Engl J Med 1990; 322: 1106-1112.
11. Kramer S, Reynolds FH Jr., Castillo M, Valenzuela DM, Thorikay M and Sorvillo JM. Immunological identification and distribution of parathyroid hormone-like protein polypeptides in normal and malignant tissues. Endocrinology 1991; 128: 1927-1937.
12. Henderson JE, Shustik C, Kremer R, Rabbani SA, Hendy GN and Goltzman D. Circulating concentrations of parathyroid hormone-like peptide in malignancy and in hyperparathyroidism. J Bone Mine Res 1990; 5: 105-113.
13. Kaiser SM, Sebag M, Rhim JS, Kremer R and Goltzman D. Antisense-mediated inhibition parathyroid hormone-like peptide production in a keratinocyte cell line impedes differentiation. Mol Endocrinol 1994; 8:139-147.
14. Moseley JM and Gillespie MT. Parathyroid hormone-related Protein. Crit Rev Clin Lab Sci 1995; 32 (3):

299-343.

15. Girod SC, Kreuger G and Pape HD. p53 and Ki67 expression in preneoplastic and neoplastic lesions of the oral mucosa. *Int J Oral Maxillofac Surg* 1993; 22: 285-288.

16. Matsumura T, Yoshihama Y, Kimura T, Shintani S and Alcalde RE. p53 and MDM2 Expression in Oral Squamous Cell Carcinoma. *Oncology* 1996; 53 (4): 308-312.

17. Ogden GR, Chisholm DM, Kiddie RA and Lane DP. p53 Protein in Odontogenic Cysts: Increased Expression In Some Odontogenic Keratinocytes. *J Clin Pathol* 1992; 45: 1007-1010.

18. Ibbotson KJ, Harrod J, Gowen M, D'Souza S, Winkler ME, Derynck R, et al: Human recombinant transforming growth factor-alpha stimulates bone resorption and inhibits formation in vitro. *Proc Natl Acad Sci USA* 1986; 83: 2228-2232.

19. Van Rensburg BG and Jansen. *Oral Biology*. 1st ed. Chicago, Quintessence Publishing Co, Inc. 1995; 247-261.

20. Snead ML, Luo W, Hsu DD, Melrose RJ, Lau EC and Stenman G. Human ameloblastoma tumors express the amelogenin gene. *Oral Surg Oral Med Oral Pathol* 1992; 74:64-72.