

# TISSUE EXPANSION: A NEW MODALITY FOR EYELID RECONSTRUCTIVE SURGERY

M.S. Farahvash

Departement of Ophthalmology, Retina Service, Farabi Eye Hospital, School of Medicine, Tehran University of Medical Sciences, Tehran, Iran

*Abstract* — For the first time we have used eyelid skin expansion to facilitate reconstruction of selected patients with shortage of lid skin (e.g. for burn scar and after excision of tumors). This method allows for a controlled increase in skin, need for reconstruction, and offers many advantages over grafted skin transferred from a distance. Color, texture, thinness, delicacy and adnexal structures are aesthetically and functionally better matched. We used expanders in four patients with eyelid skin shortage to prepare suitable flaps for reconstruction successfully. *Acta Medica Iranica* 35 (3 & 4): 82-86; 1997

*Key words:* Tissue expansion, eyelid reconstructive surgery, reconstructive surgery

## INTRODUCTION

During the past decade, tissue expansion has become a valuable technique in reconstructing a wide variety of soft tissue defects. Radovan first popularized this technique for reconstruction of the breast (1). Soon it became apparent that other areas of the body could be reconstructed with expanded tissue, these included deformities of the head and neck.

The concept of tissue expansion was applied clinically in a case of ear reconstruction by Neumann (2). Controlled skin expansion is a new clinical technique of providing localized donor tissue for reconstructive surgery. Historically the reconstruction of soft tissue defects have necessitated use of skin graft and flaps. Tissue expansion naturally occurs in lactating breast and abdominal wall as the gravid uterus enlarges, or the expansion of skin overlying large benign tumors. The surface area of skin is increased after expansion. In one study, on histologic changes of guinea pig skin, after controlled expansion, it has been found a significant thinning of the dermis and no difference in epidermal thickness (3,4,5).

Vascularity of expanded skin is increased, but the actual mechanism of this condition is not known. Studies done by Barnhill and Ryan (6) showed that mechanical forces might have some effects on new vessel formation. The expanders are gradually inflated by injection of sterilized isotonic saline (7,8).

## MATERIALS AND METHODS

We have utilized this new approach in the last 2.5 years in six patients with eyelid skin shortage. Two patients excluded from the study because of infection during expansion. All of the patients were male. The youngest patient was eighteen and the oldest was forty-two years (mean 27.7 years) old.

As there was no suitable expander in Iran, we designed a relatively inert plastic ballon, its inflating tube was out of incision and not covered by skin. In two patients the expander was inserted in lateral canthal region and in one over inferior orbital rim. In one patient with complete loss of eyelid skin due to severe burn, we expanded retroauricular skin in one side. The average time for flap development was 12 days. After full expansion the flaps were used to cover the defect.

### Operation Technique

We made expanders in various sizes and shapes. We chose the base of the expander the same diameter as the defect for reconstruction. The incision should be small, far from expansion area and perpendicular to the direction of expansion in order to minimize tension on the incision (Fig. 1). The dissection of the canal and pocket is over the muscle facia and it is best developed by blunt dissection. This method of dissecting preserves the longitudinal blood supply which is vulnerable to sharp dissection. The dissected pocket should be wider than the base of the expander. The expander may be placed empty or with a small amount of normal saline. Initially unnecessary pressure on the flap should be avoided (9,10,11).

the expander is folded for easy insertion through the small incision and is then placed with the base flat in the pocket. Normal saline injections are performed at appropriate intervals for the particular flap being developed. The average interval of expansion varies with different areas and size of defect. In our patients this was twelve days. We begin injection of saline the day after insertion of expander and continue it until the skin becomes tight. If pale discoloration of the skin is observed, the fluid may be withdrawn to prevent possible

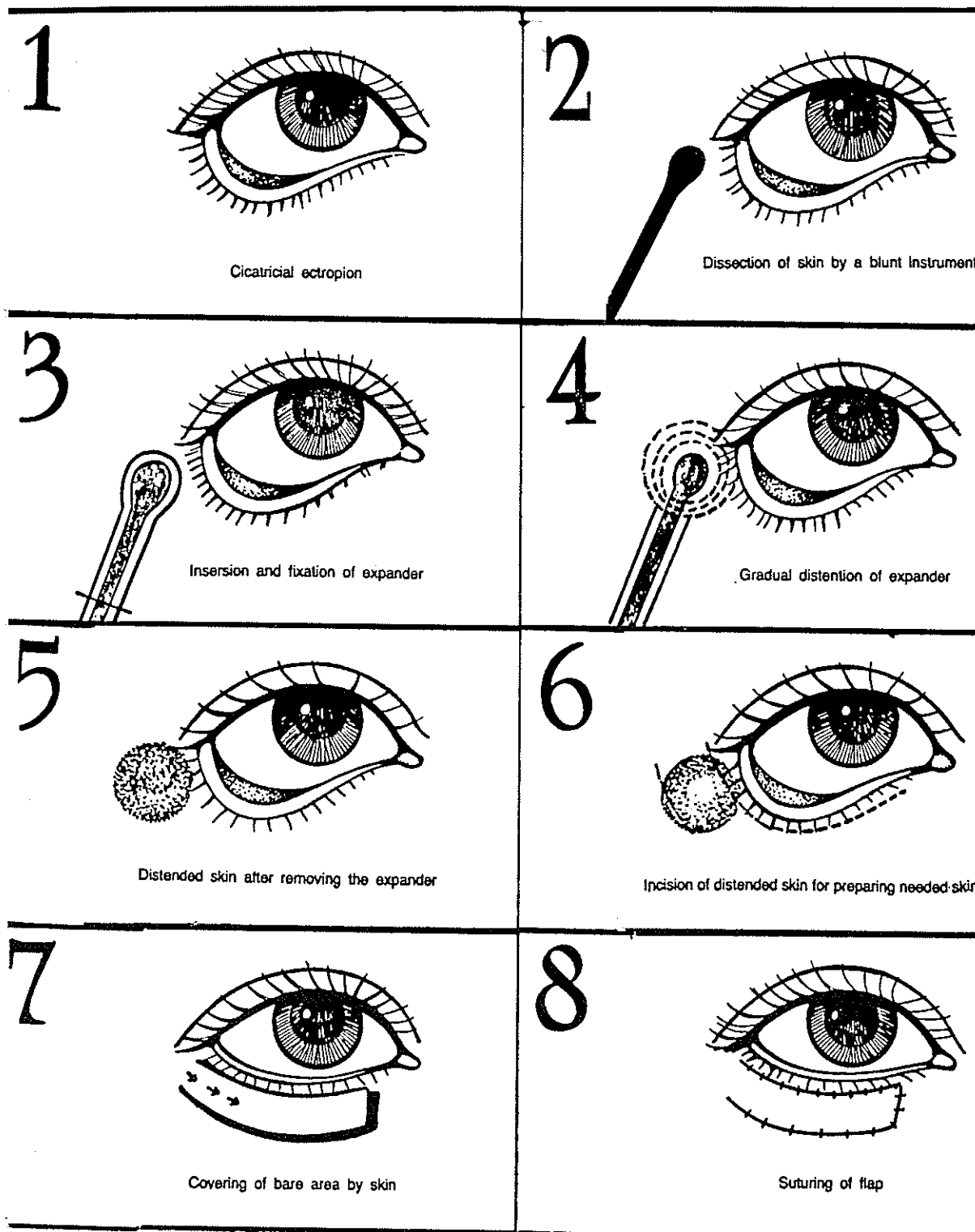


Fig. 1. Schematic presentation of tissue expansion.

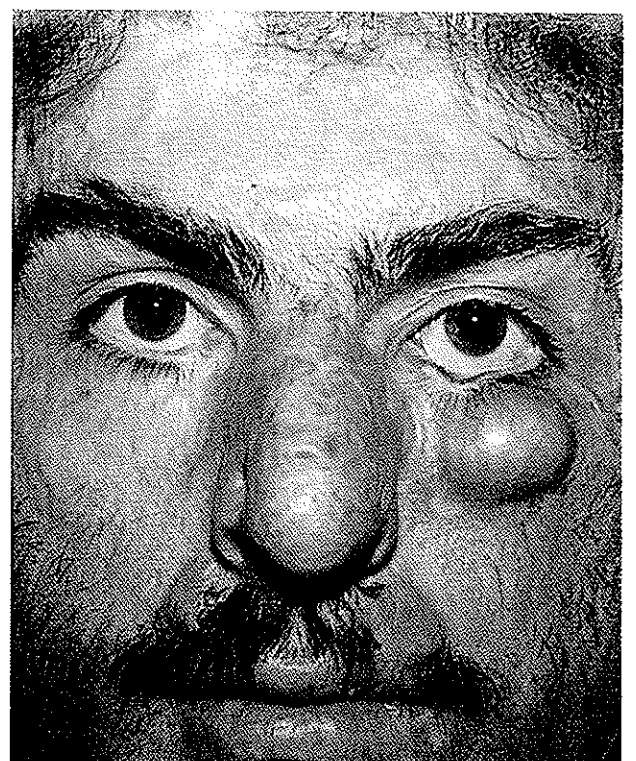
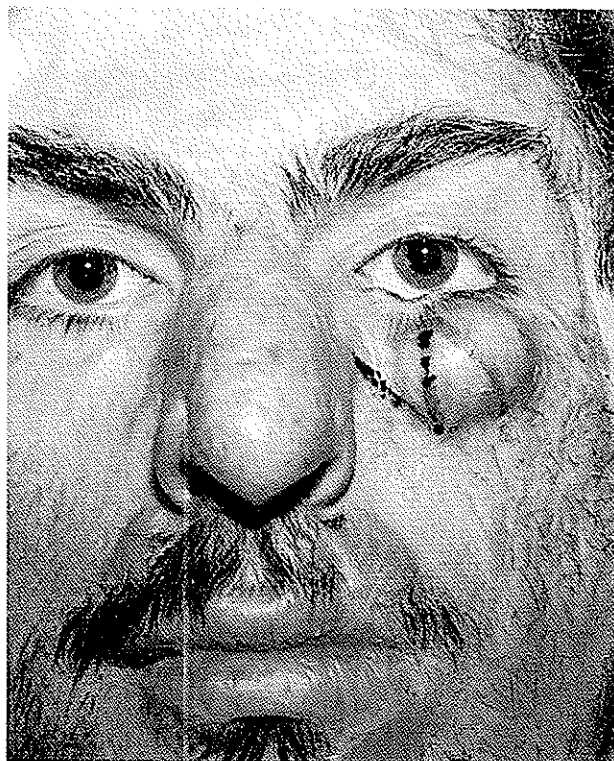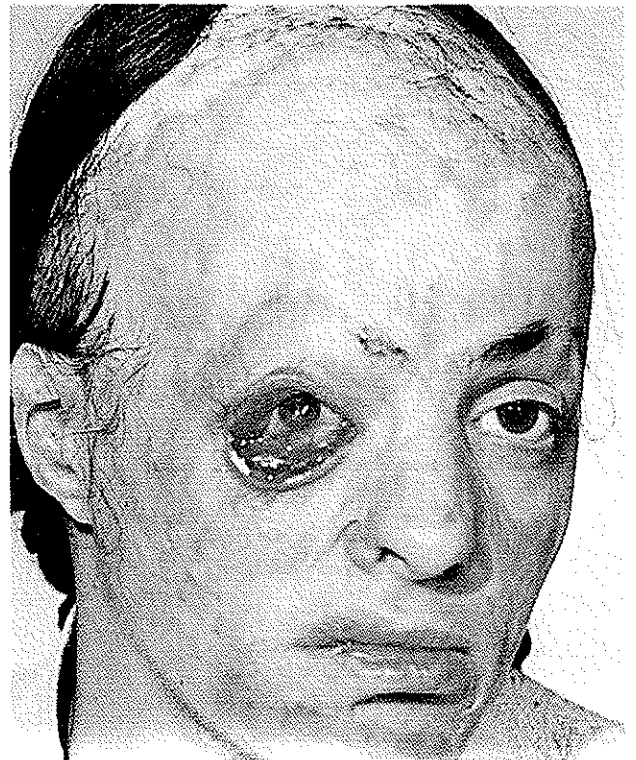

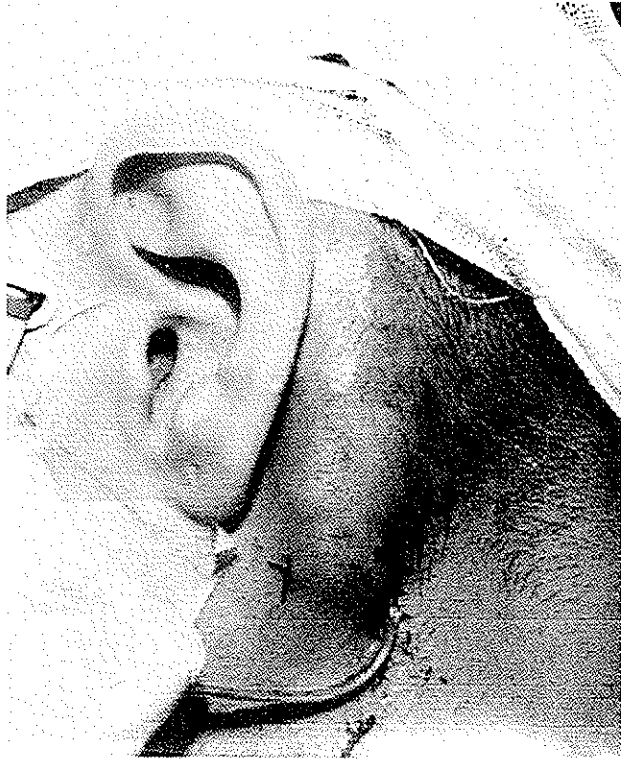
Fig. 2. Patients photographs before surgery

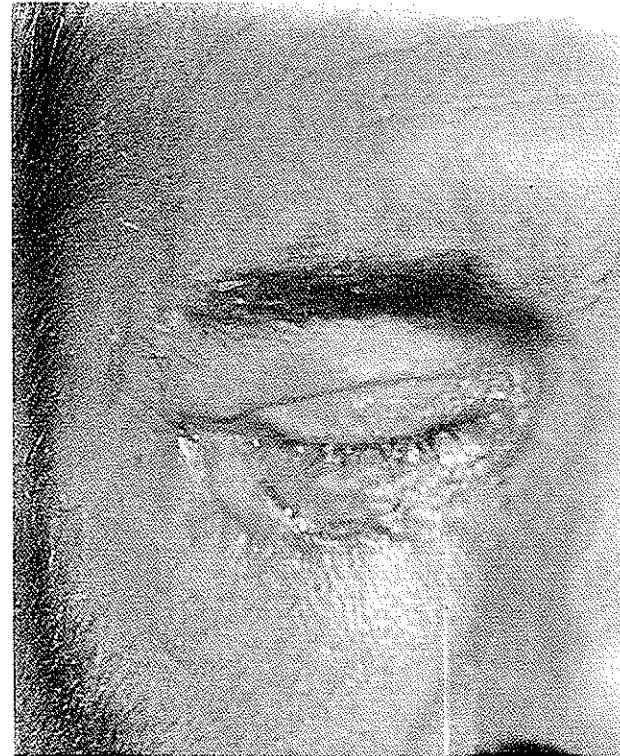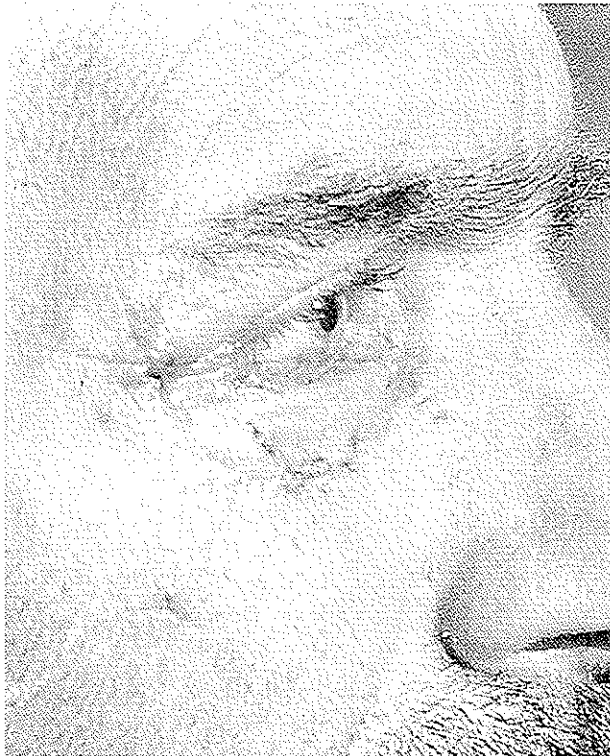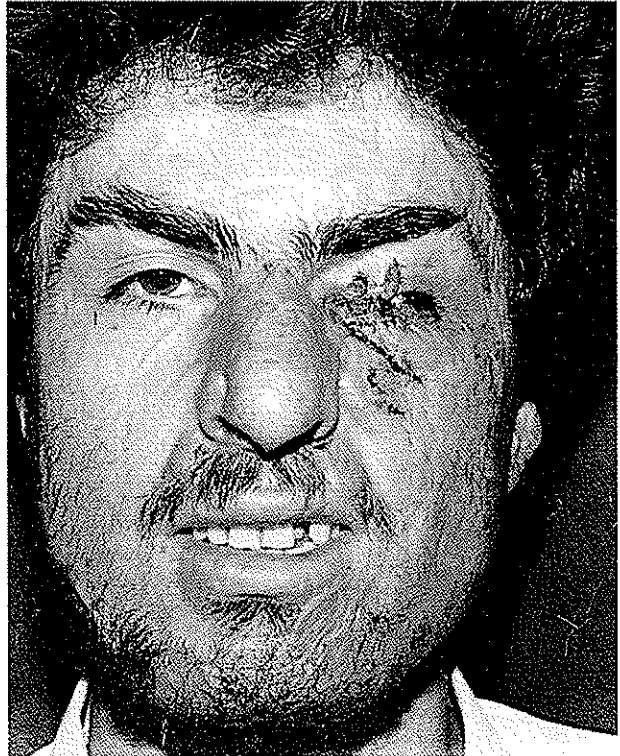


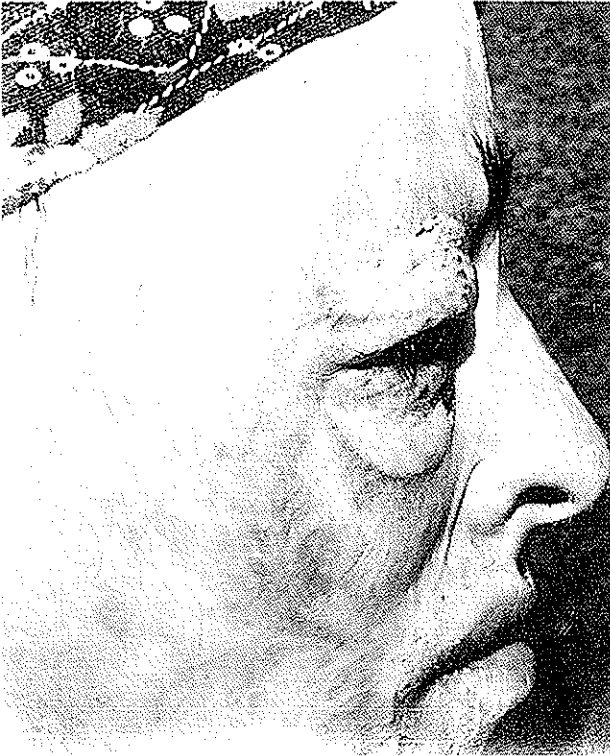Fig. 3. Patients' photographs after operation

necrosis. We continue injection successfully until adequate skin be prepared (12,13,14).

## RESULTS

Two patients excluded from the study because of the infection during expansion. In other four cases, acceptable reconstructive, functional and cosmetic results obtained (Fig. 2). The complication of tissue expansion method may be minor (pain on expansion, and seroma) or major (infection, expander exposure and necrosis) (15). Tissue expansion complications is shown in Table 1.

## DISCUSSION

Results of the study shows that tissue expansion seems to be a valuable technique in selected patients with shortage of lid skin. In this method, color, texture thinness, delicacy and adneral structures of the grafted tissue are better matched. It seems that by using the standard and inert ballons for expansion, the complications become lower.

**Table 1. Complications**

| Complications  | numbers of patients (6) |
|--|-------------------------|
| Pain on expansion                                      | 3                       |
| Seroma   | 0                       |
| Infection  | 2                       |
| Expander exposure                                      | 0                       |
| Necrosis of the distal part of the flap after rotation | 0                       |

## REFERENCES

1. Radovan, C: Tissue expansion in soft tissue reconstruction. *Plast. Reconstr. Surg.* 74: 482; 1984.
2. Neumann, C.G. : The expansion of an area of skin by progressive distention of a subcutaneous balloon. *Plast. Reconstr. Surg.* 19: 124; 1975.
3. Austad, E.D. Pasyk K.A. McClatchey, K.D. and cherry C.W. Histomorphologic evaluation of guinea pig skin and soft tissue after controlled tissue expansion. *plast. Reconstr. Surg.* 70: 704; 1982.
4. Cherry G.W. Austad E. et al. Increased survival and vascularity of random pattern skin flaps elevated in controlled, Expanded skin. *plast. Reconstr. Surg.* 72: 680-685; 1983.
5. Pasyk, K.A., Austad, E.D., MC clatchey, K.D., and cherry, G.W. Electron Microscopic evaluation of guinea pig skin and soft tissues expanded with a self - inflating silicone implant. *plast. Reconstr. Surg.* 70: 37; 1982.
6. Barnhill R. and Ryan T.J. mechanical considerations in new vessel growth. In *Basic Aspects of Microcirculation.* Amsterdam: Excerpta Medica; 1982.
7. Pasyk, K.A., Angenta, C.C., and Austad, E. : Histopathology of human expanded tissue. *Clin. Plast. Surg.* 15: 435; 01987.
8. Sasaki G.H., and pang, C.Y. pathophysiology, of skin flaps raised on expanded skin. *plast. Reconstr. Surg.* 74: 591; 1984.
9. Argenta, L.C.: controlled tissue expansion in reconstructive surgery. *Br. J. plast. Surg.* 37: 520-525; 1984.
10. Argenta, L.C.I Marks, M.W., and Pasyk, K.A. : Advances in tissue expansion. *Clin. Plast. Surg.* 12: 159-160; 1985.
11. Argenta, L.C., watanabe, M.J., and Grabb, W.C.: The use of tissue expansion in head and neck Reconstruction. *Ann. Plast Surg.* 11: 31-35; 1983.
12. Brobmann, G.F., and Huber, J. Effects of different shaped tissue expanders on transmural pressure. Oxygenation, histopathologic changes, and skin expansion in pigs. *plast. reconstr. surg.* 76: 731-733; 1985.
13. Cohen, I.: Silicone expander with self - contained valve *plast Reconstr. Surg.* 75: 279-280; 1985.
14. Manders, E.K, shcendern, M.J., Furrey, J.A., Heizler, P.T., Davis, T.S., and Graham, W.P., III soft tissue expansion concepts and complications. *plast. Reconstr. Surg.* 74: 493-495; 1984.
15. Austad, ED. : Complications in Tissue expansion. *Clin. Plast. Surg.* 14: 549-555; 1987.