

SPOROTRICHOSIS IN IRAN: FIRST REPORT OF ISOLATION OF
SPOROTHRIX SCHENKII FROM CLINICAL MATERIAL.

Farideh Zaini

This paper reports for the first time the isolation of *Sporothrix schenkii* from a woman in Tehran, Iran. Literature reviews on subcutaneous mycosis in Iran (1, unpublished) do not reveal any well documented case of sporotrichosis in man. Moreover, no comprehensive investigation has been undertaken on the natural reservoirs of *S. schenkii* and other dimorphic pathogenic fungi in this country.

Department of Mycology and Parasitology, School of Public Health and Institute of Public Health Research, University of Teheran, Teheran 14, Iran.

Case Report

A 36 year old female housewife was admitted to the Medical Mycology Laboratory of School of Public Health and Institute of Public Health Research on June 1983 with chronic subcutaneous lesions on right arm. The patient gave a history of some small nodules like an insect bite at the beginning of symptoms. The nodules were broken down, ulcerated later and discharged pus. Those subcutaneous lesions were surgically removed twice within a period of eight months and then lesions were diagnosed as leishmaniasis and treated with Glucantim without any relief (Fig.1).

She was otherwise in good physical condition and had no remarkable past history.

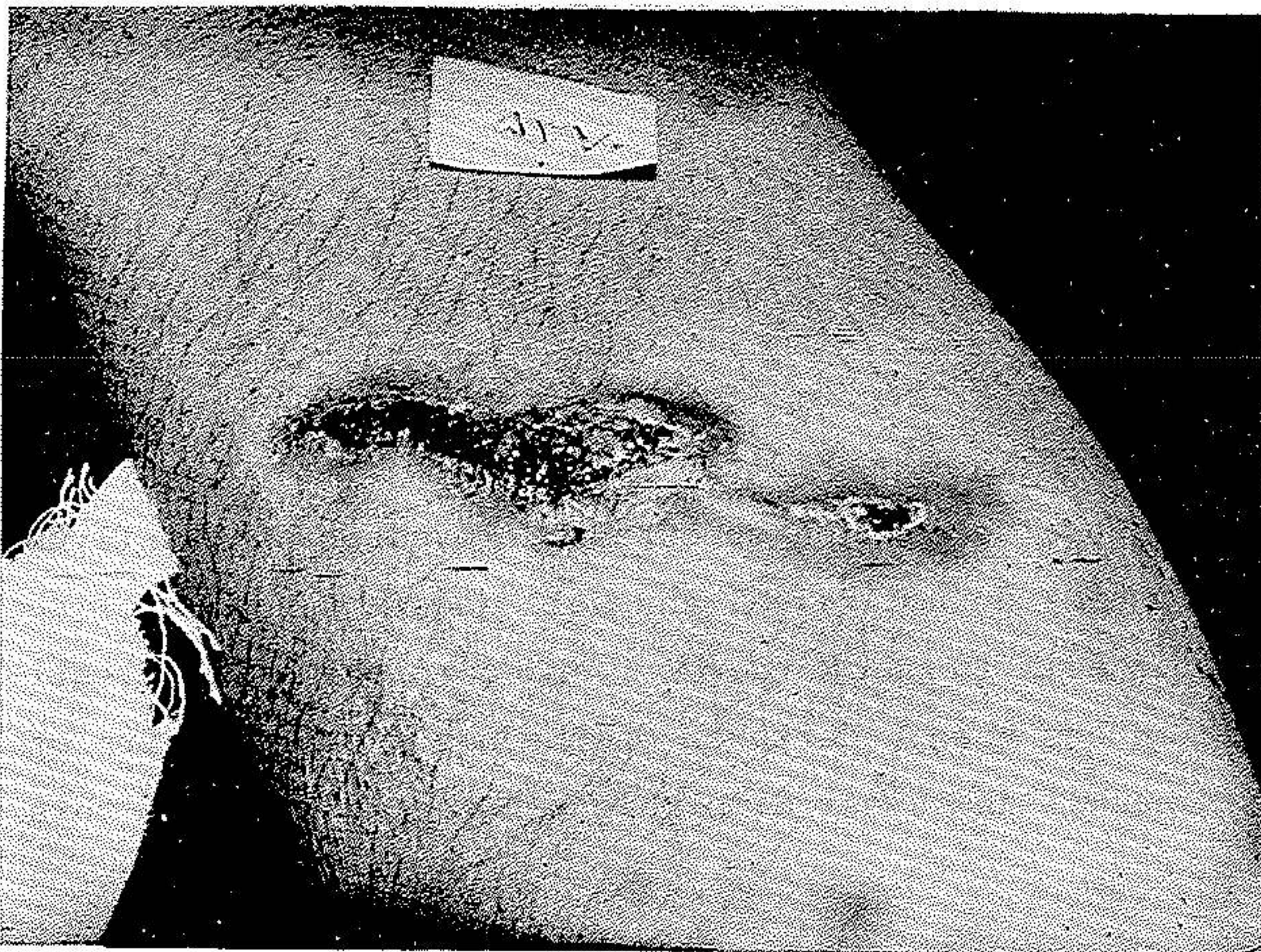

Figure 1. Subcutaneous sporotrichosis of arm. The lesion was diagnosed initially as leishmaniasis.

Laboratory data

The exudates and pus were aspirated from subcutaneous lesions and was examined directly and inoculated on Sabouraud's dextrose agar(S), Sabouraud's dextrose agar containing Chloramphenicol(0.05 mg ml^{-1}) and Cycloheximide (0.5 mg ml^{-1}) (SCC), Blood agar(BA), Brain Heart Infusion agar(BHI) and incubated at 26°C and 37°C .

Result

Direct examination of potassium hydroxide preparation was negative for fungal elements, therefore the identity of the fungus based on its gross and microscopic cultural morphology including demonstration of its dimorphic character(2).

Fungal growth was examined after 15 days. Mycelial form culture(26°C) on S, SCC, BHI and BA characteristically had a wrinkled membranous surface which at first was whitish in colour but in time became brownish to black (Fig. 2).

Microscopic examination of mycelial form was characterized by the delicate (12μ in diameter), branched, septate, hyaline mycelium and numerous conidia which were produced in abundance on delicate strigata along the hyphae and terminally on conidiophores(Fig.3).

Yeast-form(37°C) colonies were moist, creamy and whitish in colour.

Microscopic examination revealed single and budding

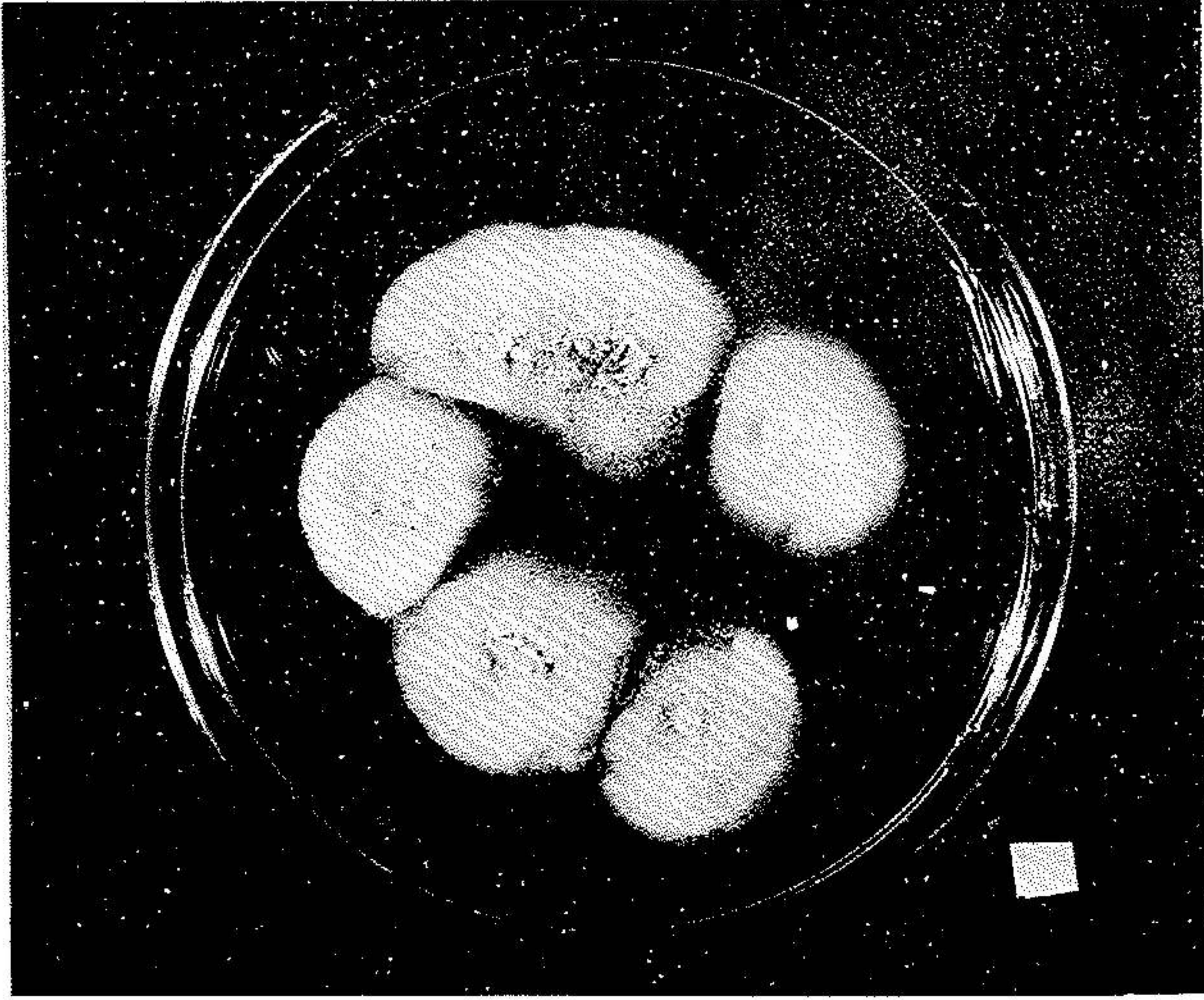


Figure 2. The initial isolant of *S. schenckii* from a case of subcutaneous sporotrichosis after 15 days of incubation at 26^o c.

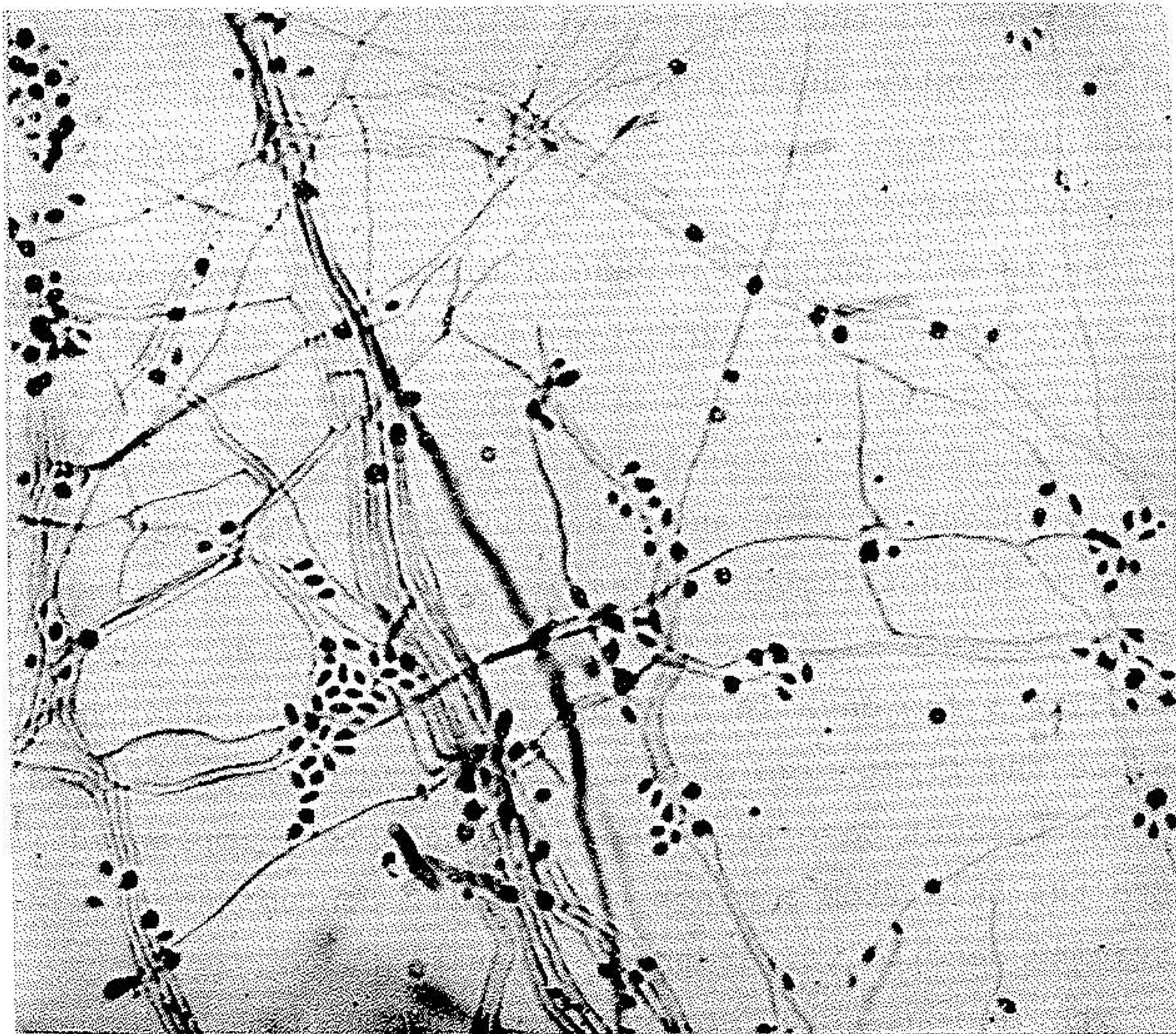


Figure 3. *S.schenckii*. Twisted mycelial strands bearing delicate conidiophores and conidia at 26°c X 450.

yeast-like cells vary in size and form.

Discussion

The first case of *S.schenckii* infection was particularly notable in a housewife in Iran, which shows the presence of this fungus in our environment.

Because of the climate and geographical condition in this country there are varieties of cutaneous, subcutaneous and fungal disease but still there is no report on sporotrichosis.

As is well known, *S.schenkii* grows as a saprophyte in environment. It is suggesting that people especially farmers and gardeners are probably exposed to this fungus in nature. It is found in soil, on plants and on a variety of plant debris and plant materials. Although this patient did not remember clearly the circumstances under which the infection had been acquired, but she did mention spending a few days in a garden out of Teheran a month before the first sign of the disease was occurred. Perhaps in the present case the fungus may have been implanted into the skin from a minor trauma with contaminated cultivating decorative garden or house plants.

The lesions were remained active for a long time even after surgical remove because the infection was not diagnosed, so failure to correct treatment of the infection gave results in a chronic manifestation.

This case prompted us to initiate an investigation in distribution of this fungus and dimorphic fungi in Iran to find out the incidence of the sporotrichosis or the presence of the probable other fungal infection caused by dimorphic fungi.

Summary

The isolation of *Sporothrix Schenckii* in IRAN is reported from the arm lesions of a housewife for the first time. The identity of the fungus was based on its

gross and microscopic cultural morphology including demonstration of its dimorphic character.

Résumé

Dans cet article, pour la première fois en Iran, on rend compte l'isolement d'un cas de sporotrichose sous-cutane apparue sur le bras d'une ménagère. Cette sporotrichose démontre par la culture des prélèvements cliniques.

Jusqu'à présent, aucun cas de cette maladie n'a été signalé en Iran, mais il n'y a pas de renseignements étendus à propos des maladies provoquées par des champignons dimorphiques dans ce pays.

REFERENCES

1. Asgari M., Alilou M., (1972). Mycetoma in Iran. The first report of eight cases with mycological studies. Ann. Soc. Med. Trop. 52, 287-305.
2. Campbell, M.C., Stewart, J.L. (1980). The Medical Mycology Handbook. P. 120-121. John Wiley & Sons, Inc., United States of America.

Acknowledgement

The author wishes to thank Miss. Khoshghadam Ommidi for technical assistance.