

Cutaneous Horn

A report of a very rare and exceptional Case.

ABDOLHAMID M. HESSABI M.D.

Cutaneous Horn is one of the rare cases in Medical Literature, particularly, when the horn has grown too large. The following case is one the rare, if not unique case reported.

Case Report

Mrs. E.O. fifty years old was born in Teheran Suburb (Capital of Iran). She is referred to our out-patient clinic on 3, 3, 1984 because of a horn-like mass on her head. During the examination the horn was so large and interesting that it amazed me for a few seconds. The Patient history revealed that she had the horn for fifteen years, but the growth was faster in the recent years. The patient stated that five years ago, when the horn was much smaller

than today, it was broken by her husband; despite her refusal her husband held her head between his legs and broke the horn from its root by exerting much pressure, in as much as the patient fainted from the severe pain, that followed by bleeding. But she failed to refer to a hospital or a physician, and the wound gradually healed by dressing at home. It began to grow again after a few months, but it grew faster and has become so large during the last five years.

The patient knows nothing about her past history and any local diseases prior to the growth of the horn. During the clinical Examination I revealed that the horn has a length of 32 Cms, with a brown colour, grown on the parietal bone, and after forward projection, it has turned 360 degrees around itself (Fig. 1,2); the base being hy-

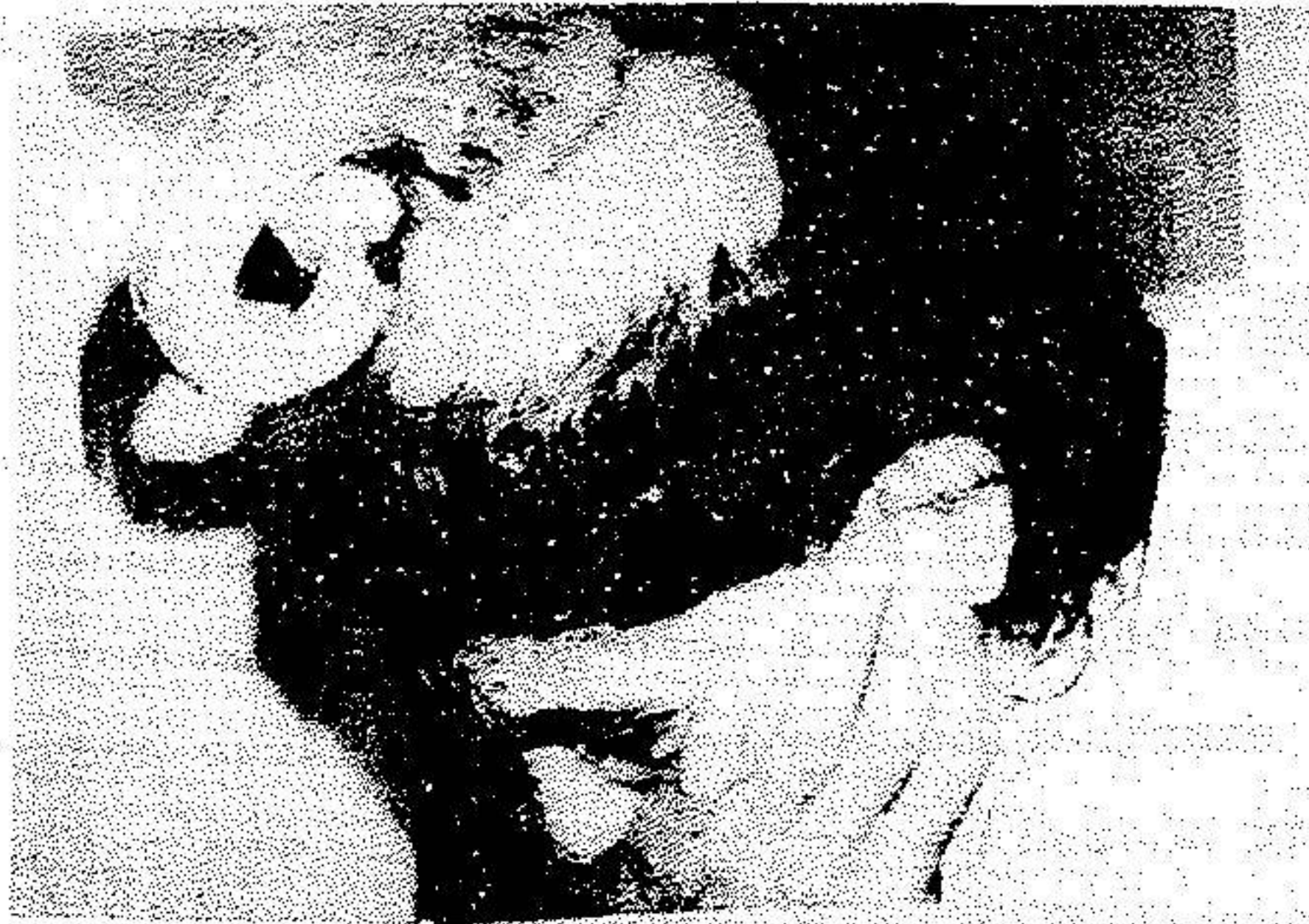


Fig.1

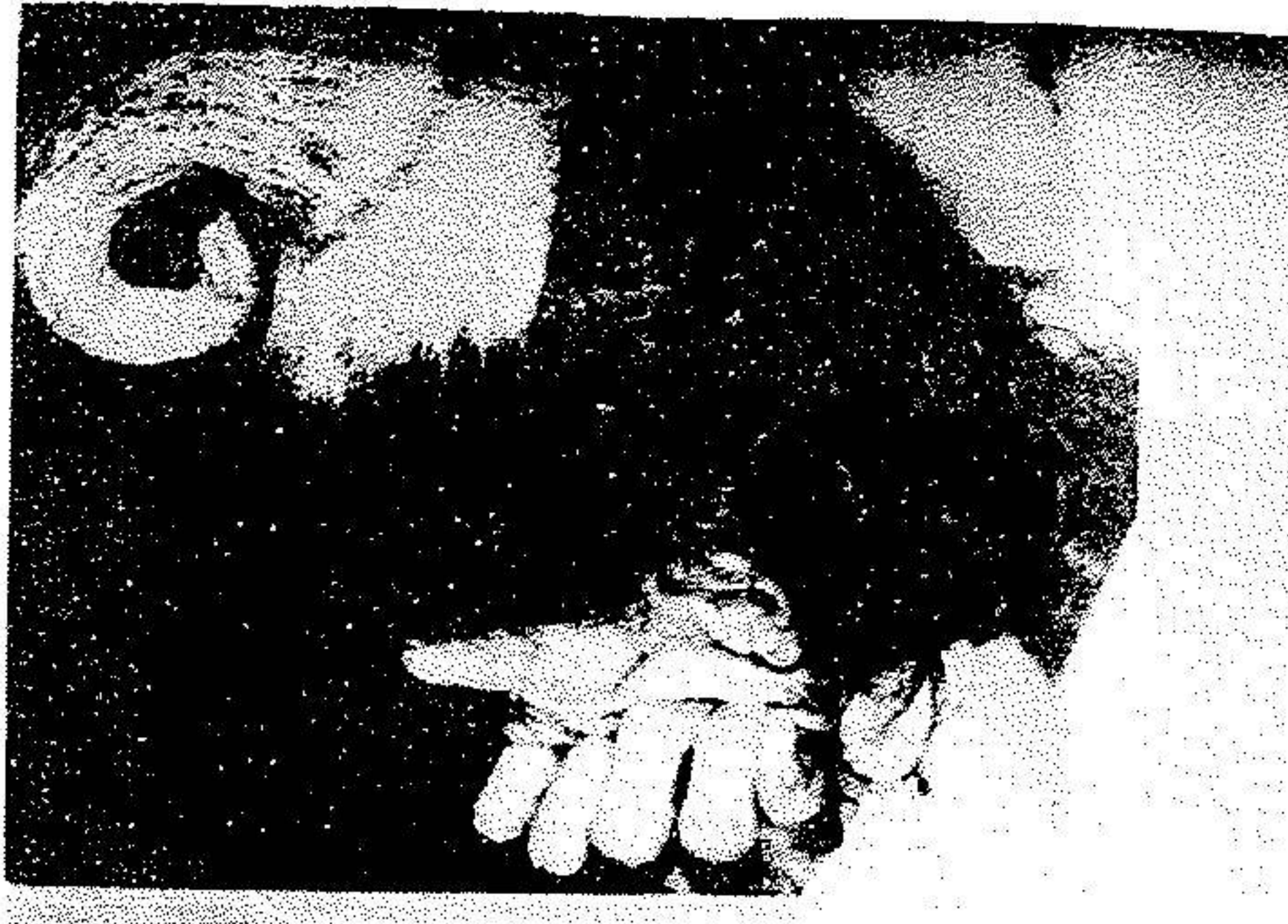

Fig.2

perkeratotic with a distance of 3-4 mms. The patient was hospitalized for surgery to remove the horn. General check-up showed that all her organs were normal, and there was no problem with respect to the blood and urine tests. X Ray examination shows the horn with a faint colour on the face (Fig.3) and the lateral view (Fig. 4)

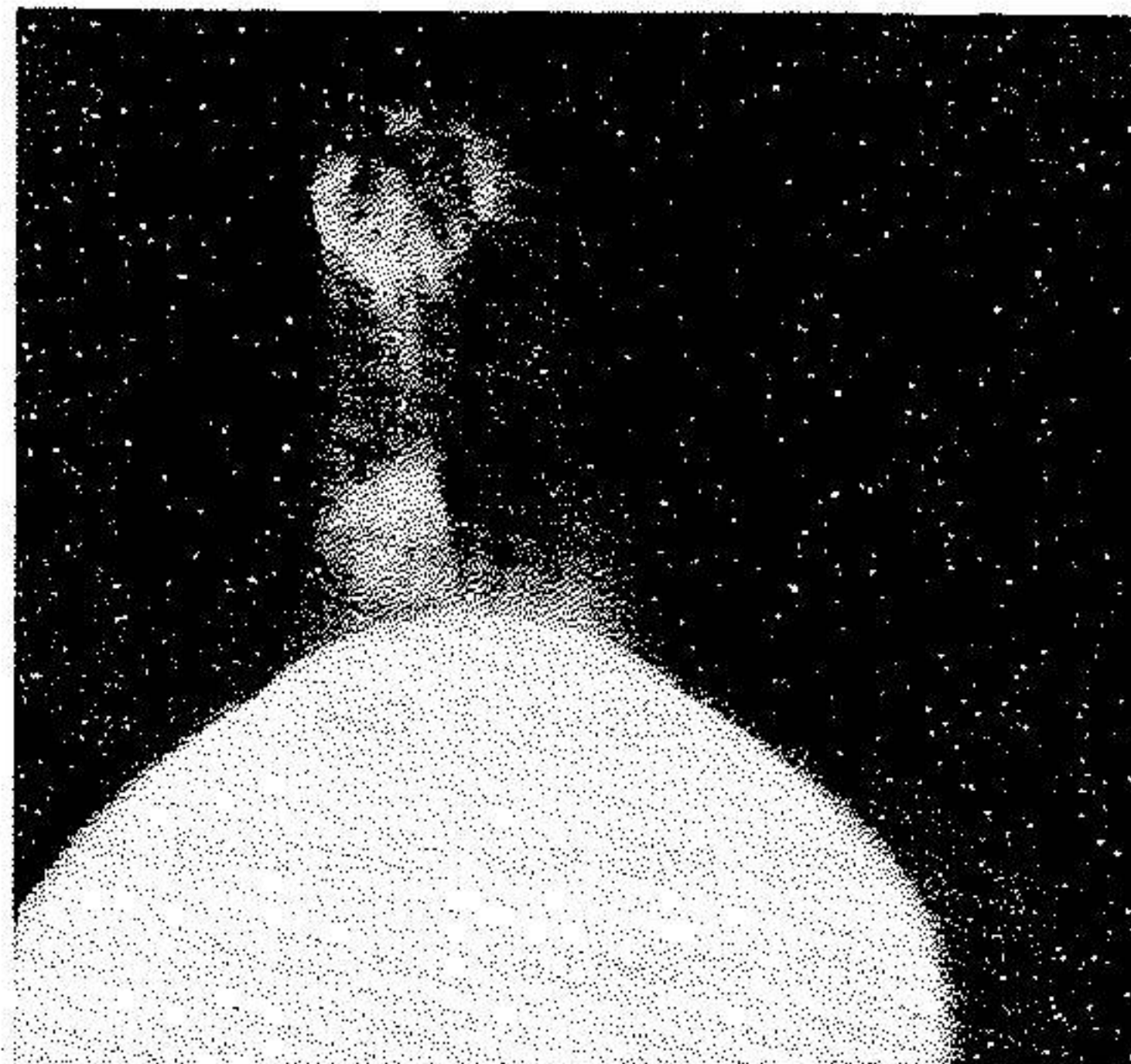

Fig.3

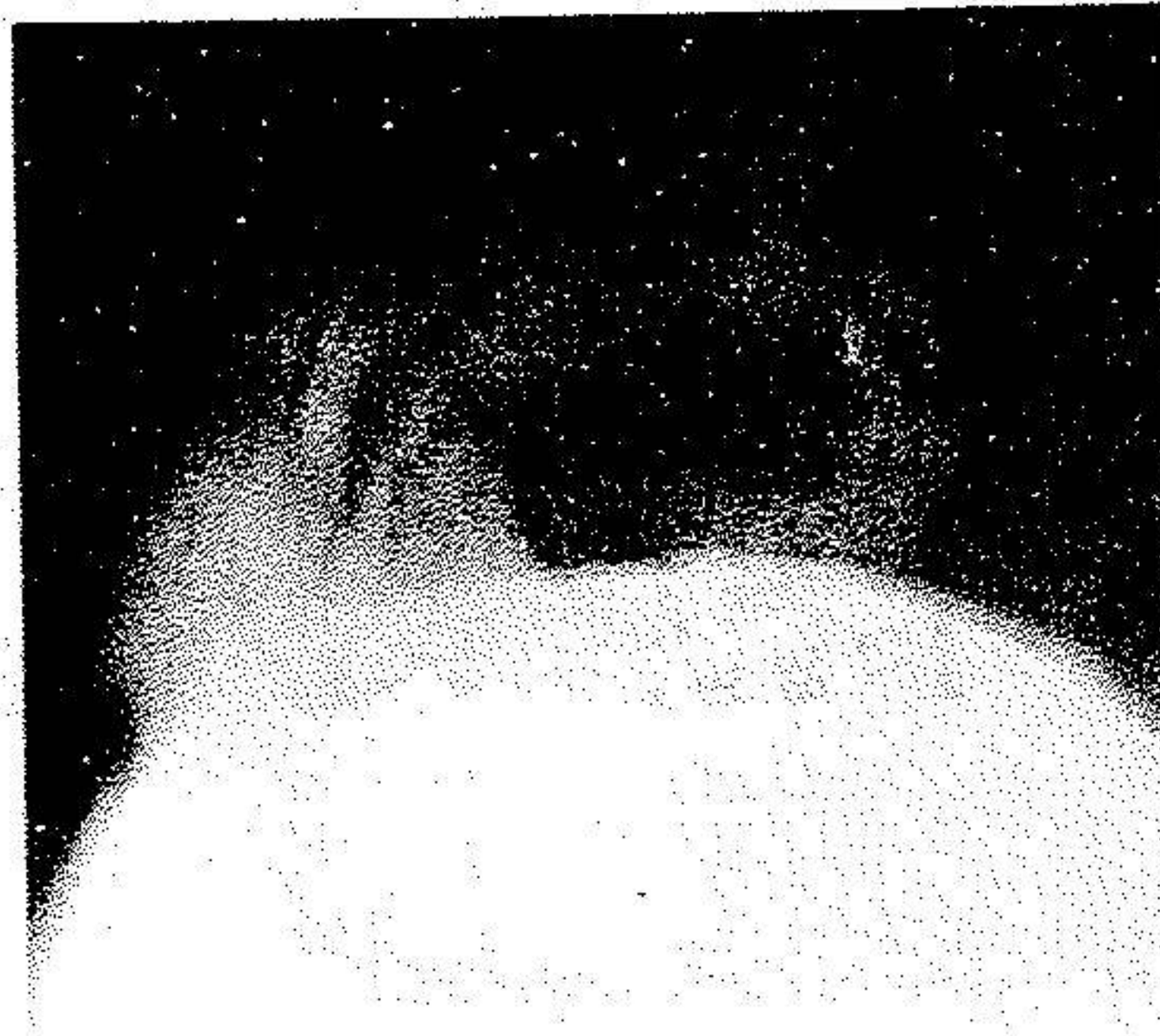


Fig.4

Operation.

The patient was operated on 5,3, 1984. All around the horn with all tissues up to two centimeters were removed. Which are as following:

- 1- The length of the horn from bottom to the top is 32 Cms. (Fig. 5)
- 2- Base circumference Is 17 Cms. (Fig. 6)
- 3- Base Diameter 5 Cms. (Fig. 7)
- 4- Top circunference 7 Cms (Fig. 8)
- 5- The top Diameter is about 1 Cms.

Three weeks later she was operated for the skin gra-
ft, and she left the hospital on 23,4, 1984.

A piece of the base of the horn was taken for the patho-
lpgical Exam. and the result is as follow.

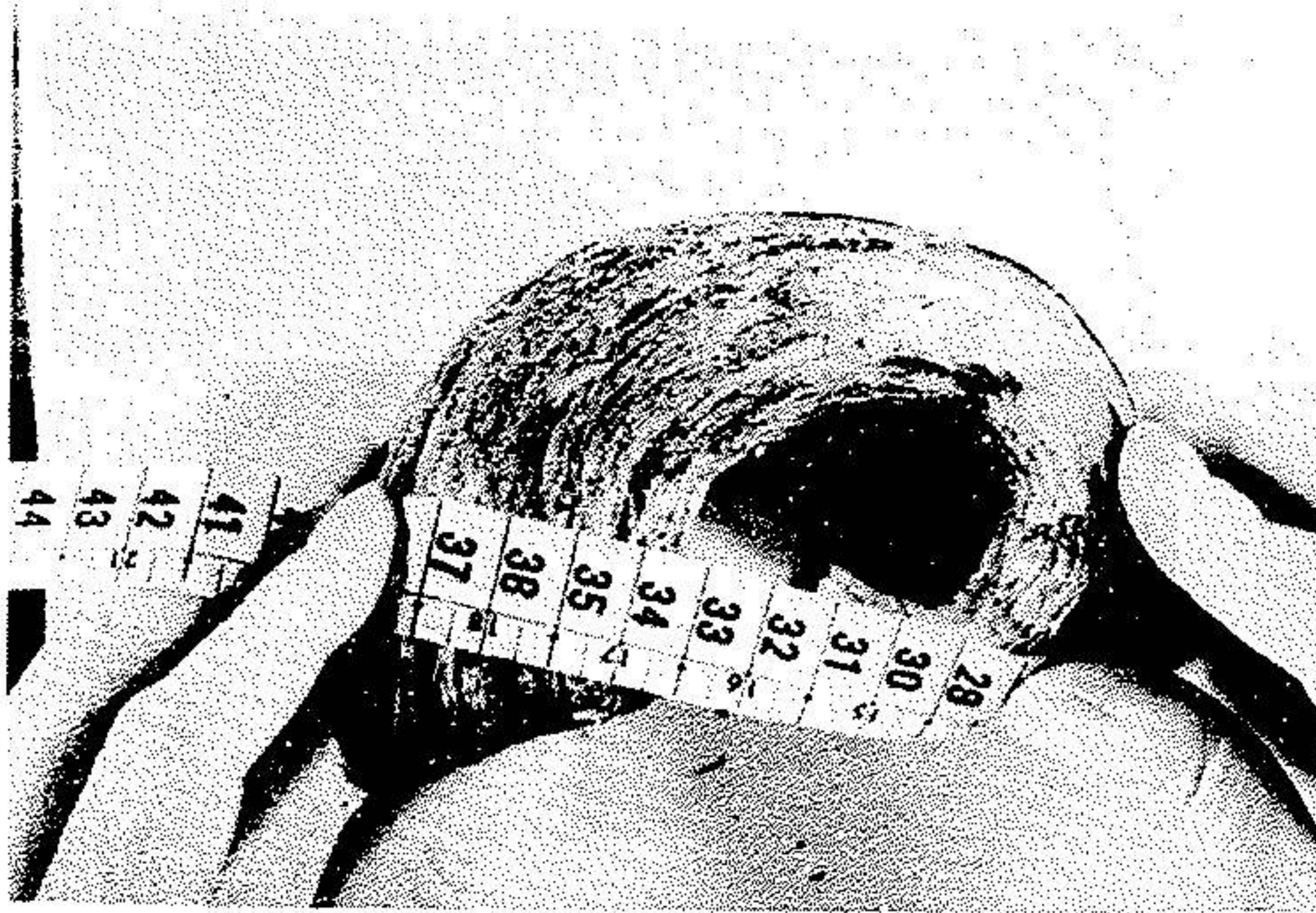


Fig.5

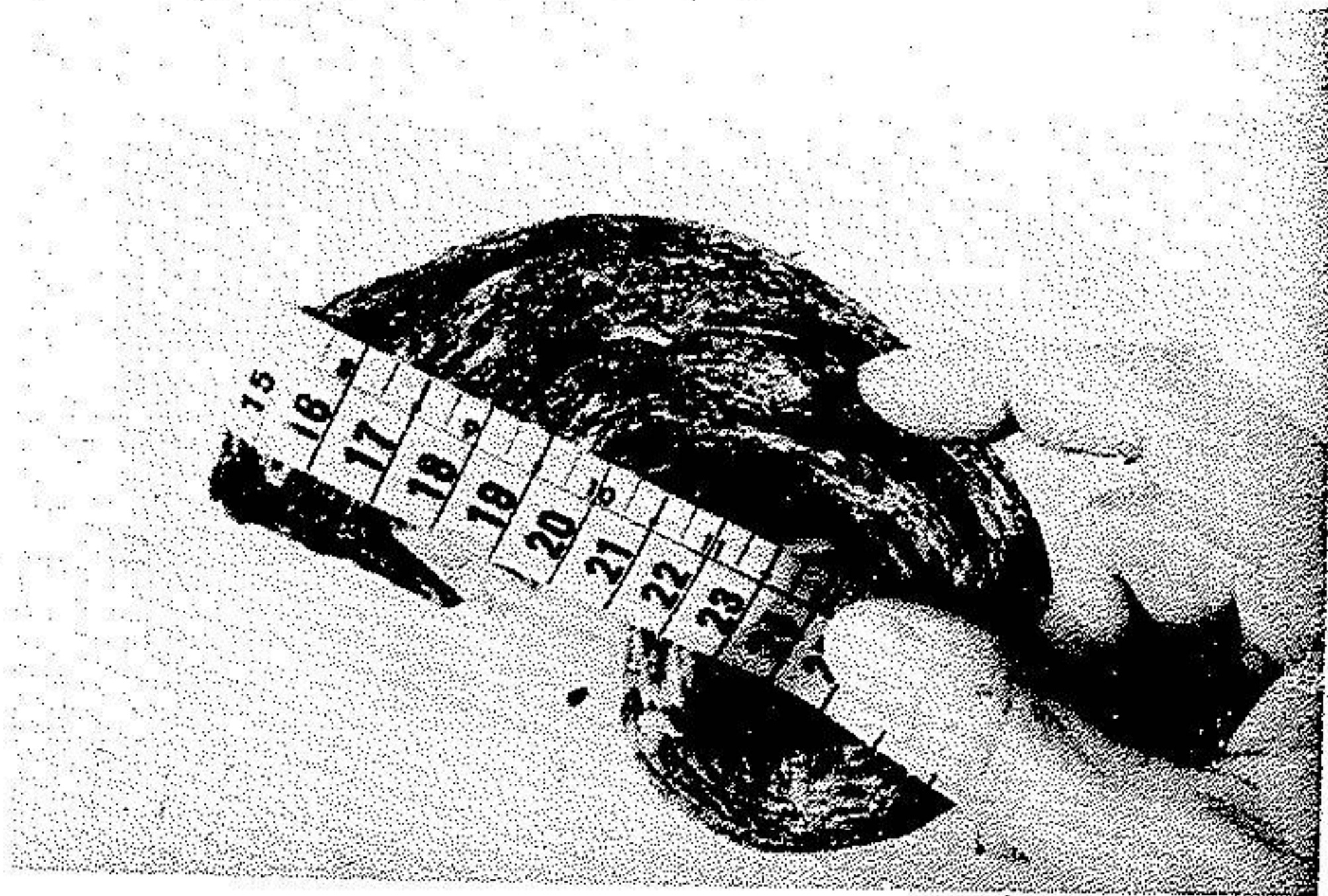
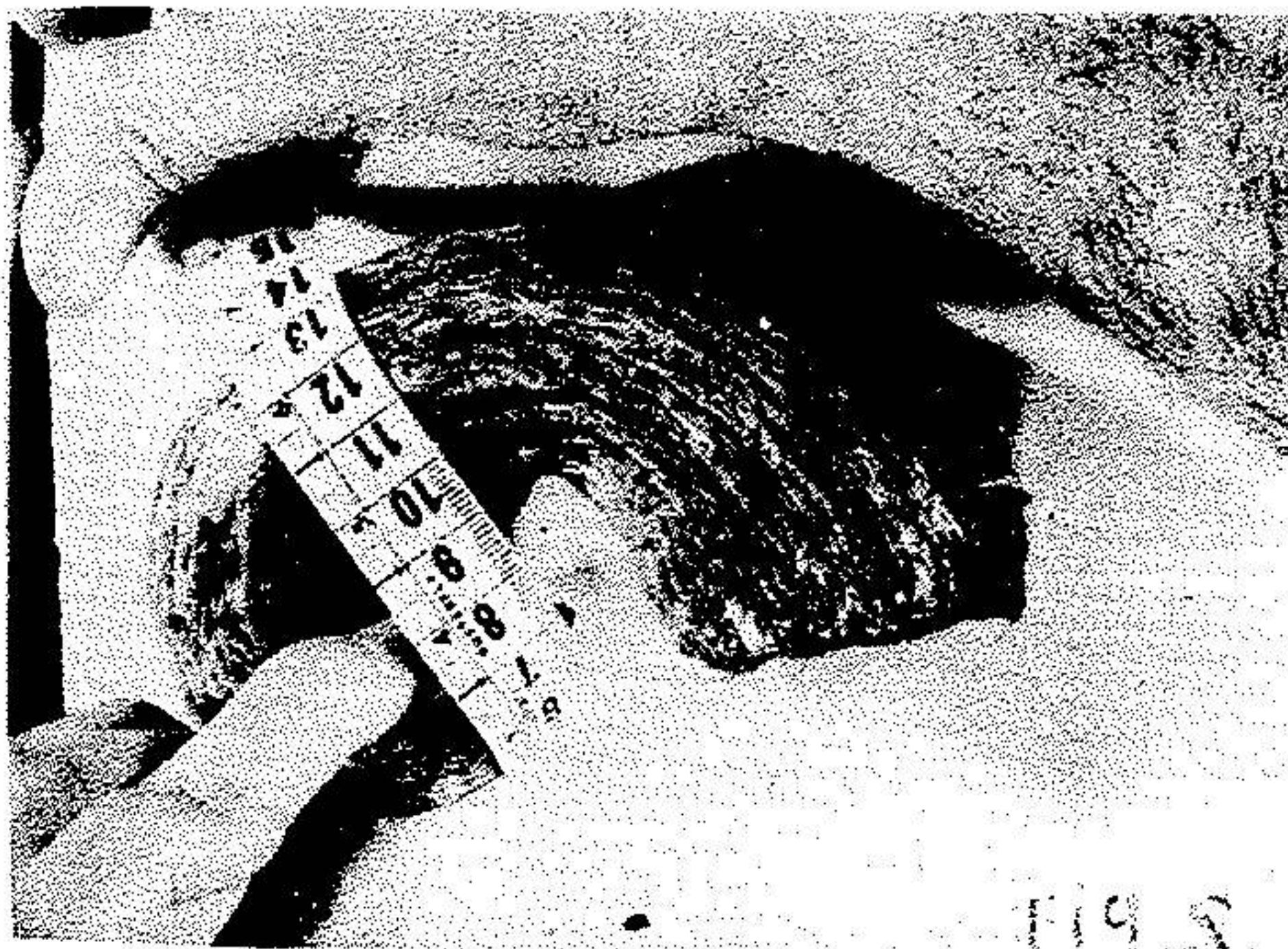
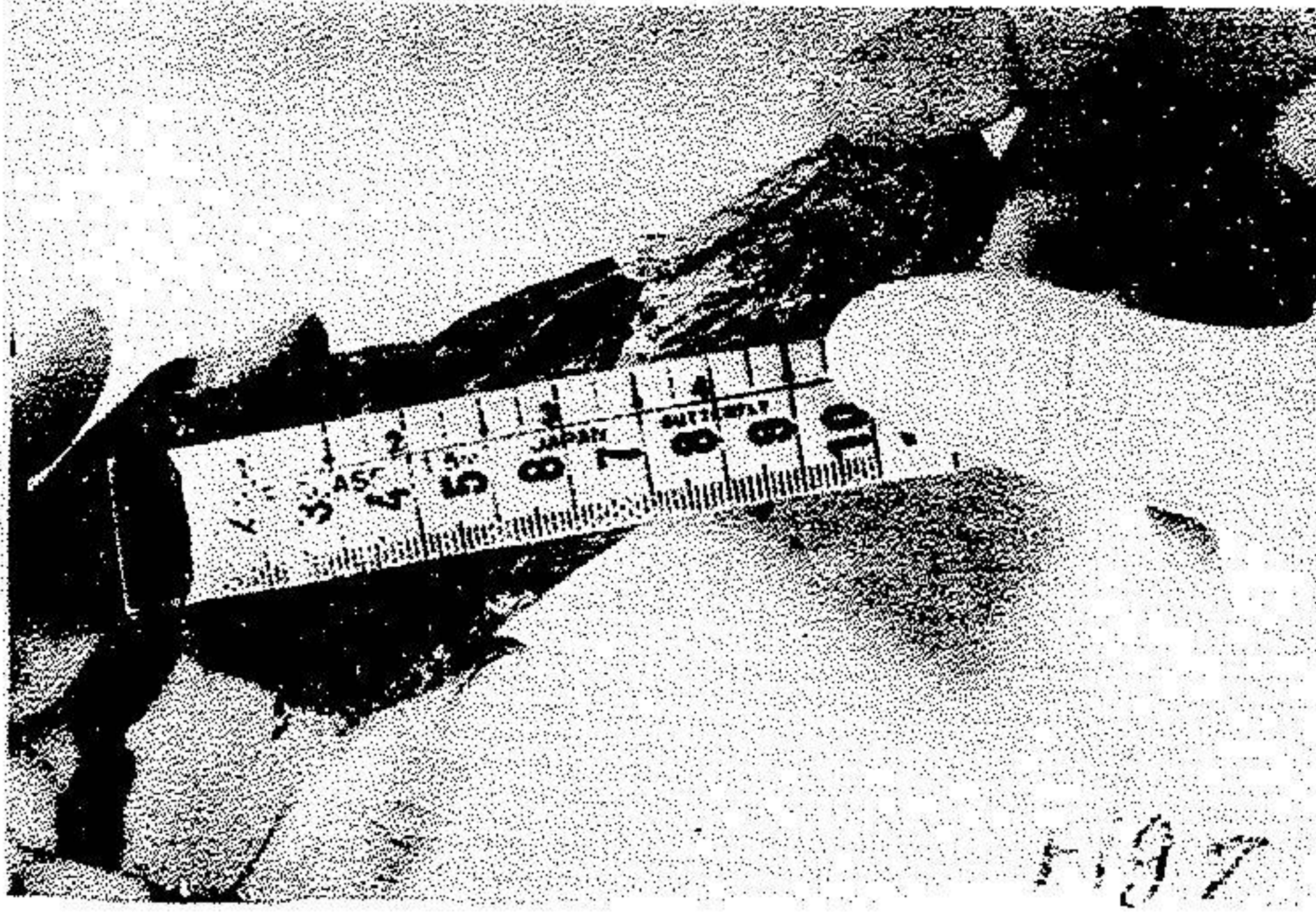


Fig.6



Pathology Report:Gross Appearances :

The specimen consists of a pyramidal shape of fibro-cartilaginous tissue measuring 5x3x2 Cms. The base consists of a brown colour soft tissue. Other part is white gray.

Histology

Section shows the histology of skin tissue featuring hyperkeratosis, acanthosis and papillomatosis. The dermis is infiltrated by inflammatory cells. No evidence of malignancy is seen.

Diag :

Histology is compatible with Cornu Cutaneum (Cutaneous Horn).

Discussion :

As stated earlier, Cutaneous Horn, particularly its large and long type is a rarity. The study of medical literature shows that cutaneous horns had a length between 1 to 6 Cms., the horns over this length (7 & 8 Cms.) is very rare. And the horns over 12 Cms. length are very exceptional.

The latest published report is from Milan, Italy(1) that is about a Lady with the Cutaneous Horn of 18 Cms. length and 2 Cms. Diameter, It started when she was 23 years old but the development was gradually and slow and had fast growth during the last 8 months(Fig. 9,10) and was removed when she was 60 years old whereas our patient, horn is 32 Cms. (Fig. 5)

Cause:

No decisive view could be expressed with regard to real causes of such horns. But there must be some factors which predispose one for affliction. In the light of the published cases, some of these factors are as below:

- 1- Growth of the horn on the ground of hyperkeratotic, Verruca Vulgaris (2), Nevus Verrucous (1)
- 2- Growth of the horn on a chronic infectious ground (Pyogenic granuloma simulating a Cutaneous Horn). (3)
- 3- Growth of the horn on a Metastatic renal-cell carcinoma presenting as a Cutaneous Horn (4).
- 4- Giant Cutaneous Horn developed at the expense of a total orbital skin graft, description of a case in which the patient developed Cutaneous Horn 12 years after orbital skin graft. The reporter believes that Post-surgery stimulations have resulted thereto. (5)
- 5- Cutaneous Horn on the ground of Tricholemmoma, with inverted follicular Keratosis with underlying tricholemmoma (6)
- 6- Growth of Cutaneous Horn on solitary nodular calcinosis of the skin (7).

Locality

Locality is quite variable; in a report on 18 cases of Cutaneous Horn, 9 grew on the limbs, 4 on the back, 3 on the scalp, and 2 on the face (8).

Age.

Age limits have been reported to be between 16 to 72 years, with 50 years as average (8). Duration of the disease in average is 2 years.

Therapy

Surgery is the solution, and the removal must be within two Cms. or more, all the indepth tissues and the skin should be removed so as to reduce probable recurrence. Then skin graft.

Summary

The patient who is introduced has developed cutaneous horn with the length of 32 Cms. which seems to be the longest horn ever reported in the literature.

Acknowledgement

I wish to tank Mr. Kazem Motabar MD who helped me for operation, and Sina hospital pathology Departement for preparation of the pathology report.

References

- 1) Alfisi-M. Gulienetti-R. Ferrante-A. Veneziani-A.
Buccanera -D. Polenski-M-M. Frrari-A.
Cutaneous Horn (Letter)
Plast-Reonstr-Surg. 1984 Jan. 73(1). P 158-9
- 2) Nakamura-K.
Two cases of trichilemmal-like horn.
Arch-Dermatol. 1984 Mar. 120(3) P. 336-7.
- 3) Findlay-R-F. Lapins-N-A.
Cutis. 1983 Jun. 31(6) P 610-2.
- 4) Peterson-J-L. Memarlin S-L.
J-Dermatol-Surg-Oncol. 1983 Oct.
9 (10) P. 815-8.
- 5) Zalog-N.
J-Fr-Ophtalmol-1982 5(II). P 717-20.

- 6) Garcia-e-Silva-L.
Med-Cutan-Iber-Lat-Am. 1982 10(I)
P. 27-30.
- 7) Kanitakis-C. Isoitis-G.
Ann-Dermatol Venereal 1978, Dec.
105 (12). P 1033-40.
- 8) Brownstein-M-H. Shapiro-E.F.
Clin-Exp-Dermatol. 1979 Mar.
4(I). P 59-63.