

CRANIOCEREBRAL MISSILE INJURY

A STATISTICAL REVIEW

ALI ALIMOHAMMADI, M.D.

HOSSEIN ESKANDARY, M.D.

PARVIZ MOHIT, M.D., M.S.

Abstract

A Statistical report of 912 battle casualties admitted in a special unit of the neurological surgery department during 49 months of the recent war was given. Methods of their evaluation, operative categories, management policies including techniques of Missile and bullet removal, and their complications were discussed.

Key Words

Head Injury, war wound, Statistical report, battle casualties, Missile wounds, Management, bullet injuries.

---

HEAD, DEPARTMENT OF NEUROLOGICAL SURGERY  
TEHRAN UNIVERSITY MEDICAL CENTER

RESIDENT, DEPT. OF NEUROLOGICAL SURGERY  
TEHRAN UNIVERSITY SCHOOL OF MEDICINE

RESIDENT, DEPT. OF NEUROLOGICAL SURGERY  
TEHRAN UNIVERSITY SCHOOL OF MEDICINE TEHRAN-IRAN

---

## Introduction

The recent war in the Persian Gulf region with catastrophic mortality and morbidity figures prompted the medical profession in mobilization toward better management of the battle victims.

These efforts have gained unprecedented experiences specially for the surgeons in neurological fields. Experiences so gained can also be used in metropolitan areas with increasing incidences of neurological trauma due to terrorism and suicide attempts.

Better understanding of the mechanisms involved and proper management of these victims at the site of accident may prove to be valuable, in that longer transportation time and thus better management at specially equipped neurological units becomes increasingly more feasible. A Statistical report of 912 battle casualties cared for in our neurological service during four years of war with a brief reference to their management and complications is presented in this report.

## Clinical Materials And Methods

A total of 912 battle casualties, with various neurological injuries, admitted from September 1980 to October 1984 were included in this study. 352 patients (38.59%) had peripheral neurological injuries of which 240 were operated upon. 178 (19.51%) patients with spinal cord lesions were treated, 39 of them had various operational treatments. The remainder were 382 (41.88%) with craniocerebral injuries, mostly missile and bullet wounds, which are the subject of the present discussion (Table 1)

Type of lesion	no. of pts	no of pts operated upon
Peripheral nerve injuries	352	24
Spinal Cord injuries	178	39
Craniocerebral injuries	382	58

Table 1: Battle casualties admitted at a special neurosurgical unit during 49 months of the recent war.

Operations do not include those who were operated in the battle front Facilities or at other centers.

15 or 3.92% of the 382 head trauma patients had gunshot and bullet wounds and the remainder had craniocerebral missile injuries.

The most common site was the frontal lobe and the least was sphenoid sinus and the posterior fossa (Table 2).

Opp. site of entry	no pt.	%
Frontal	74	19.37
Temporal	39	10.20
Parietal	39	10.20
Occipital	34	8.90
Vertex	24	6.28
Orbit	19	4.97
Facial	14	3.66
Sphenoid sinus	4	1.04
Posterior fossa	4	1.04
Frontotemporal	24	6.28
Frontoparietal	39	10.20
Temporoparietal	29	7.59
Parietooccipital	39	10.20

Table 2: Distribution of the lesion sites in craniocerebral bullet and Missile wounds.

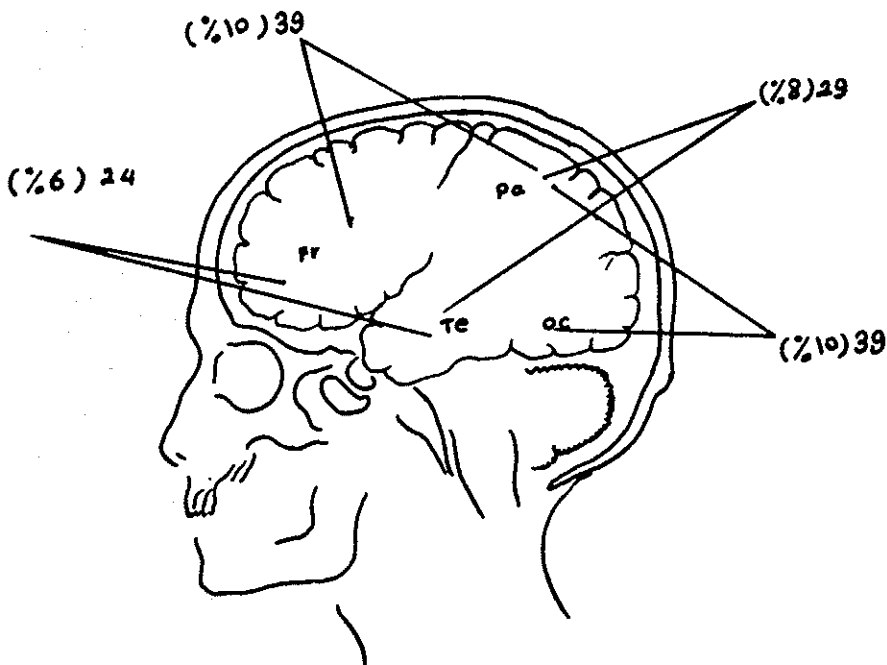
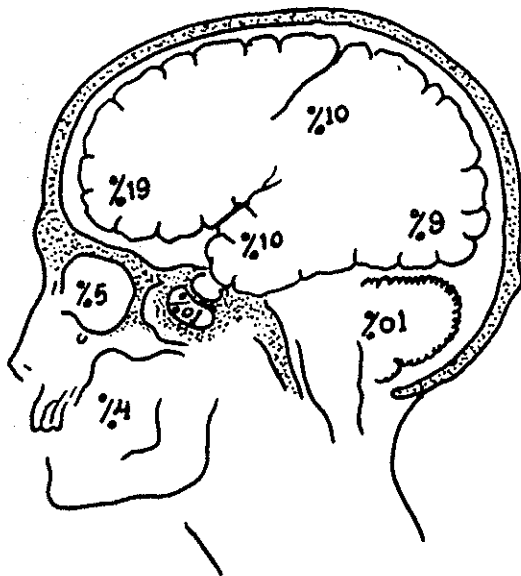
Patients whose general condition were suitable underwent the following diagnostic procedures:

- 1- Skull x Rays For evaluation of the site of offending bullet or missile, bone fragments and depressed fractures at or away from the site of missile entry.
- 2- Angiography was performed on 35 patients in which trauma to major vessel due to bone fragments, missile or bullet were suspicious and/or for evaluation of the patency of the sinuses. In this study no traumatic aneurysm or A.V. Fistula was seen. Only in 2 patients with craniocerebral wounds carotid thrombosis near the bifurcation of common carotid were observed. One case was due to bullet wound and the other due to perforating trauma. Both cases were fatal. One patient was referred from the general surgery department whose common carotid angiography showed a Fistula between vertebral artery, subclavian vein and the common carotid. No surgery was performed on this patient due to his unwillingness and no record of his follow-up is available.
- 3- C.T.Scan is done for most of the patients in this series and has proved to be valuable tool in diagnosis of missiles and bullets, their entry site their direction of penetration, bone fragments in addition to related complications like contusion, hemorrhage of edema.

Therapeutic approach- Antibiotics were used routinely before and after the operations. In our center, Penicillin, Chloramphenicol, Gentamycin and Cephalosporines are used in the majority of cases. Complications encountered have been mostly local scalp infections (Table 3).

Type of Infection	no. of cases	%	% in Hammn series(1)
Local scalp Infec.	20	5.00	0.81
Meningitis	6	1.50	0.63
Brain abcess	3	0.78	-
Osteitis	4	1.04	-
Pulmonary Infec.	8	2.09	-
Urinary Infec.	10	2.60	-

Table 3- Tye of infections and the number of cases seen in this series. Note percantages quoted from similar study.



---

### Complications

Infection- Was mentioned before (Table 3)

Seizure-In this study only one case of epileptic seizure was encountered. We treat all patients with any damage to dura and the brain tissue with antiepileptics e.g. phenobarbital and diphenylhydantoin for various periods extending to 2 years.

Ralph E. Hagan reported 11 cases of epilepsy in post operative study of 506 similar patients (3). The follow up of our patients fail to show any epileptic episode occurring.

CSF Leakage-As mentioned before watertight repairing of the dura mater prevents C.S.F leakage to a great extent. Five cases of csf cutaneous fistula and 2 cases of rhinorrhea were seen in the present study. Treatment should consist of multiple lumbar puncture or cutaneous drainage. Three of 5 and 1 of our cases needed operational intervention with 1 mortality due to infection.

Hydrocephalus- Two cases of hydrocephalus due to intraventricular hemorrhage were seen in this study.

Both were treated with v-p shunting .

Subdural Hematoma-Four cases of massive subdural hematomas seen in this series were treated successfully. Better prognosis of these fortunate patients seems to be due to limited cortical lacerations caused by missile in contrast with high mortality of the blunt trauma acute subdurals.

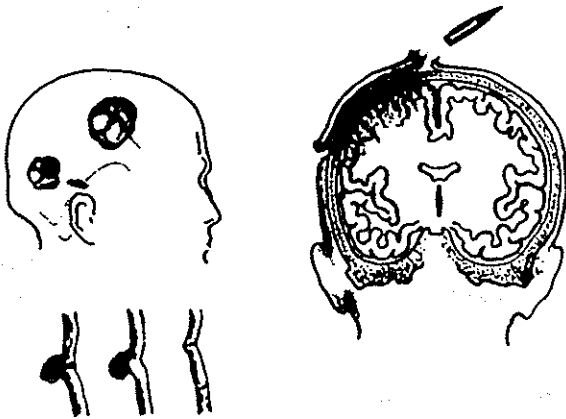
Mortality- In this study the mortality rate was 9.4%. 95 percent were due to severe brain injuries, groups 485- and/or multiple injuries. Two percent were due to infe-



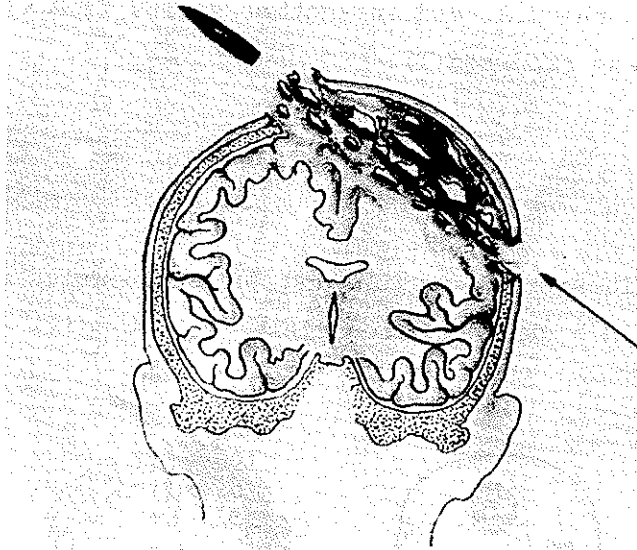
ction. In a similar study Hammn reported a %9.74 mortality rate in the U.S. and in another series from vietham a %14.28 was reported(1).

### Discussion

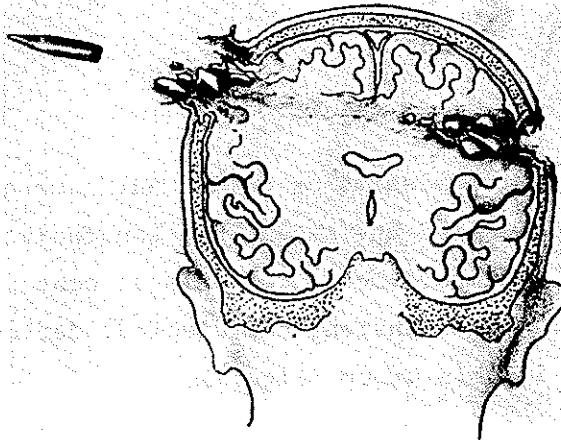
Craniocerebral missile and bullet injuries can be grouped in 5 general categories:



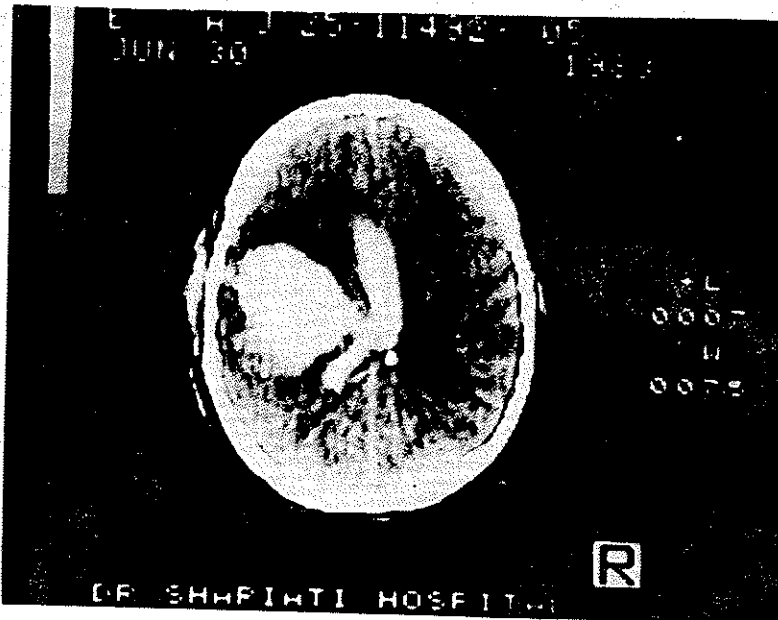
- 1- Injuries in which missile or bullet has lacerated the scalp and damaged the skull in a tangential direction with occasional local brain tissue contusion or laceration. Some transient neurological deficit can be expected in this group (Fig. 1).



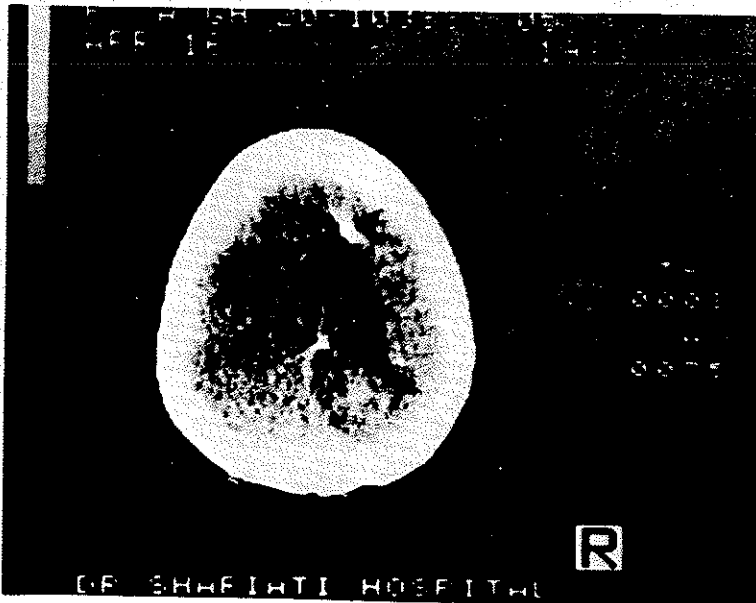
- 2- Injuries in which offending particle has entered From one side and perforated the brain tissue, but the damage is restricted to cortical region (Fig. 2).



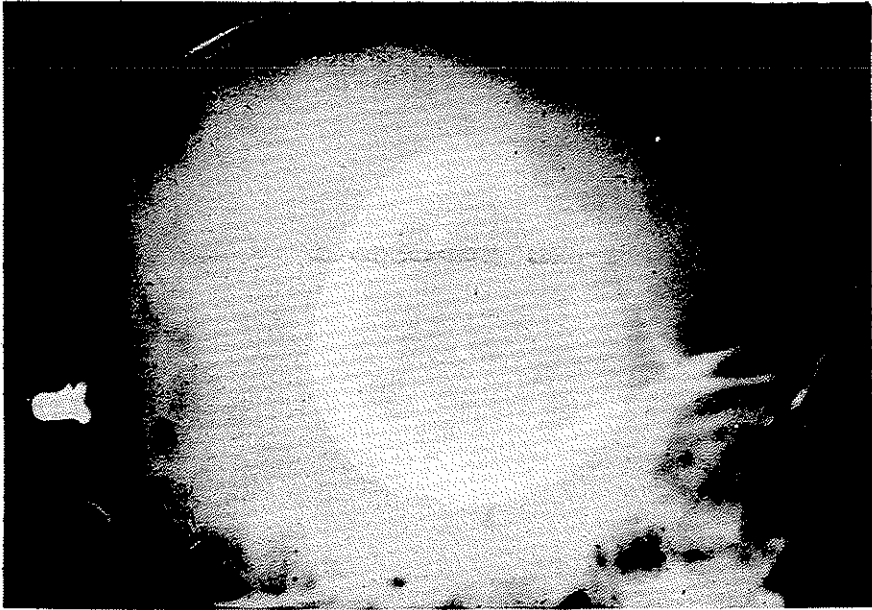
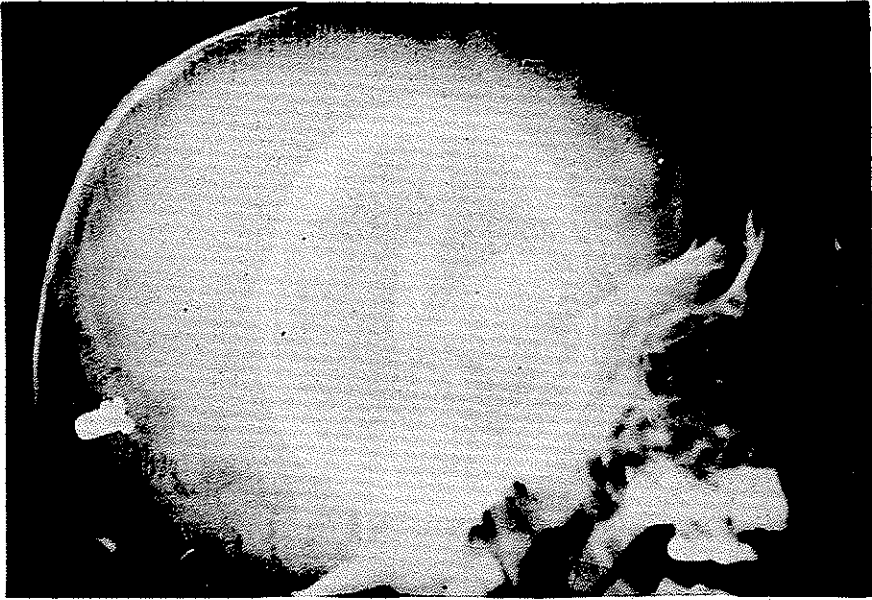
- 3- Injuries in which the bullet has entered the brain tissue and lacerated cortical area. but along with it bone fragments have lodged within the brain. The bullet itself may or may not be embeded there (Fig.-



- 4- Injuries in which the offending particles have passed and damaged the basal ganglia and the ventricles. These patients have suffered critical deficits (Fig.4).



- 5- Injuries in which bullets have entered the cranium with intracranial ricochet. Highly critical damages with great mortality rate is expected in this last group (Fig.5).



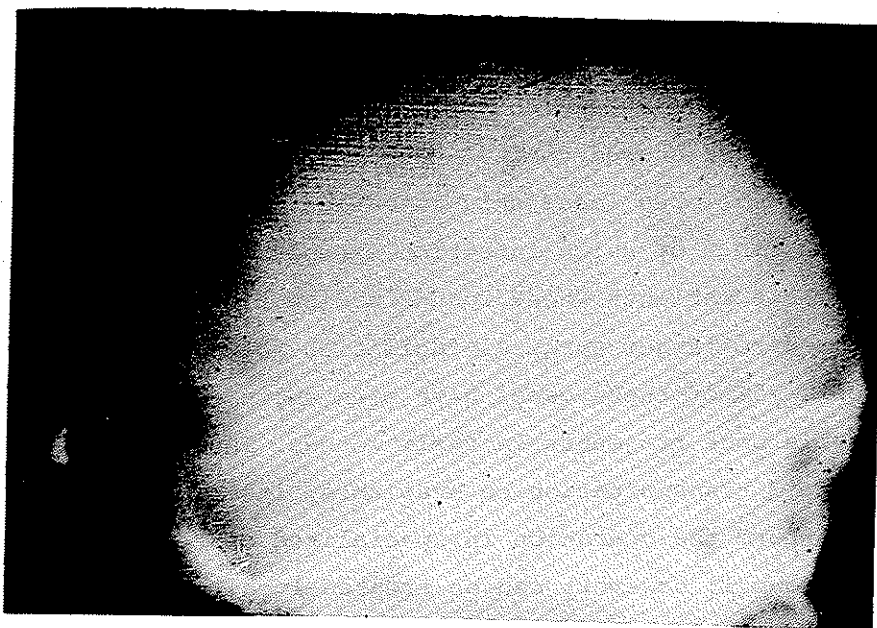


Fig.6. a,b,c In a plain X Ray taken by stereotactic method the bullet was localized 3Cm. above the entry site, a small fracture on the right occipital bone. The patient's head was fixed so that the bullet was in vertical line with the entry site.

Serial daily radiography showed bullet migration. the bullet was easily removed on the 3rd day by a small incision on the skin.

---

From the therapeutic point of view, a speedy surgical management is the most desirable since the rate of infection increases with time.

Garey (2) showed that 44 out of 45 cases of missile trauma developed local skin infection 2 to 4 hours after trauma, in 5 of which infection extended to brain tissue.

Those patients whose wounds are debrided can be transferred to larger surgical facilities for major operations. 75% of these cases have been shown to have had sterile bone fragments in their wounds. Therefore should rapid transportation be available, it might be wiser to perform the operation in specialized centers.

Group 1, however, can be treated locally and debridement should not be postponed for what ever reason.

Group 2, should be treated with debridement of scalp, excision of bone fragments and necrotic tissue within the brain. The dura should be sutured and if necessary grafted watertight. Hagan recommends a "S" shape or elliptical incision for such an operation (3).

Group 3, has to be debrided thoroughly and the necrotic tissues generously excised. Thorough washing is also essential. Bone fragments have to be extracted. If missile fragments or bullet have penetrated to the otherside a secondary operation may have to be performed and the fragments be removed. One must be reminded that a remaining foreign element will increase infection possibility by several folds, However, if a missile fragment is deeply situated and the removal requires destruction of vital parts of healthy brain, this rule can be appropriately waived or special procedures such as stereotaxis may be used.

Group 4, and 5 have to be managed with essentially similar methods and further damage must be avoided with meticulous search and debridements.

Procedures available for removal of missile and bullet fragments:

- 1- Stereotactic surgery may be utilized and the foreign element bereached with great accuracy.
- 2- Fluroscopic procedures aid in localizing the foreign element in many instances. The degree of tissue damage depends on the shape of the element and its location,
- 3- Centrifugation technique is used mostly for bullet extraction. Markham has used this method for the extraction of a metal elemtn lodged in the lateral ventricle and succeeded in extracting the element from the occipital lobe (4).
- 4- Gravitational force utilization is recommended by jefferson (5,6). Migration of the bullet depends on three factors. a -gravitational force of the metal element. b - liquification of the brain tissue around the bullet. c -pulsation of the brain.

The 1st author has the experience of extracting a bullet from the head of a 8 year old boy by this method(Fig.6. a, b, c).

#### Acknowledgement

The authors wish to thank Dr. Y. Tarassoli, assistant professor of neurosurgery for the drawing of Figures 1 to 3 and his and other residents participation in the management of these patients.

---

References

- 1- Hammn W.M. Analysis of 2187 consecutive penetrating wound of the brain from Vietnam. J Neurosurgery 34: 127-31, 1971.
- 2- Garey ME. A bacteriological study of craniocerebral missile wound from Vietnam, J Neurosurgery 34: 145-54, 1971.
- 3- Hagan RE. Early complication following penetrating wound of the brain. J Neurosurgery 34: 132-41, 1971.
- 4- Markham JW, Stein S, Pelligra R. Use of centrifuge in the treatment of an intraventricular metallic foreign body. Technical note. J Neurosurgery 34: 800-4, 1971.
- 5- Jefferson G. Removal of rifle bullet from the right lobe of the cerebellum. Illustrating the spontaneous movement of a bullet in the brain. Brit J Surg 5: 422-24, 1971.
- 6- Hanieh A. Brain injury from a spent bullet descending vertically. J Neurosurgery 34: 222-4, 1971.

Further References

- 1- Adeloje A, Latunde Odeku E. A syndrome characteristic of tangential bullet wounds of the vertex of skull J Neurosurgery 34: 155-8, 1971.
- 2- Crchard HA. Missile Injuries of the brain is operative Neurosurgery. Aurtherop Worths, London: 1979, 76-8.
- 3- Jacobs CB, Berg RA. Tangential wounds of the head.



- J Neurosurgery 33: 642-6, 1971.
- 4- Learer RC, Loeser J.Lhermitt's phenomenon after high velocity missile injury of the brain. J- Neurosurgery 34: 159-63, 1971.