

A CASE REPORT OF WELL DIFFERENTIATED CHONDROSARCOMA OF THYROID GLAND

H. Haeri¹, F. Asadi Amoli² and Sh. Shariat Torbaghan³

(1) Department of pathology, Imam Khomeini Hospital, Faculty of Medicine, Tehran University of Medical Sciences, Tehran, Iran

(2) Department of pathology, Faculty of Medicine, Tehran University of Medical Sciences, Tehran, Iran

(3) Department of pathology, Institute of Cancer, Imam Khomeini Hospital, Faculty of Medicine, Tehran University of Medical Sciences, Tehran, Iran

Abstract - We report a 75 year - old man who presented with a cervical mass, dysphagia and hoarseness, CT - scan of neck showed a large cold nodule in the right lobe of thyroid gland, which was followed by surgical excision and its histopathologic exam revealed well-differentiated chondrosarcoma.

Acta Medica Iranica 37 (4): 249-251 ; 1999

Key Words: Sarcoma, thyroid gland, chondrosarcoma

INTRODUCTION

Sarcomas like fibrosarcoma (8), liposarcoma, (1) osteosarcoma (7), malignant hemangioendothelioma and (2) other sarcomas have been reported to occur in the thyroid gland but they are extremely rare and even the existence of some like malignant hemangioendothelioma has been questioned (4).

In the past, sarcomas were rather common in studies from central Europe, but most of these cases probably represented undifferentiated carcinoma (4,5).

CASE REPORT

A 75-yr-old man presented with cervical mass in thyroid area with out pain. The patient's symptoms appeared five years earlier which had grown over the years causing obstructive symptoms finally ending in dysphagia and hoarseness over the last year. There was no history of head and neck or familial history of thyroid gland malignancy. On palpation, there was asymmetric lobulated enlargement of the thyroid gland with a prominent painless large hard nodule in right lobe, without cervical lymphadenopathy.

On laryngoscopic examination, epiglottis and vallecula were normal but right AE fold, arytenoid and right FVC were edematous and right TVC was paralyzed suggesting right recurrent laryngeal nerve

involvement because of thyroid malignancy, which suggested right recurrent nerve involvement.

Thyroid gland function tests (T3, T4, T3RU, TSH) were within normal limits. In the fine needle aspiration of the nodule no material was obtained for cytologic preparation.

Thyroid scan showed gland enlargement and foci without uptake in both lobes especially a large cold nodule in right one

In the CT-scan of neck with contrast a large hypodense right lobe thyroid mass with an enhancing rim and internal calcification were detected which had displaced the trachea to the left side, obliterating its lumen (Fig. 1). Therapy was undertaken with a high clinical suspicion of malignancy and in order to relieve the obstructive symptoms.

On operation, the thyroid was found to be enlarged having a hard consistency, adherence to adjacent organs especially the right recurrent laryngeal nerve.

PATHOLOGIC FINDINGS

Macroscopic

A specimen consisted of a thyroid lobe measuring 10 × 8 × 7 cm, 210 gr and on cutting a well - defined nodule with maximum diameter of 7 cm white - gray in color and cartilaginous consistency was seen. Surrounding thyroidal tissue was solid, brownish in color with meaty consistency.

Microscopic

On microscopic examination, neoplastic tissue showed proliferation of cartilaginous tissue of pleomorphic chondrocytes with lobular appearance and compression and invasion of adjacent thyroid tissue with foci of calcification and ossification was observed (Fig. 2,3).

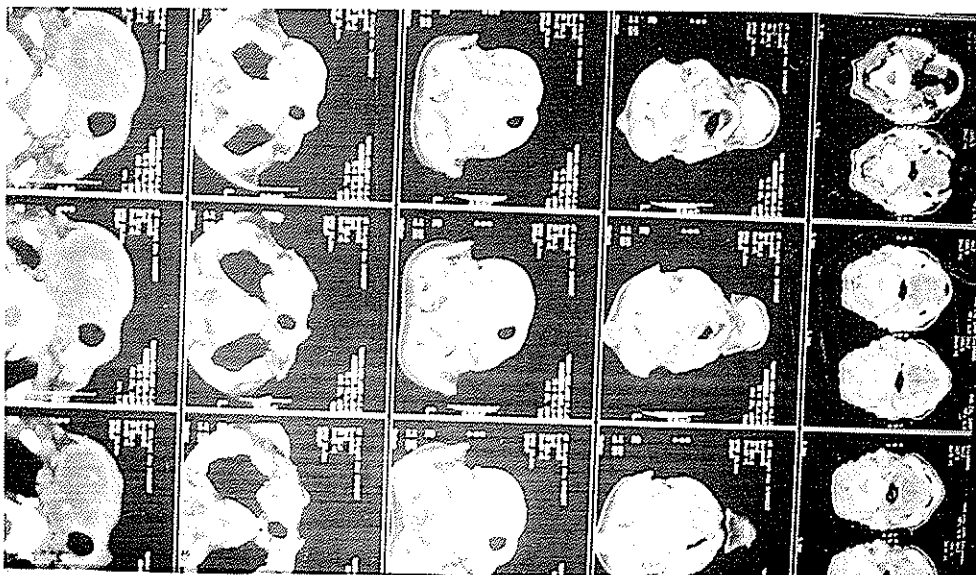


Fig. 1. Neck CT - scan demonstrating a hypodense right thyroid lobe mass with internal calcification.




Fig. 2. Microscopic view of chondrosarcoma in thyroid gland tissue (H & E × 400)

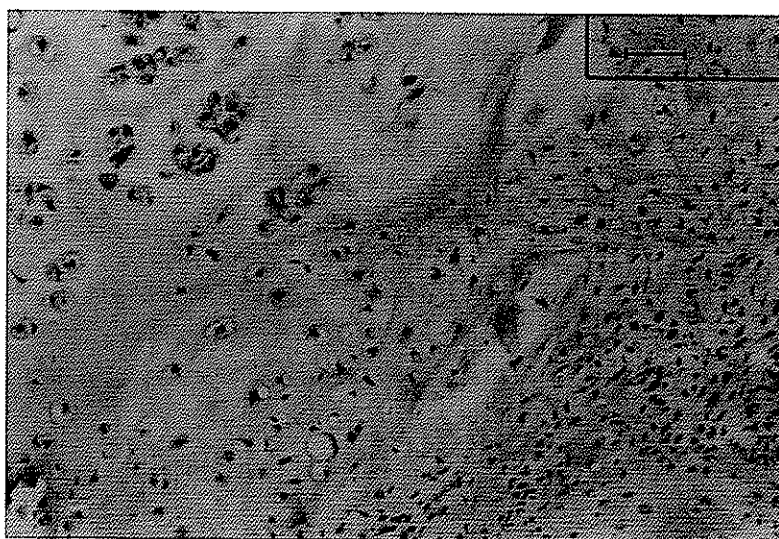


Fig. 3. High magnification appearance of neoplasm demonstrating well differentiated chondrosarcoma. (H & E × 600)

DISCUSSION

The sarcoma of thyroid comprises less than 1% of all thyroid neoplasms, and although sarcoma of various microscopic types has been reported in thyroid but usually in the form of individual case reports.

These include fibrosarcoma (8) liposarcoma (1) leiomyosarcoma (3) osteosarcoma (7) and malignant schwannoma (6). It should be remembered that most sarcoma - like thyroid tumors have been reported as primary to the thyroid which will prove to be examples of undifferentiated (sarcomatoid) carcinoma when appropriately studied with immunohistochemistry and electron microscopy (4,5).

A histologically confirmed was presented. In the review of literature, we found only one case report of primary myxoid chondrosarcoma of the thyroid gland (9).

REFERENCES

1. Andrion A., Gaglio A., Dogliani B., Osco E. and Mzzuccoce. Liposarcoma of the thyroid gland. *Am. J. Clin. Pathol.* 95: 675-679; 1991.
2. Beer TW. Malignant thyroid haemangioendothelioma in non endemic goitrous region. *Hisopathology.* 20L 539-541; 1992.
3. Lida Y., Kato R., Yoshioka M., Oyamata and Kawaoi. A primary leiomyosarcoma of the thyroid gland. *Acta. Pathol. J. Ph.* 43; 71-75; 1993.
4. Krisch K., Holzner JH., Kokoschka. and Roka R. Hemangioendothelioma of the thyroid gland - true endothelium or anaplastic carcinoma? *Patho. Pract.* 170; 230-242; 1980.
5. Mills SE., Stallings RC. and Austin MB. Angiomatous carcinoma of thyroid gland : Anaplastic carcinoma with follicular and medullary features mimicking angiosarcoma. *Am. J. Clin. Pathol.* 86; 674-678; 1986.
6. Naruse T., Kokie A. and Suzumura K. Malignant triton tumor in the thyroid a case report. *J. Pn. J. Surg.* 21; 466-470; 1991.
7. Ohbu M., Kameyat. and Wada C. Primary osteogenic sarcoma of the thyroid gland : A case report. *Surg. Pathol.* 2; 67-72; 1989.
8. Shin W., Aftalion B., Hotchkiss E., Schenkaman R. and Berkman. Ultrastructure of a primary fibrosarcoma of the human thyroid gland. *Cancer.* 44; 584-591; 1979.
9. Tseleni BS., Arvanitis D., Kakaviatos N. and Parakevakou H. Primary myxoid chondrosarcoma of the thyroid gland. *Arch. Pathol. Lab. Med.* 112; 94-96; 1988.