

LOW FREQUENCY SENSORINEURAL HEARING LOSS (A NEW NEURO-OTOLOGIC DISEASE ENTITY)

Mohammad Hassan Khalessi*, MD

* Professor, Tehran University of Medical Sciences, Faculty of Medicine, Amir Alam Hospital.

SUMMARY

Fourteen patients with bilateral low frequency sensorineural hearing loss were found with disproportionate speech discrimination scores. These patients were submitted to a comprehensive audiological, electrophysiological, neurological, and radiological battery of investigation. The results pointed to a lesion probably in the central auditory pathway.

KEY WORDS: Auditory brain-stem response (ABR); Electronystagmography (ENG); Neurofibromatosis (NF₂); Speech discrimination score (SDS).

INTRODUCTION

Bilateral sensorineural hearing loss has generally a high frequency configuration. However, low frequency loss is frequently associated with some cochlear pathology such as Ménière's disease, inherited traits, and viral infections.

In cochlear lesions, speech discrimination scores are expected to comply with the audiometric pattern and the degree of hearing loss; therefore, in the presence of marked loss of speech recognition, out of proportion to the pure tone thresholds, a retrocochlear or a central auditory disorder is suspected.

MATERIALS AND METHODS

In a period of three years, fourteen patients were seen in the Audiology Unit at Amir Alam Hospital.

All patients presented a low frequency sensorineural hearing loss with a disproportionate speech discrimination scores (Fig. 1).

The discrepancy between the pure tone thresholds and speech discrimination scores directed

the attention of the author to a new pathological neuro-otologic entity or a syndrome.

A detailed history was taken from all subjects, followed by ear nose and throat examination.

Pure tone air and bone conduction testing, speech audiometry, tympanometry, and acoustic reflex measurement were conducted on all patients, but brain-stem evoked response audiometry, Bekesy audiometry, electronystagmography (ENG), electroencephalography (EEG), and CT Scan were administered on eight of them.

RESULTS

Fourteen patients: seven males and seven females with an age range of 16-50 years, were examined over a period of three years.

The major complaint was speech discrimination difficulty accompanied by hearing loss. The duration of major complaint ranged from 4-12 years.

None of the patients reported vertigo, except for patient 7; ear discharge or any neurological symptoms except for patient 1 who had optic nerve atrophy.

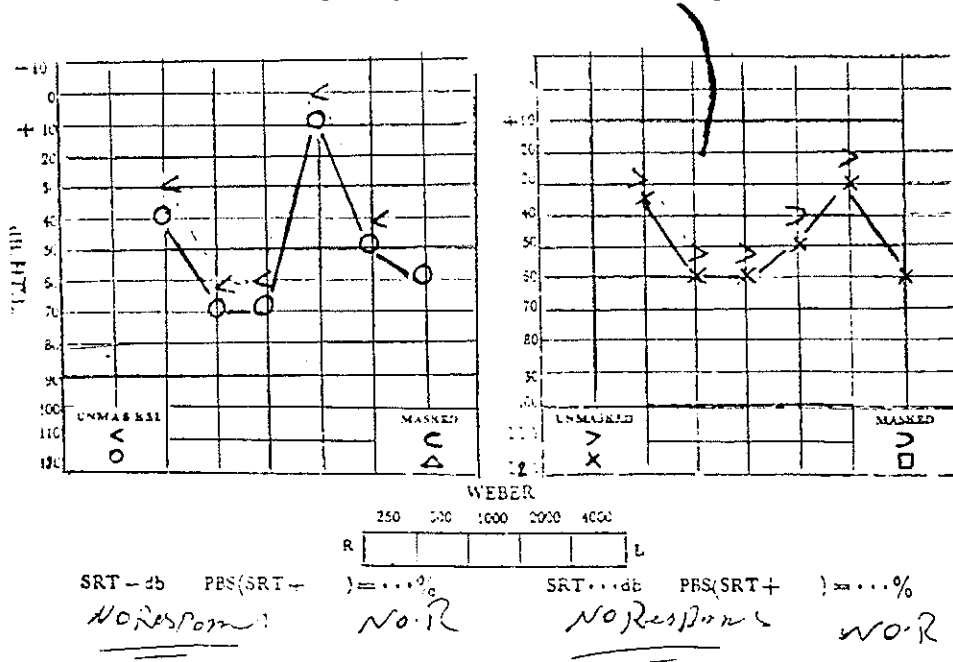


Fig. 1. Pure tone and speech audiogram. Case 8.

Three of the fourteen subjects reported the family history of sensorineural hearing loss.

Ear, nose and throat examinations revealed no abnormality in any of the patients.

Pure tone audiometry results revealed bilateral low frequency sensorineural hearing loss in all cases. Speech discrimination scores ranged from 0% to 85%.

Immittance tests revealed bilateral normal type A tympanograms for all patients.

Acoustic reflexes were bilaterally absent in five cases but were present at higher than expected threshold in three cases. Two of the latter cases showed some degree of reflex decay.

Bekesy audiometry was type 1 in two patients being tested.

Brain-stem evoked response audiometry performed in six patients had the following results:

In case 3 (M.S.), there were normal latency of waves I-V, but bilaterally abnormal morphology of all the waves.

In case 4 (V.F.), ABR performed in July, 1989, showed no waves in the left ear but normal latency and morphology of waves in the right side, whereas

in follow up tests, in September, 1990, ABR was normal in both ears.

In cases 7 and 8, none of the waves was shown to be bilateral. (Fig. 2)

In case 10 (E.M.), no wave was bilateral except for the wave I in the right ear. In case 12 (A.A.), no wave, except for the wave V, was seen with some delay.

Electronystagmography (ENG) and electroencephalography (EEG) were normal in all the patients being tested.

Laboratory tests, including FTA abs and autoimmune blood tests were normal. Except for case 5 who had moderate hyperlipoproteinemia, and case 11 and 12 who showed some hypolipoproteinemia. CT Scan performed in nine patients revealed normal inner ear structures with no other pathological signs in seven cases (Fig. 3), but an optic nerve atrophy in case 1 and a posterior fossa meningioma in case 7 (Fig. 4). It seems that there is no relationship between these two pathological signs and their hearing problem. However, the tumor in case 7 was in worse hearing side and hearing was deteriorated a little after tumor removal (Fig. 5).

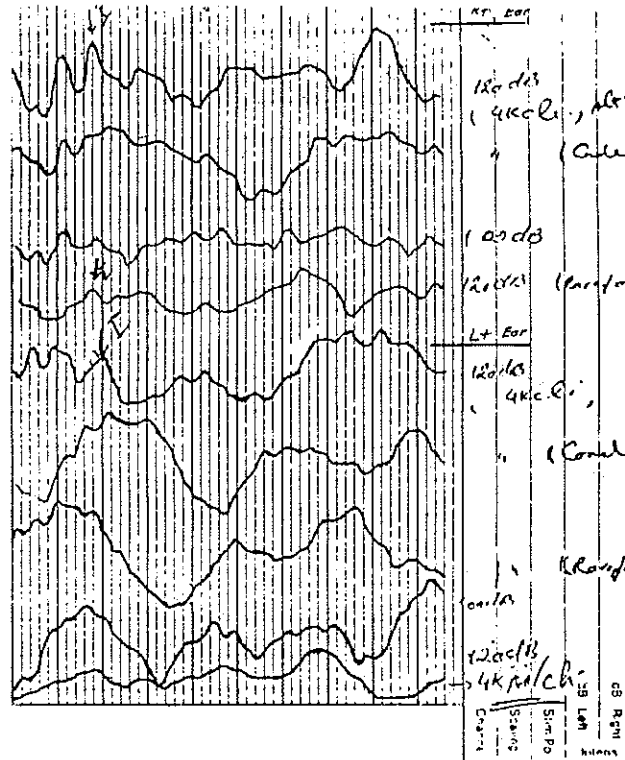


Fig. 2. Brain-Stem evoked response audiogram. Case 8

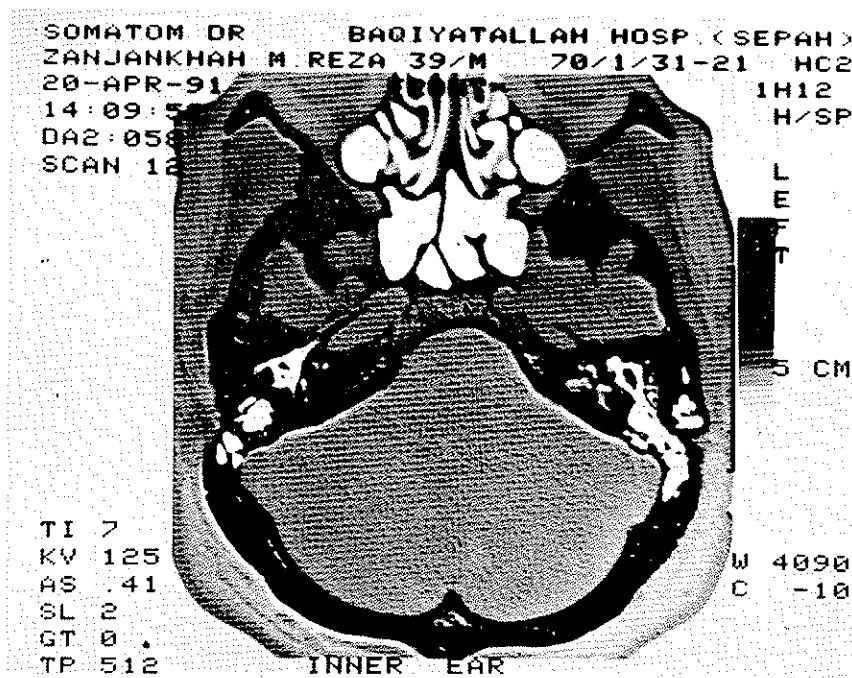


Fig. 3. CT Scan. Case 8. Normal inner ear structures

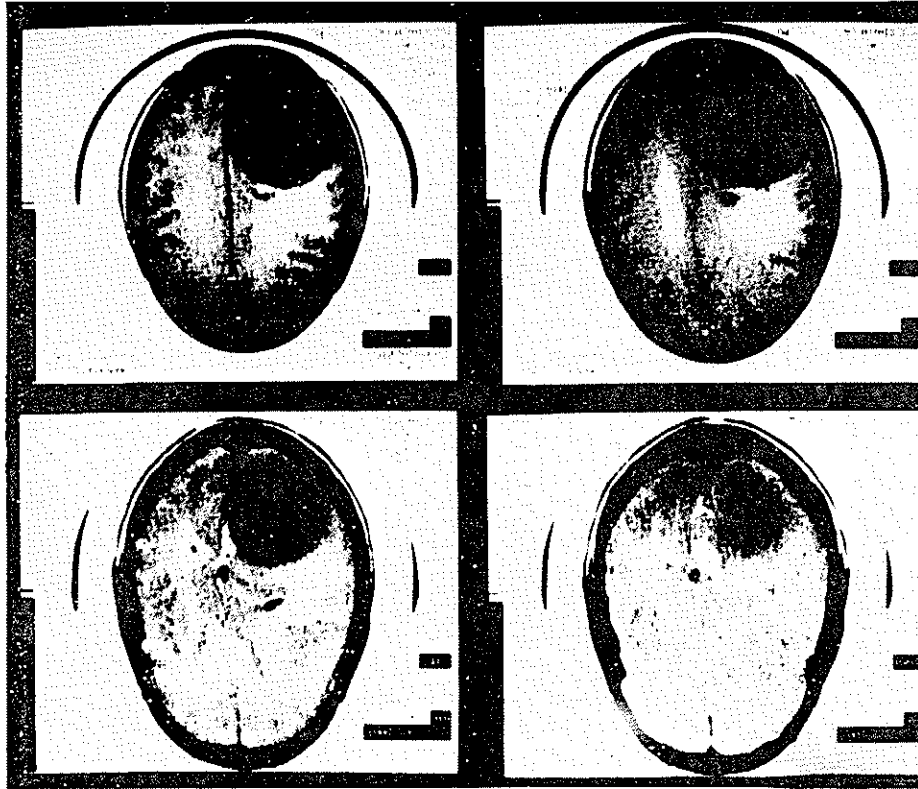


Fig. 4. CT Scan. Case 7. Posterior fossa meningioma

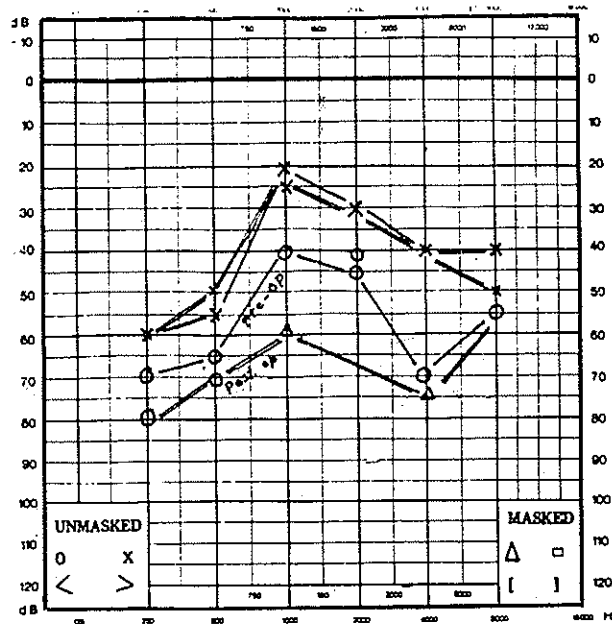


Fig. 5. Deterioration of hearing after tumor removal. Case 7

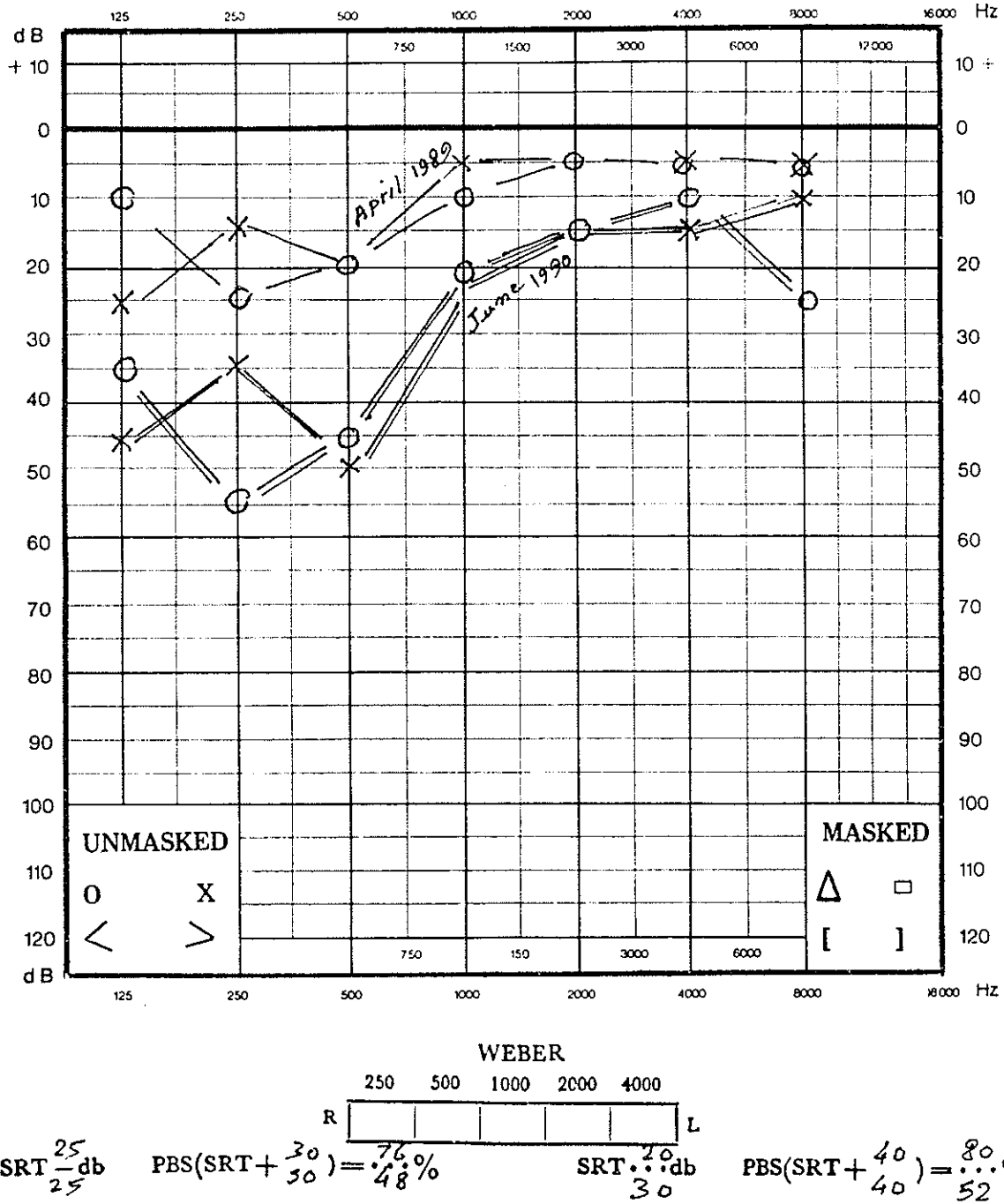


Fig. 6. Progression of hearing loss and deterioration of speech discrimination in case 4

DISCUSSION

In a period of three years, fourteen patients with low frequency usually progressive sensorineural

hearing loss were evaluated (Fig. 6).

Low frequency loss in all patients in this study was bilateral sensorineural and symmetrical with a marked difficulty in speech discrimination.

Low frequency of flat type sensorineural hearing loss may be seen in some cochlear and retrocochlear pathology:

- Ménière's disease, may be associated with low frequency sensorineural hearing loss without vestibular symptoms in the early stages, but there is a fairly good discrimination in these stages and hearing is usually fluctuant.

- Sterial presbycusis is a common pathological entity, occurring slowly in the third to six decades of life with a flat audiometric pattern, but with an excellent discrimination score.

Mundini dysplasia might show a bilateral slowly progressive sensorineural hearing loss with a flat audiometric pattern and with a poor discrimination but may have a positive family history and the radiological signs of the disease.

Bilateral sensorineural hearing loss with different patterns may be seen in retrocochlear lesions such as bilateral acoustic neuroma (NF₂) with poor speech discrimination, but this disease has also its distinct radiological signs.

- Multiple sclerosis, best represents the demyelinating disease in the central nervous system, can produce auditory symptoms, but it is usually with vestibular dysfunction in up to 50% and with other neurological symptoms and signs.

At the end, bilateral low frequency sensorineural hearing loss has a distinct clinical feature quite different from the hearing pathology as right now being known, and it gradually becomes more and more significant.

Further research is needed to identify the specific etiologic factor(s) causing this low frequency hearing disorder.

ACKNOWLEDGMENT

The author would like to thank Miss S. Abdi and Mr. S. Farahani, the audiologists of the audiology section of the ENT department at Amir Alam Hospital for their assistance in performing the hearing tests.

REFERENCES

- 1) Yost, WA, & Nielsen, DW. (1985). Fundamentals of Hearing: An Introduction. (2nd ed.). Chicago, New York, London: Holt Rinegart Winston.
- 2) Katz, J, Ph.D. (1975). Handbook of Clinical Audiology, (3rd ed.) Baltimore, London, Los Angeles: Williams & Wilkins.
- 3) Schuknecht, HF, MD. (1974). Pathology of the Ear, Cambridge, Massachussettes: Harvard University Press.
- 4) Booth, JB. (1987). Scott Brown's Otolaryngology, (5th ed.). (p. 3). Boston, London: Butterworths.
- 5) Soliman, SM. (1987). Low frequency sensorineural hearing loss. *Audiology*, 26, 332-338.
- 6) Takashi, F, MD, *et al* (1991). Transient retocochlear low frequency sensorineural hearing loss. *Laryngoscope*, 110.