

DISTRIBUTION OF SCIATIC NERVE IN HAMSTRING MUSCLES

R. Khaleghi, M. Barbarestani, M. Akbari, P. Pashaksh, H. Marzban and F. Zangenehnia

Department of Anatomy, Medical Faculty, Tehran University of Medical Sciences, Tehran, Iran

Abstract - Regarding the importance of sciatic nerve distribution in replacement of anal sphincter and sciatic nerve block we decided to study this matter for the first time in Iran. In this way 100 cadavers (88% male and 12% female) were dissected and studied by loop microscope. The results shows that primarily, according to the first branch derived from sciatic; there would be 4 main Groups. If this samples were regarded according to the second branch of the nerve, then there would be 6 accessory groups added. So, in group A the first branch was related to proximal part of semimembranosus, in group B the branch was recorded to... . Some scarce cases (6%) were recorded as normal variations based on the above mentioned patterns.

Acta Medica Iranica 38 (2): 89-91; 2000

Key Words: Sciatic nerve distribution, hamstring muscle

INTRODUCTION

The posterior muscles of the thigh consist of semitendinosus (ST), semimembranosus (SM) and biceps femoris (BF), which are collectively known as hamstrings. The major function of them are flexion of the knee and extension of the hip joint (1). In some disorders leading to shortening of these muscles (2), and in replacement of anal sphincter their innervations are important (3). Since such a study hasn't been conducted in Iran we decided to do it by studying 100 samples.

The sciatic part of adductor magnus in mammals develops separately from its obturator part and joins the medial group muscles of the thigh but its innervation is still from sciatic nerve. In this way the sciatic nerve, entering the posterior part of the thigh, innervates the hamstrings distal to the ischial tuberosity (1).

Hamstrings mainly originate from ischial tuberosity. The SM from superolateral surface, the ST and the long head of BF from medial surface and AM from inferolateral surface of the tuberosity (1).

The SM insert to the medial condyle of tibia and oblique popliteal ligament. The ST inserts to the medial border of tibial tuberosity naming pes anserinus tendon. The short head of BF originates from lateral lip of linea aspera and after joining with the long head, inserts to

the head of fibula (1).

On the other hand, in other country Fenzel G and coworkers (5) Himstedt and coworkers (6) and Rab M and coworkers (3) have worked on topography of sciatic nerve.

MATERIALS AND METHODS

The study was prepared on right lower extremity of 100 cadavers in Anatomy department of Tehran, Shahid Behshti and Azad universities. In all cases the cadavers were intact. At first they were positioned prone, anatomical position and then skin incisions were made on gluteal and posterior thigh regions based on Grant's method (4). Incising the skin and superficial fascia, the sciatic nerve was exposed. Then the nerve was followed by its entrance to hamstrings. All of the lengths of primary branches are measured from ischial tuberosity till second branches by collis and the second branches from their branching points till their entrance the muscles by collis (Fig. 1).

Then the related pattern were drawn on mm. papers. Some of the samples were photographed and finally they were degined by 3D. Max and 3D. studio software.

RESULTS

It was found out in this study that, in 15% of cases, just 2 branches, in 34% of cases 3 primary branches, in 36% of cases 4 primary branches, in 16% of cases 5 primary branches and in 2% of cases 6 primary branches branched off from tibial part of the nerve. In 95% of cases the peroneal and tibial parts of the nerve, were enclosed in a same sheath when entering in popliteal fossa. In these cases the branch from peroneal part of sciatic nerve for the short head of biceps femoris was always distal to the last branch of tibial part. In 5% this branch head different origin depending on the location of bifurcation of the two parts of sciatic. In 66% of cases the branch to the proximal part of ST was among the first branches. In 98% cases the branches to SM and the sciatic part of AM, had a common trunk which in 66% of cases it was the last lateral branch of the sciatic part of the nerve. Separate

branches are sent to the proximal part of ST and the long head of BF which in the case of branch to ST, just in 1% of cases a common trunk was seen though this percent was 72% for BF branch.



Fig. 1. Primary divisions of sciatic nerve in hamstring muscles

Based on the primary branches, the tibial part of the sciatic nerve may be divided to 4 groups (i.e: A,B,C,D). In group A, consisting 36% all cases, four subdivisions were found. In this group the first branch was sent to STp muscle. In 94.5% of cases, the second branch was for BFp and in 58.3% of cases, for BFd. The third branch in 75%, 27.7% and 44.4% of cases was respectively for STd, BFd and a common trunk for SM + AM. The fourth branch in 5.5%, 50% of cases was respectively for common trunk for STd + FBd + FBd or SM + AM.

The fifth branch in 19.5%, 8.5%, 5.6% was respectively related to STd, BFd and SM. In 5.6% of cases a sixth branch existed which was related to AM. In group B consisting 24% of all cases, the first branch was a common trunk for STp + BF. The second branch in all cases was a common trunk for AM and SM but in 58.2% of cases this branch was for STd. In 41.8% of caesa a branch for STd was the third one. In

this group no other branches existed.

The group C consist 24% of all cases, had a common trunk for BF as it's first branch. In this group, the second branch in all cases was related to STd and 58.3% to a common trunk for AM and SM. The fourth branch in 21% was related to STd and in 17.7% to a common trunk for AM and SM.

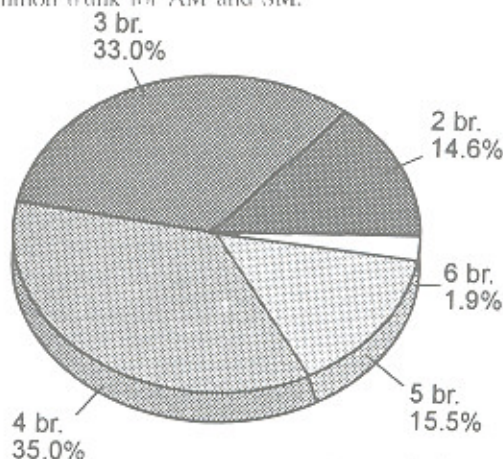


Fig. 2. Numbers of divisions driven from sciatic nerve to hamstring muscles

Group D with 10% of all cases had the first branch for the proximal part of BF the second branch also completely dedicated to the proximal part of BF the third branch in 60% was related to BFd and in 40% to a common trunk for AM and SM the fourth branch in 30% was related to STd and in 40% of cases to BFd and in other 30% to a common trunk for AM and SM the fifth branch in 70% was related to STd and in 30% to a common trunk for AM and SM. (Fig. 2).

The E,F and G groups may be considered as variation.

In group E, consisting 4% of all cases the first branch was a common trunk for STp + BF + STd and the second branch was a common trunk for AM and SM.

In group F, consisting 1% of cases, the first branch was a common trunk for STp + BF + STd and the second branch was a common trunk for AM and SM.

In group G which consist 1% of all cases, a common trunk for ST, was the first branch and a branch to BF, was second and a common trunk for AM and SM was the third branch of sciatic nerve in posterior thigh.

DISCUSSION

As it was for the first time that such a study took place in Iran, the result of this research won't be comparable. In medical statics of medline, such a study in human wasn't reported either.

But, Butler and his coworkers, obtained 3 major groups on their research on rabbit. In these animals the hamstring part of adductor magnus muscle is separately located on hamstring compartment. Chelly (8) used these researches for blocking the sciatic nerve with anterior approach and claimed that the results may also be true for human being's. But he just had considered the proximal part of the nerve below the ischial tuberosity and our study concerns the whole length of the sciatic nerve in posterior aspect of the thigh. Fenzl by doing cross sections and studying the topography of sciatic nerve in human hamstring muscles said that 87% of proximal part of the nerve was composed of proneal nerve and the lowest branch (belongs to short head of biceps femoris) in 89% of cases was a branch of tibial nerve. It seem's to be well worth to study the pattern of distribution of sciatic nerve below the popliteal cavity and the advantages of specific patterns in different procedures of tendon transfer.

REFERENCES

1. Grays' Anatomy: William Warwick, 37th edition, London, Churchill Livingstone, 1995; 644.
2. Outline of orthopaedics, J. Crawford Adams. 10th edition London; 1989: 197-217.
3. Rab M., Mader N., Kamolz Lp., Hausner T and Girsch W. Basic anatomical investigation of ST and long head of BF for their possible use in electrically stimulated neosphincter formation. Department III, University of Vienna, Austria. Surg Radiol Anat. 19(5): 287-91; PMID: 9413073: 1997.
4. Grant's dissector, Eberhardt K.Sauerland. 8th edition London, Churchill Livingstone, 1986: 121.
5. Fenzl G., Zinnecker R and Anat Anz. Topography of the sciatic nerve fibers in regard of clinical use, 163(2): 107-10. PMID: 3592252, Germany, 1987.
6. Himstedt HW, Schumacher Gh, Menning A, Lau H and Schultz M., Anat Anz. Topography of muscular nerve spreading 4.lower extremity, ischiocrural muscles ST, and SM: 134 (1): 8-19; Germany, 1973.
7. Butler PE, Sims CD, Randolph MA, Menkes D, Onorato J and Lee WP. A comparative study of nerve healing in adult, neonatal, and fetal rabbits. Department of Neurology at Massachusetts General Hospital, Boston, USA. PMID: 10513922.
8. Chelly J E and Delaunay L. A new anterior approach to the sciatic nerve block. Department of anesthesiology, the university of Texas medicine school-Houston, USA. PMID: 1999.