

VITREOUS LOSS: INCIDENCE AND ITS COMPLICATIONS IN EXTRACAPSULAR CATARACT EXTRACTIONS

A. Nikeghbali., M. Mirsamadi and M. Hashemi

Department of Ophthalmology, Faculty of Medicine, Iran University of Medical Sciences, Tehran, Iran

Abstract - One of the dangerous complications of cataract extractions is vitreous loss. The purpose of this study is to evaluate the incidence of vitreous loss and its sequale while teaching residents at Rasoul Akram Hospital in Iran. This study has been conducted on existing records of 730 eyes which were subjected to extracapsular cataract extractions by 3rd and 4th year, right handed residents of Rasoul Akram hospital. The information was taken from the records of patients who had vitreous loss during cataract surgery and the following data was extracted. The presence of any systemic diseases, phase of operation where vitreous loss occurred, vision on the next day, one month and 3 months later, the cause of low vision and any post operative sequale of the eye were evaluated. Extracted data collected and the prevalence of vitreous loss and its sequale were identified and presented. Forty-nine eyes (6.7%) had vitreous loss, thirty-one of them were in the left eye (63.3%) and eighteen of them were in the right eye (36.7%). Regarding the stage of operation in which vitreous loss had occurred: twenty-eight eyes while nucleous delivery (57.7%) eighteen eyes during aspiration of cortical material (36.7%) and in three cases during IOL implantation. Five eyes had pseudoexfoliation syndrome, four patients were diabetic and three had high myopia. Post operational sequale of these 49 eyes were: Thirty-five with transient corneal edema (71.4%), nine with misshaped pupils (18.9%), four with high astigmatism (8.1%), two with cystoid macular edema (4%), two with retinal detachment (4%) and seven with cloudy vitreous (14.3%). The incidence of vitreous loss is more than expected. More extensive research to evaluate the prognostic factors according to the eye (OD/OS) and the stage of the operation that leads to vitreous loss and to decrease its incidence is still needed.

Acta Medica Iranica 38 (3):111-114; 2000

Key Words: Cataract extraction, incidence of vitreous loss, complications in cataract extractions.

INTRODUCTION

Loss of vitreous is one of the most serious complications that occurs during cataract surgery. The complications resulting from operative loss of vitreous are due to morphologic changes in the vitreous body which are related to different mechanisms including direct contact of vitreous with other tissues, incarceration of vitreous into the operative wound,

fibroplasia of residual vitreous and chronic inflammation. Common ocular complications after operative loss of vitreous are excessive degree of astigmatism, bullous keratopathy, epithelial invasion of the anterior chamber fibrous ingrowth, wound infection and endophthalmitis, iris prolapse, updrawn or misshaped pupil, fibroplastic traction bands, secondary glaucoma, cystoid macular edema, vitreous opacities and hemorrhage, expulsive hemorrhage, retinal detachment and chronic irritability of the eye(1).

The past 40 years have been marked by significant progress in reducing the incidence of operative loss of vitreous. The experience of Vail (2) and Barrquer (3), Troutman and Routlan(3) probably reflects the most accurate documentation of progress made in recent years. Vail(2) reported a 12.7% incidence loss of vitreous since 1925 until 1945.

According to Barraque and co-workers(3) the rate of vitreous loss fell from 7.3% in 1945 to less than 1% 20 years later. Jaffe(1) believes that an incidence of vitreous loss of not more than 3% should be attained.

Chitkara and, Smerdon (4) reported the chance of loss 5.3% in high risk eyes and 3.7% in low risk groups and 4% overall in 1552 patients that underwent extracapsular cataract extractions (ECCE). Because of the significance of this complication and lack of any report of vitreous loss in Iran, we have decided to evaluate the incidence and complications of intraoperative vitreous loss in cataract extractions in a year of teaching residents at a hospital in Iran. The results of this research could be the basis for further research and steps suggested for the prevention of this complication.

MATERIALS AND METHODS

This is a descriptive study conducted on existing records of 730 eyes that underwent extracapsular cataract extractions (ECCE) performed by 3rd and 4th year, right handed residents at Rasoul Akram hospital which is a teaching hospital of Iran Medical Sciences University and located in Tehran, Iran. This study was conducted during a year long period from November 1997 to November 1998. Congenital and traumatic cataracts and the eyes that had previous vitreous damage were excluded from this study. The files of all

cataract-operated eyes with senile cataract were reviewed and the files of those eyes that had posterior capsule rupture and vitreous loss during cataract surgery were identified and the following data was transferred to information sheets. The data collected from the records included the age of the patient, the presence of any systemic diseases, eye (left or right) on which surgery was performed, the type of anesthesia used, the phase of the operation where in vitreous loss occurred, the management of the eye after vitreous loss, the vision and the intraocular pressure (IOP), the status of the cornea, retina and media opacities on the first day, at one month and at 3 months post operation, the reason for having a vision of less than 20/40, and finally, the major postoperative ocular complications and their treatments. The data collected were categorized and then underwent a descriptive statistical analysis.

Technique

Eight, right handed, 3rd and 4th year residents at Rasoul Akram Hospital had performed all operations. General anesthesia was preferred but local anesthesia had been attempted by using 3cc-retrobulbar and 7cc-akinesia injection of 2% lidocaine by the surgeon. The technique of ECCE in all cases had been: limbal incision with 3 pre- placed 6-0 silk sutures and a can-opener capsulotomy performed. Under viscoelastic material, nucleus expression was performed by pressing on the inferior limbus with the left hand and right and on the superior, posterior to the incision. Aspiration of cortical material was performed with a Simco needle while A/C maintainer formed anterior chamber deepening, then interrupted 10-0 nylon suturing was used for closure of the incision after the I.O.L implantation.

RESULTS

This study included 730 eyes that had ECCE during the year long period from November 1997 to November 1998 at Rasoul Akram hospital located in Terhan Iran. Forty-nine eyes had vitreous loss during ECCE (6.7%). The confidence Interval (CI) for the development of the vitreous loss is 5% to 8.5% for the patients of this study. The mean age of the patients was 65 + 5 (range = 45-90) years. The male to female ratio is 27/22 (55.1% / 44.9%). Local anesthesia was used in 24 cases (59.2%) and general anesthesia in 20 cases (40.8%). Vitreous loss occurred in 31 of the left eyes (63.3%) and in the right eye it occurred in 18 eyes (36.7%). The confidence interval for the development of vitreous loss in the left eye was 50-76%. Of the forty nine eyes that had vitreous loss, four of the cases had diabetes mellitus, nine had controlled hypertension and

five had pseudo-exfoliation (PXI). Three of the eyes had myopia with more than 6 diopters (Fig. 1). Vitreous loss had occurred in twenty-eight eyes during nucleus delivery (57.3%). It occurred in eighteen eyes during the course of aspiration of cortical material (36.7%) and in three eyes during subsequent manipulation (Fig. 2). All patients who suffered vitreous loss underwent limbal anterior vitrectomy by the use of a vitrectomy machine. In twenty-two eyes anterior chamber intraocular lens were implanted. The best-achieved corrected visual acuity is shown in Table 1.

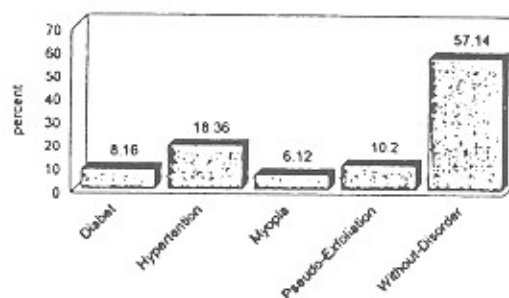


Fig. 1. Frequency of systemic disorders of the eyes with vitreous loss during ECCE in Rasoul Akram Hospital Nov, 97-98.

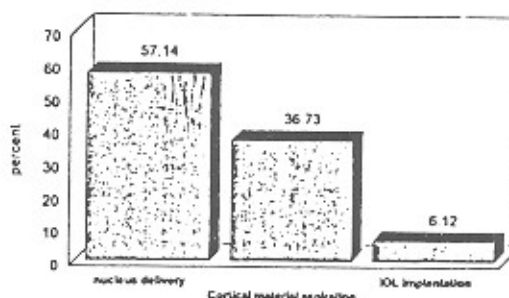


Fig. 2. Frequency of vitreous loss in different phases of ECCE + IOL in 49 patients-Rasoul Akram Hospital Tehran Nov, 97-98.

Distribution of the post-operative complications of the forty-nine eyes are shown in Fig. 3. One out of the thirty-five eyes that had macular edema needed P.K. due to irreversible bullusk keratopathy. Nine of the eyes had misshaped pupils (18.9%) and seven eyes had vitreous opacity (14.3%). Four of the eyes had astigmatism with more than 3 dippter (8.1%), two with

cystoid macular edema (4%), two retinal detachment (4%), and (6%) photophobia

Table 1. 3 Months post operative visual acuity of eyes with operative loss of vitreous during ECCE in Rasoul Akram Hospital Tehran NOV 97-98

Visual acuity	Number	Percent
F.c - 1.10	10	20.4
> 1/100- < 4/10	12	24.5
> 4/10 - < 7/10	17.5	34.7
> 7/10	10.3	20.4
Total	49	100

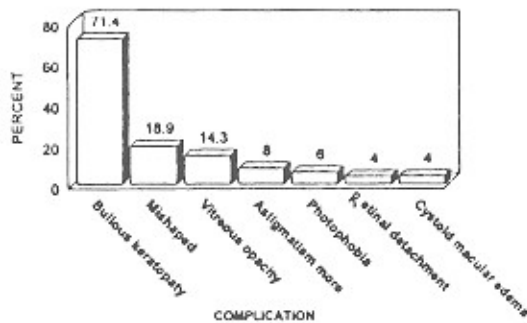


Fig. 3. Distribution of post operative ocular complications of the eyes with operative loss of vitreous during ECCE + IOL in Rasoul Akram Hospital Tehran Nov. 1998.

DISCUSSION

The results of this study show a 6.7% chance of intraoperative vitreous loss during ECCE, which is two times greater, than that suggested by Jaffe(1). He believes that because of improvement of surgical instrumentation, training, technique procedures and facilities the incidence of vitreous loss should be less than 3% .

Our results are obtained from a medical center where residents conducted ECCE with can-opener capsulotomy and manual nucleus delivery and cortical aspiration. At present, there is no previous data in Iran to compare our results with but the results achieved are acceptable in comparison with reports from training centers that are using more advanced facilities. Smith and Seiff (5) reported the incidence at 16% by first year residents, 10% by second year residents and 6% by third year residents. Thomas and et al(6) reported a 10% chance of vitreous loss in ECCE by phaco-emulsification in a resident training center. Therefore the incidence rate of our study is not far

from the other studies. The incidence of cataract is not different in the left or right eye but the chance of vitreous loss in the left eyes was at 63.3% and in the right eyes 36.7%, which shows a statistically significant difference. To our knowledge this is the first time that a difference is reported in the eyes. We assume that the reason for this is that most surgeons are right handed and therefore handling the right eye of the patient being less prominent on the right temporal orbit making it much easier to operate in comparison to the left temporal orbit where surgical manipulations should be performed through the buldgest mid-orbit especially in sunken eyes. With these findings it is suggested that the left eye is a higher risk factor in comparison to the right eye and need shifting to the temporal approach in sunken eyes. It is recommended that a study for comparison of vitreous loss in both eyes using controlled cases by one surgeon is needed to rule out risk factors and to confirm the high risks for the left eyes. Intraoperative vitreous loss occurred in 57.2% of the cases during manual nucleus delivery, during the course of aspiration of cortical material it occurred 36.7% and during intraocular lens implantation and subsequent manipulations (6%). GaoY(7) reported in 1996 in 757 eyes with senile cataract operation a 6.7% overall chance of vitreous loss with 33.3% occurring during nucleus expression, 49% during cortical aspiration and 17% during subsequent manipulation which closely relates with our results where most of the vitreous losses occurred during nucleus and cortical manipulation. Except for unexpected damage to the posterior capsule, the main factors for occurrence of this complication are due to small incision for the nucleus delivery, lens dislocation during capsulotomy, small pupil in the course of cortex aspiration and the high pressure from posterior and tractions on capsular tag on removing the cortex. The can-opener technique of capsulotomy has been performed on all of the eyes in this report. Although it seems that in continuous circular capsulorhexis (?CC)(8) or the envelope technique(9, 10) the chance of capsular tear extension to the posterior will be less. A case controlled study would be quite helpful in determining this issue.

Of the forty-nine eyes that had vitreous loss five eyes had pseudoexfoliation syndrome (PXF) which showed the incidence to be two times greater than those who didn't have PXF. This is a usual finding in PXF due to poor pupillary dilation and the high chance of zonular rupture during surgical manipulation. Vitreous loss in PKF patients seemed to be five times more as reported by Scott(11). Scorilli L.(12) has reported that the chance of vitreous loss is 5.1 times greater in PXF eyes as compared to when it is not present. Although the number of our patients with PXF is low and the high risk patients have not been separated from the others it has been determined that

eyes with PXF have a higher risk of vitreous loss. We suggest a prospective randomized clinical trial to evaluate the risk factors in Iranian patients. Corneal edema was the most common ocular complication of vitreous loss, which was 85%. It is suggested that the limbal approach of the anterior vitrectomy could cause more damage to the cornea and iris. This could be an explanation for the high occurrence of corneal edema, which is at 85%. We suggest closing the wound and doing pars plana vitrectomy(13) to keep the instruments away from the cornea and the iris to decrease the chance of post-operative chronic inflammation and corneal edema. Astigmatism of more than 3 diopters, which was at 8.1%, is due to the number of sutures and an increase in the tightness of the sutures. Unpredictability of the healing of the wound and the unstable state of the cornea in the case of vitreous incarceration of the wound were other factors considered. Foreign body sensation and photophobia in 6.1% of the eyes with vitreous loss could be due to misshaped pupil and chronic uveitis due to more manipulation of the eye and wound during handling of incarcerated vitreous strand that could be decreased by pars plana technique of vitrectomy. This is a retrospective study with its shortcomings. We suggest that prospective case control studies be done to examine large series of ECCE to determine the risk factors for posterior capsule rupture and vitreous loss and its long term complications in order to decrease this preventable complication.

REFERENCES

1. Jaffe NS. Cataract surgery and its complications 5th edition 1990 C.V. Mosby, 341-358, 434-450;1990.
2. Vial D. After results of vitreous loss. *Am J Ophthalmol*, 59: 537-586; 1963.
3. Barraquer I. Trautman RC. Rutlan J. Surgery of the Anterior segment of the eye. New York McGraw-Hill Inc. 204, 281; 1964.
4. Chitikara DK. Smerdon DL. Risk factors, complication and results in extracapsular cataract extraction. *J. Cataract and Refractive Surg.* 23(4): 570-4; 1997.
5. Smith JR. Seiff SR. Outcomes of cataract surgery by resident at a public county hospital. *Am J Ophthalmol* April 123(4): 448-54; 1997.
6. Thomas R. Naveen S. Jacob A. Braganaz A. Visual outcomes and complications of residents learning phacoemulsification. *Indian J. Ophthalmol.* Dec. 45(4): 215-19; 1997.
7. Gao Y. Chen T. Zhao S. An analysis of posterior capsular rupture in cataract surgery. *Asio Pacific J Ophthaimol* May 39(3): 200-2; 1996.
8. Gimbel KY. Neuhann T. Development, advantages and methods of continous circular capsulorhexis technique. *J. Cataract Surg* 16: 3 1-7; 1990.
9. Baikoff G. Insertion of the simco posterior chamber lens into the capsular bag. *Am J Intraocular Implan. Soc.* 7: 267; 1981.
10. Apple DJ. Intracapsular implantation of various posterior chamber IOLS: Animal test results. *Ophthalmic Practice* 5(3): 100-7; 1987.
11. Scott Y. Pseudoexfoliation syndrome and extracapsular cataract extraction. *Acta Ophthalmol Copenh* Dec. 71(6): 765-770; 1993.
12. Scorolli L. Campos EC Bassein L. Meduri RA. Pseudoexfoliation syndrome: Cohort study on intraoperative complications in cataract surgery. *Ophthalmology* 212(4) 278-80; 1998.
13. Gonvers M. New approach to managing vitreous loss and dislocated lens fragments during phacoemulsification. *J. Cataract Refrac. Surg.* 20(3): 340-9; 1994.