

WRESTLING INDUCED CERVICAL SPONDYLOSIS, FACT OR FICTION? A STUDY CONDUCTED IN 148 ATHLETES

SA. Fakhr Tabatabai¹, Z. Hussain Khan¹ and B. Nabaei²

1) Department of Neurosurgery, Imam Khomeini Hospital, School of Medicine, Tehran University of Medical Sciences, Tehran, Iran

2) Department of Social Medicine, School of Medicine, Tehran University of Medical Sciences, Tehran, Iran

Abstract - Traumatic injuries are leading causes of spinal cord damage. The purpose of this study was to evaluate whether wrestling induced cervical spondylosis amongst professional wrestlers or not. To test this assumption, two groups of athletes, 72 wrestlers versus 76 non-wrestlers 15-55 years of age were studied. Radiographic findings and clinical assessments were compared in both groups. Significant differences (Odds ratio = 2.91, $P = 0.007$) were noted between the two groups regarding the prevalence of radiological cervical spondylosis. The clinical radiculo-myelopathy was significantly developing in wrestlers in higher ages (Odds ratio = 77.5, $P < 0.001$). Torg ratio of $< 80\%$ was found to be somehow more in the younger age group. Considering the awesome and debilitating implications of this entity among professional wrestlers, it seems prudent to keep an eye on the cervical spine of all new entrants and closely follow up the professional wrestlers to prevent developing myelopathy. *Acta Medica Iranica* 38 (4): 190-195; 2000

Key Words: Cervical spondylosis, professional wrestlers, radiculomyelopathy

INTRODUCTION

Wrestling in Iran can be traced thousands of years back to the reign of the ancient Persian Empire, and it continues to be the most favorite sport even today. It is as popular with Iranian as cricket is with the British and rugby with the Americans. Ferdowsi, a renowned Iranian poet notifies in his voluminous book, *Shahnameh* (1) to the wrestling between Rostam and Sohrab (Fig. 1).

Cervical spondylosis (CS) defined as a degenerative process of the spine is frequently seen in the lower cervical segments. After the fifth decade of life, a definite enhancement of degenerative process is seen in structures of the vertebrae (2). Fibrosis and osteophyte around the disc are formed for stabilizing the joints (3,4,5). It has been suggested that over use can exacerbate the process of CS.

Repetitive flexion-extension movement in rabbit led to premature CS confirming this hypothesis (6,7). Considering the role of sport in CS, two factors seem involved namely; movement of the neck and aging (8).

CS eventually leads to myelopathy and radiculopathy (3,4,10). Cervical myelopathy (CM) is thought to stem from spinal canal stenosis, osteophyte and relatively excessive mobility (4,10).

Flexion and extension of the neck bring about changes in the spinal canal diameter frequently seen in wrestlers (8). Increased movement of the cervical spine and vertebral joints cause a high incidence of degeneration and CS at the cervical segments (3), likewise superimposition of CS on a previously stenosed canal leads to CM (2), and aging is also incriminated to cause spondylosis (11).

Regarding the relatively high incidence of cervical problems in professional wrestlers, the present study is conducted to test the hypothesis whether there exists a correlation between CM and wrestling in professional wrestlers or not.

METHODS AND CASES

In this case control study 72 male wrestlers, 15-55 years of age were randomly selected from active professional wrestlers introduced by National Wrestling Federation. They were evaluated against 76 non-wrestlers athletes (distance runners) of the same age. Clinical and radiological assessments were carried out and recorded in both groups.

In order to clinch cervical radiculomyelopathy, a thorough clinical evaluation and neurological assessment were carried out in all cases. Radiographic changes such as the presence of osteophyte, disc space narrowing and canal stenosis were evaluated in both groups by an experienced radiologist. All the cases enrolled in the study had lateral cervical plain X-rays, however those in whom clinical signs or radiological findings favoured the presence of CM or CS, magnetic resonance (MR) studies were conducted to confirm the clinical picture (Fig. 3). The ratio "sagittal" diameter of the canal to that of adjacent vertebral body (Torg ratio = TR) is said to be normally 1/1 (12). In some instances where osteophytes posed a hurdle, in the exact measurement, confirmation of canals diameter was achieved with the help of CT Scan. TR was compared between the two groups.



Fig. 1. Wrestling between Rostam and Sohrab, the two legendary wrestlers in ancient persia.

RESULTS

Clinical and radiological findings of 72 wrestlers and 76 non-wrestlers are summarized (Table 1).

The clinical signs of CS increase in both groups with the advancing age. According to Logistic regression

Table 1. The summary statistics findings in wrestlers and non-wrestlers

Age groups	Wrestlers					Non-wrestlers				
	TR<0.8	CS changes		+CM	Total	TR<0.8	CS changes		+CM	Total
	N*	N	N	N	N	N	N	N	N	N
	(%)**	(%)	(%)	(%)	(%)	(%)	(%)	(%)	(%)	(%)
15-24	9	27	5	1	32	3	29	1	1	30
	(28)	(84)	(16)	(3)	(100)	(10)	(97)	(3)	(3)	(100)
25-34	9	18	7	5	25	2	23	4	1	27
	(36)	(72)	(28)	(20)	(100)	(6)	(85)	(15)	(4)	(100)
35-44	2	2	6	5	8	1	6	4	1	10
	(25)	(25)	(75)	(62)	(100)	(10)	(60)	(40)	(10)	(100)
45-54	1	1	6	5	7	2	6	3	1	9
	(14)	(14)	(86)	(71)	(100)	(22)	(67)	(33)	(11)	(100)
Total	21	48	24	16	72	8	64	12	4	76
	(29)	(67)	(33)	(22)	(100)	(11)	(84)	(16)	(5)	(100)

* Frequency

** Percent

Table 2. Analysis for Linear trend in proportion of CS amongst Wrestlers and Non-wrestler

Age groups	Odd ratio			Confidence interval
	Wrestlers	Non-wrestlers	Wrestlers/Non-wrestler	
15-24	1	1	1	0.1-16.2
25-34	7.75	1.25	5.75	0.6-53.4
35-44	51.64	3	15	1.2-185.2
45-54	77.50	3.33	20	1.4-282.5
Total	P < 0.001	P < 0.32	6.96	1.9-25

analysis, the augmentation demonstrated was not significant in non-wrestlers but was significant in wrestlers with an Odds ratio of 77.5 ($P = 0.007$).

Comparing the wrestlers to non-wrestlers in different age groups the development of CM become significant from age 35 and shows a 20 fold increase (Table 2).

Likewise, TR < 80% was more frequent in age group 15-24 and 25-34.

The aforementioned findings are clarified and further illustrated (Fig. 2).

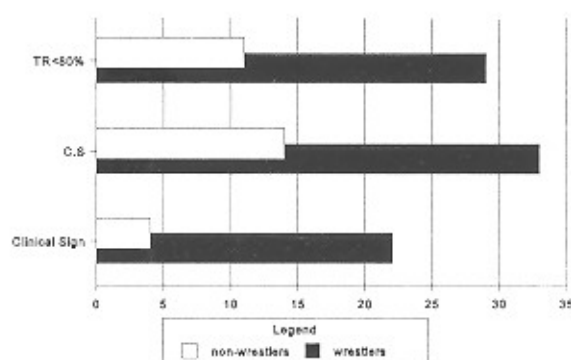


Fig. 2. The prevalence of TR < 80, CS and clinical signs in wrestlers and non-wrestlers.

DISCUSSION

We reasoned that CM could be an aftermath of wrestling and thus hypothesized that wrestling could have a direct bearing and an impact on CM in individuals exposed to abnormal positions in this type of sport. To assess this assumption, we conducted a battery of clinical, radiological, MRI and CT Scan studies in the population under study.

This study demonstrated that the experimental indices utilized proved sensitive measures in predicting CM. Our findings point towards a significant difference in those between the fourth and fifth decades of their life. Although it has been stated that athletes often have abnormal large vertebral bodies (13), nevertheless sportsmen with TR < 80% are probably predisposed to cervical spinal cord damage and developing CM (12).

In our study, TR < 0.8 was more frequent in age group 15-24 and 24-35 (Table 1), but no other evidence of CS could be found either clinically or radiologically and perhaps the decreased TR was an incidental finding.

The prevalence of CS increases with advancing age, and repetitive jogging and twisting movement of the neck. Chronic ring apophyseal injuries due to wrestling have been mentioned in thoracic and lumbar spine (2). However in wrestling many a time a special position called bridge, colloquially termed poll (Fig. 4)

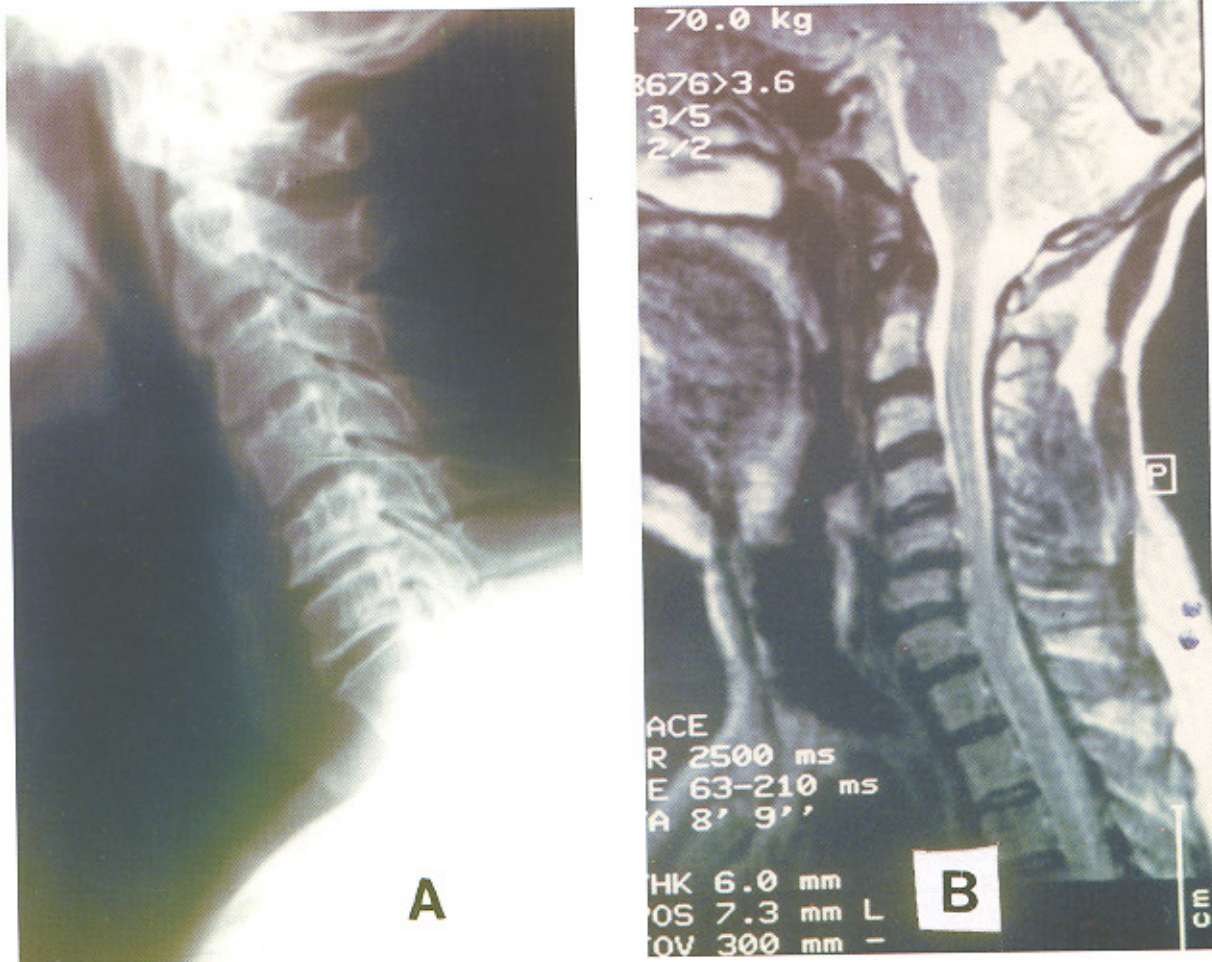


Fig. 3. Lateral cervical radiogram (A) and MRI (B) of a 52 year old wrestler with 31 years history of wrestling

is adopted by one of the competitors under the duress of circumstances during the wrestling bout. This hyperextended neck posture imparts the maximum strain to the posterior longitudinal ligament, which is further transmitted to the tectorial membrane. Despite the fact that the posterior longitudinal ligament is much thinner than the anterior longitudinal ligament and both are weaker in the cervical region than in the thoracic and lumbar spine (6), the strong muscular structure of these wrestlers help to overcome this anatomical weakness. At times, the incredible weight transmitted to the cervical spine during this highly vulnerable posture not only causes shearing of the ligaments but also causes extensive trauma to the intervertebral disc space and thereby brings a flourishing career to an end.

During training, such positions are commonly

adopted and if repeated for long periods can initiate the debilitating process of CS in these aspiring young wrestlers. The nature and type of sport does have a profound impact on the overall safety of the sportsmen. For instance, roentgenograms of the cervical spine in high cliff divers failed to reveal any abnormality although they were exposed to persistent neck trauma (14).

CS is a degenerative process of the cervical spine (3-5) and after the fifth decade of life these changes are also seen in the structures of body (15). Cervical injuries often encountered as a result of participation in sport by young impetuous people were due to causes such as inadequate supervision, motivation to attempt tasks beyond their abilities and a mismatch between the abilities of the performer and the tasks attempted (16).

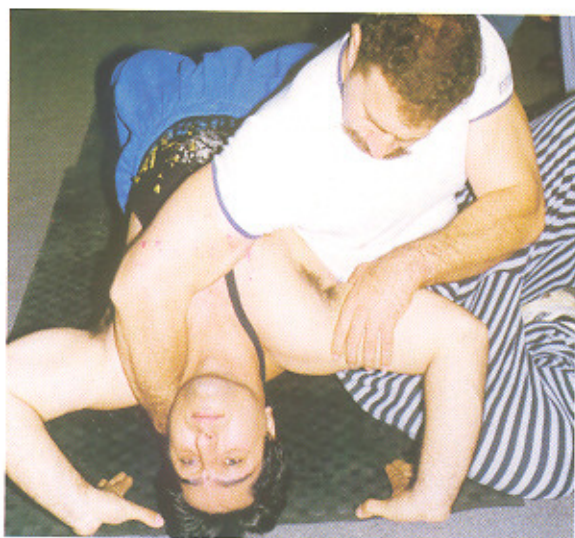

Fig. 4. The unnatural and vulnerable posture of bridge during wrestling.

It seems conceivable that wrestling induced augmented movements of the neck and repetitive strains in the form of micro or macro trauma in special position that accompany this sport can expedite the process of CS. It is increasingly clear that future therapies of wrestlers prone to develop CS will be multifaceted combining physical education, and surgery tailored to counteract the ongoing and slow pathological events.

In this study, significant differences between two groups were found (Table 2). It appears prudent to keep a close watch on these sportmen and conduct X-rays, CT or MR in circumstances where the need dictates. The fact that many cases of incomplete or impending CS can be anticipated and timely diagnosed emphasizes the need for a more active prophylactic role in everyday life in the form of close surveillance and thorough scrutiny.

In other sports such as boxing, karate and sword fighting etc, protective measures in the form of face covers, gloves and other bracings enable the competitors to tolerate the kicks, fists and thereby ward off accidents to a considerable extent, but unfortunately in a sport like wrestling such is not the case. We feel that certain positions like bridge can jeopardize the wrestlers career or at times bring an incalculable harm to their life. We further are of the opinion that the need for standardization of the technique of wrestling should perhaps pave the way for less episodes of CS and CM and other insults in these highly susceptible sportmen.

In conclusion, in wrestling although the rules of the sport are observed but they need a second look so that untoward accidents and longterm sequelae are prevented.

REFERENCES

1. Ferdowsi HA. Wrestling between Rostam and Sohrab, Calligraphy In: Ferdowsi (ed). Shahnameh. Tehran 1006; 42.
2. Sward L, Hellstrom M, Jacobson B, and Karlsson L. Vertebral ring apophysis injury in athletes. Is the etiology different in the thoracic and lumbar spine? *Amer J Sports Med.* 1993; 21: 841-5.
3. Neck DW. Cervical spondylosis: clinical findings & treatment. *Contemporary Neurosurgery.* 3: 1-6; 1991.
4. Hoff JT. Cervical disc disease and cervical spondylosis. In: Wilkins RH, Rengachary SS (eds). *Neurosurgery.* New York: McGraw-Hill Co. 1985; 2230-39.
5. Tarlov EC. Extradural spinal cord and nerve root compression from lesions of the cervical area and their management by the posterior approach. In: Youmans JR (ed). *Neurological surgery.* Philadelphia: WB Saunders Co. 2241-52; 1996.
6. Lorish TR, Rizzo JD Jr, Ilstrup DM, and Scot SG. Injuries in adolescent and preadolescent body at two large wrestling tournaments. *Amer J Sports Med.* 20: 199-202; 1992.
7. Pentore R, Nickelli P. Deafferented state syndrome (Locked-in-synd) following sudden cervical sprain trauma during a karate training session. *Riv Neurol.* 61: 660-70; 1991.
8. Cusick JF, Myklebust JB. Biomechanics of cervical spondylotic myelopathy. *Contemporary Neurosurgery.* 9: 1-7; 1987.
9. Pemeczy G, Bock FW, Neuhold A, and Stiskal M. Diagnosis of cervical disc disease. MRI versus clinical myelopathy. *Acta Neurochirurgica Wien.* 116: 44-48; 1992.
10. Saunders RL, Bernini PM, Shirreffs TG, and Reeves AG. Central corpectomy for cervical spondylotic myelopathy, a consecutive series with long term follow up evaluation. *J Neurosurgery.* 74: 163-70; 1991.
11. Menard D, Stanish WD. The aging athlete. *Amer J Sport Med.* 17: 187-196; 1989.
12. Odor JM, Watkins RG, Dillin WH, Dennis S, and Saberi M. Incidence of cervical spinal stenosis in professional and rockie football players. *Amer J Sport Med.* 18: 507-9; 1990.
13. Herzog RJ, Weins JJ, Dillingham MF, and Sontag MJ. Cervical spine morphometry & cervical spine stenosis in asymptomatic professional football players. Plain film radiography, CT and MR imaging. *Spine.* 16 (6 suppl): S178-86; 1991.

14. Schneider RC, Papo M, Michigan AA, and Alvarez CS. The effect of chronic recurrent trauma in high diving. *J Bone Joint Surg.* 44-A; 648-56; 1962.

15. Simeone FA, Dillin WA. Treatment of cervical disc disease. selection of operative approach. *Contemporary Neurosurgery.* 8; 1-6; 1986.

16. Silver JR. Spinal injuries in the UK. *Br J Sports Med.* 27: 115-20; 1993.