

TRANSCATHETER ABLATION OF THE POSTEROSEPTAL ACCESSORY PATHWAYS

M. Moghaddam and A. Yamini Sharif

Department of Cardiology, Shariati Hospital, School of Medicine, Tehran University of Medical Sciences, Tehran, Iran

Abstract - Transcatheter ablation of atrioventricular accessory pathway is the therapy of choice in symptomatic patients. The ablation of posteroseptal accessory pathways has some important points due to its anatomical location. Catheter ablation of posteroseptal accessory pathways via left side approach is time consuming with low success rate and higher complications. We performed successful transcatheter radiofrequency ablation of posteroseptal accessory pathways in 25 patients. This was done via right atrial approach in 23 cases and left side approach in 2 cases.

Acta Medica Iranica 38 (4): 235-237; 2000

Key Words: Accessory pathway, posteroseptal, radiofrequency, catheter ablation, coronary sinus (C.S)

INTRODUCTION

The posteroseptal region of the heart is anatomically located between the posterior-superior process of the left ventricle and inferior wall of the right atrium (1,3,4). Due to the close proximity of the posteroseptal region to atrioventricular (AV) node and its artery, initial surgical intervention were accompanied with low success rate and high incidence of complete AV block. Later transcatheter ablation of accessory pathway (AP) using direct current electrical shock and recently radiofrequency (RF) energy provide a safer and more effective source of energy. The posteroseptal (PS) area of the heart correspond to a region known as the crux, where the four chambers of the heart reach their maximal proximity posteriorly (Fig. 1). In the crux region the right atrium and coronary sinus (CS) form a unit which wraps around left atrium. The interatrial sulcus and the right AV sulcus is located below that of the left AV sulcus (3,5,6).

This anatomical structure allows right atrium to lie directly on the posterior superior process of the left ventricle (3). Also, the PS region is divided into three distinct anatomical parts (1,4,7,8):

- 1- Mid septal (anterior-superior border).
- 2- Right posteroseptal (right lateral border).

3- Left posteroseptal (left lateral border) (Fig. 2).

Based on surface ECG manifestation and electrophysiological findings the PS-APs have been categorized into right sided, left sided and midseptal ones (2). The purpose of this article is to say that catheter ablation of PS-APs is feasible with right atrial approach in spite of electrocardiographic or electrophysiologic findings that guides us to a left sided or mid septal ones.

MATERIALS AND METHODS

26 patients aged 11-62 years with documented frequent episodes of paroxysmal supraventricular tachycardia underwent electrophysiological study 11 cases had manifest preexcitation. They were categorized in three groups:

Group I: 5 patients, with positive delta in V1, negative delta in II, III, aVF.

Group II: 4 patients, with negative delta in V1, negative delta in II, III, aVF.

Group III: 2 patients, with negative delta in V1 and normal axis (9). In all patients of groups II and III there was a positive delta in V2. In 15 cases with concealed AP during orthodromic atrioventricular tachycardia (AVRT) or ventricular pacing the earliest site of retrograde atrial activation was right posterolateral (7 cases), ostium of CS (3 cases), about one centimeter inside CS (2 cases), middle cardiac vein (1 case), midseptal (2 cases).

The RF energy was delivered to the earliest point of atrial activation during ventriculo-atrial (V-A) conduction in 21 cases for 30+10 seconds. In some patients with manifest delta wave unipolar lead was studied; in those the site of RF energy delivery was a high deflection preceding the onset of QRS during sinus rhythm (5).

In case of success, the RF current was continued for 30 + 10 seconds. The procedure was repeated one or two times for safety lesions induction. Starting RF current was 10 watts and raised up to 35 + 10 watts gradually.

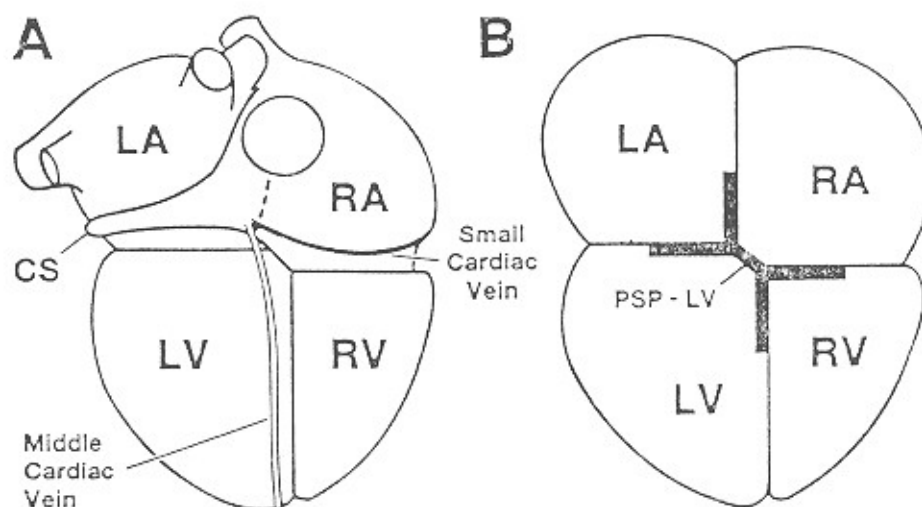


Fig. 1. The crux of the heart. The posterior aspects of the heart are shown schematically. The right atrium (RA) and the coronary sinus (CS) form a unit that wraps around the left atrium (LA). The posterior interventricular (middle cardiac) vein and the small cardiac vein join the terminal coronary sinus. Note also that the interatrial sulcus is situated to the far left of the interventricular sulcus and the right AV sulcus is markedly depressed below that of the left. This allows the right atrium to lie directly over the posterior-superior process (PSP) of the left ventricle (LV). The greater the depression of the tricuspid annulus below the mitral annulus, the larger the posterior-superior process of the left ventricle. RV=right ventricle. (Reproduced with permission from M.R. Jazayeri, Masood Akhtar, et al. *Posteroseptal Accessory pathways. Journal of Interventional cardiology, Vol 8, No. 1, Feb 1995*).

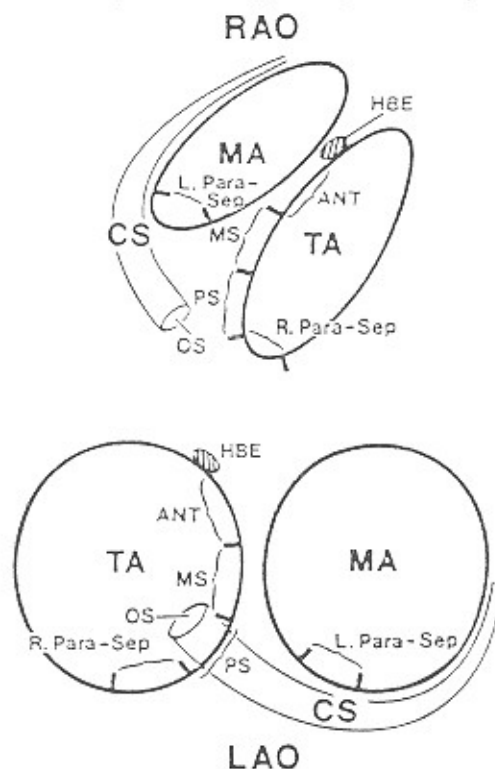


Fig. 2. Radiographic views of the posteroseptal region. These schemata represent right and left anterior oblique (RAO and LAO, respectively) views of the mitral and tricuspid annuli (MA and TA, respectively). The septal annulus of the tricuspid valve extending from the coronary sinus (CS) ostium (OS) to the site of recording of the His-bundle electrogram (HBE) is divided into the posteroseptal (PS), mid-septal (MS), and anterior (ANT) regions. Note that the posteroseptal region is surrounded by mid-septal, right paraseptal (R. Para-sep), and left paraseptal (L. para-sep) areas. (Reproduced with permission from M.R. Jazayeri, Masood Akhtar, et al. (*Posteroseptal Accessory pathways, Journal of Interventional cardiology, Vol 8, No. 1, Feb 1995*).

RESULTS

Posteroseptal AP catheter ablation was successfully performed in 25 patients. The end point was increased V-A conduction time, no arrhythmia induction in the patients with concealed AP, and disappearance of delta wave in addition to previous criteria in patients with manifest AP. The success rate was 96% in 26 patients. This was achieved via right side approach in 23 patients (88%) via left side approach in two cases (7.70%); in one case both side approaches were unsuccessful.

Table 1. RF energy catheter ablation of PS-AP

	No. of patients	right side approach	left side approach	total success rate
Jackman	65	77%	23%	92%
Schulter	21	81%	19%	80%
Chalkin	44	78%	22%	93%
Jazayeri	50	96%	4%	98%

DISCUSSION

Our results are in accordance with prior studies that right side approach is the preferred method to ablate the PS-AP (1,10,11,12).

The previous studies are shown in table 1.

The posteroseptal area of the heart is among the most complex areas of the heart which harbor the APs and a firm grasp of anatomical characteristics of this region can facilitate a successful AP catheter ablation (1,3,7). Because of the oblique atrioventricular connection of APs and also their width, many manifest PS-AP may have surface ECG characteristics of left sided AP but actually their atrial connection sites be in right atrium around ostium or inside CS, and mid septal region.

So thorough electrophysiologic study is necessary to find the exact site of AP RF energy delivery to the target point, after identification of the best site to ablate the AP thoroughly and cure arrhythmia permanently.

Because most sites of PS-AP locations like right paraseptal, ostium or inside of CS and mid septal regions are accessible via right side approach, it is recommended to try this approach first to ablate the PS-AP. Also RF energy is preferred to the other sources of energy like direct current shock because of

its quantitation, the capability of small size lesion induction and lower rate of complications.

REFERENCES

1. Jazayeri M.R., Akhtar M. Posteroseptal accessory pathways. *J. Interv. Car.* 8:89-101; 1995.
2. Oren J.W., Jackman W.M. A functional approach to the preexcitation syndromes. *Card. Clinics.* 11: 1:121-149; 1993.
3. Dhala A., Deshpande S. Transcatheter ablation of posteroseptal accessory pathway using a venous approach and RF energy. *Circ.* 90: 1799-1810; 1994.
4. Zipes and Jalife: *Cardiac Electrophysiology*, 2nd edition. W.B Saunders Co. 1995; 1080-1089.
5. Antz M., Otomo K., Jackman W.M. Electrical conduction between the right atrium and left atrium via the musculature of the coronary sinus. *Circ.* 98: 1790-95; 1998.
6. Shinbane J.S., Lesh M.D. Anatomic and electrophysiologic relation between coronary sinus and mitral annulus. *Am. Heart. J.* 135: 93-98; 1998.
7. Tai Tai C., Chen S.A. Characteristics and RF catheter ablation of septal accessory atrioventricular pathways. *PACE* 22: 500-511.
8. Josephson Mark E. *Clinical cardiac Electrophysiology*, 2nd edition. Lea and Febiger, 1993; 729-744.
9. Braunwald Eugene. *Heart Disease*, 5th edition. W.B. Saunders. 1997, 621-622.
10. Jackman W.M., Wan X., et al. Site of successful radiofrequency ablation of PS-AP. *PACE* 15: 535, 1992.
11. Schulte M., Geiger M., et al. Catheter ablation using RF current to cure symptomatic patients with tachyarrhythmias related to an atrioventricular pathway. *Circ.* 84: 1644-1661, 1991.
12. Calkins H., Langberg J., et al. RF catheter ablation of accessory atrioventricular connection in 250 patients. *Circ* 85: 1337-1346, 1992.