

THUMB CARPOMETACARPAL JOINT VOLAR DISLOCATION: A CASE REPORT

M. Farzan, M. Siassi and R. Espandar

Department of Orthopedic surgery, Imam Khomeini Hospital, School of Medicine, Tehran University of Medical Sciences, Tehran, Iran

Abstract: *Dislocation of the thumb carpometacarpal joint is a rare injury, and only 38 cases have been definitively described in the English-speaking literature. All the reported dislocations have been dorsal. We present a volar form of the thumb carpometacarpal dislocation which was managed surgically after three months from the injury with open reduction and volar ligament reconstruction, with satisfactory outcome.*
Acta Medica Iranica: 40(1): 52-54; 2002

Key words: *Hand traumas, volar dislocation of thumb carpometacarpal joint*

INTRODUCTION

Although thumb carpometacarpal (CMC) dislocations are rare, due to the importance of thumb in providing about 40% of hand function, their rarity will not decrease the importance of them. All the reported dislocations in literature have been dorsal but here, we present a volar form of the dislocation (1-3).

CASE REPORT:

Three months after direct trauma to dorsoradial aspect of the dominant hand of a 17 years old male, he was referred to our center because of pain, deformity and severe limitation of thumb's motion. The patient was unable to pinch and perform opposition. The roentgenograms were reviewed carefully, and PA and lateral views of the thumb carpometacarpal (Fig. 1) and lateral view of both

sides (for comparison) (Fig. 2) were obtained. An undiagnosed volar dislocation of thumb carpometacarpal along with a healed fracture at the second metacarpal base were present.

Due to the age of the patient, severe functional disability of his dominant hand and an unsuccessful closed reduction, the patient had been a candidate for open reduction of the joint. Possible need for arthrodesis was described to the patient and his family.

RESULTS

Surgical exposure was through a modified Wagner volar approach that curves into the distal wrist flexion crease. The base of the first metacarpal was completely displaced into the thenar muscle mass. Severe fibrosis was present and dorsal ligaments were subperiosteally stripped off the metacarpal base. After mobilization, an open reduction was performed, but direct repair of the joint capsule and volar ligament were virtually impossible, thus surgical reconstruction was done with Eaton and Littler technique.

The joint was stabilized with a 1mm K wire in 20° abduction and 40° flexion (suitable position for first CMC arthrodesis) and a short thumb spica cast was applied. The cast and wire were removed four weeks later, a removable splint was applied, and passive range of motion exercises were started. Six weeks after the operation, stability of the joint was satisfactory enough for more aggressive physiotherapy and occupational therapy.

Four months after the operation although about 10° limitation of motion was present in thumb motions, opposition of the thumb was possible. Strength and power of grip and pinch was near normal in relation to contralateral side and motion was painless (Fig. 3).

Correspondence:

R. Espandar, MD,
Imam Khomeini Hospital, Keshavarz Boulevard, Tehran, Iran.
Tel: +98 (21) 919-2455
FAX: +98 (21) 93-5512
Email: e732495@ic.aku.ac.ir

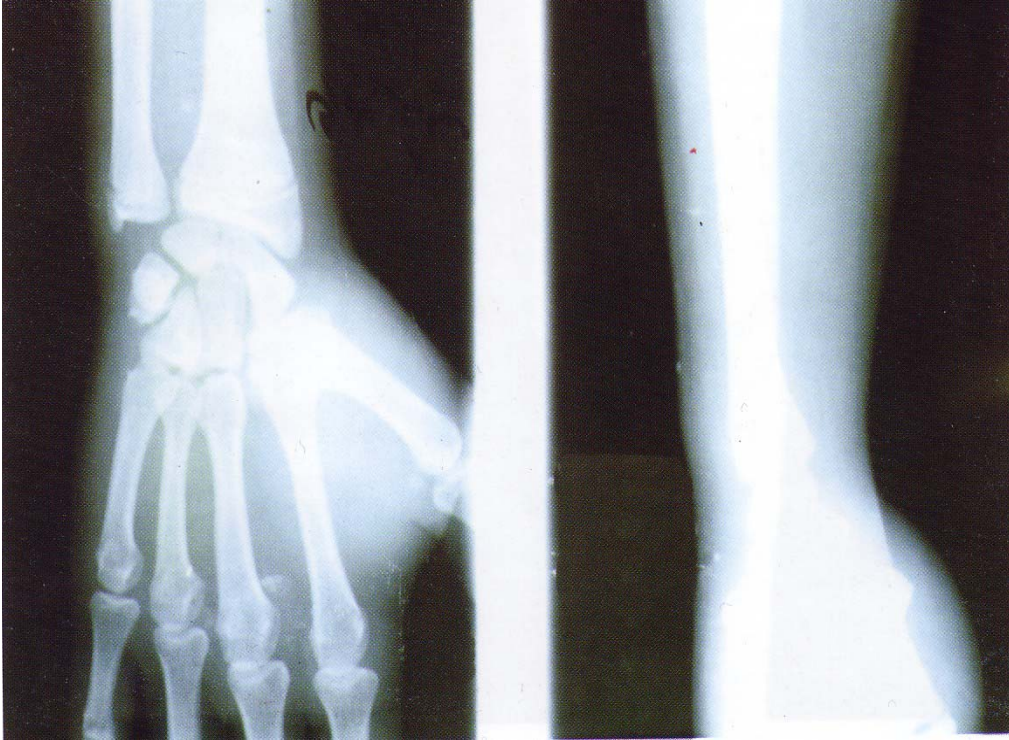

Fig. 1. PA and Lateral view of right hand 3 months after injury.
Volar dislocation of first CMC joint is evident

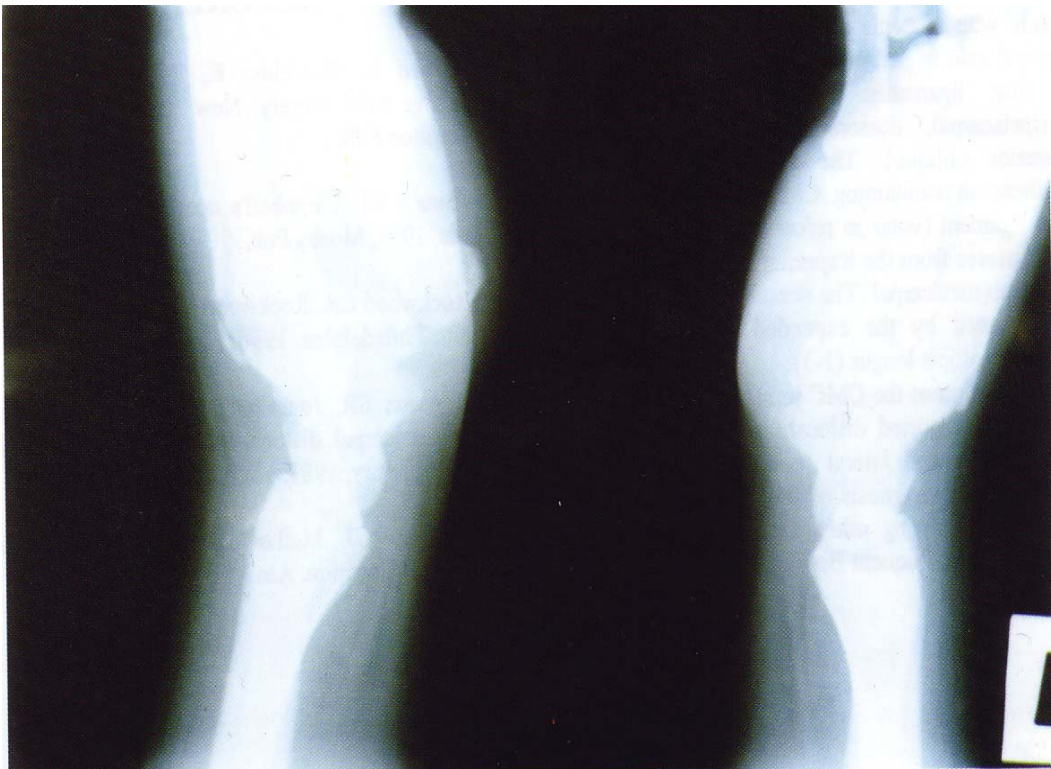


Fig. 2. Lateral view of both hands for comparison.
Volar dislocation of first right CMC joint is present

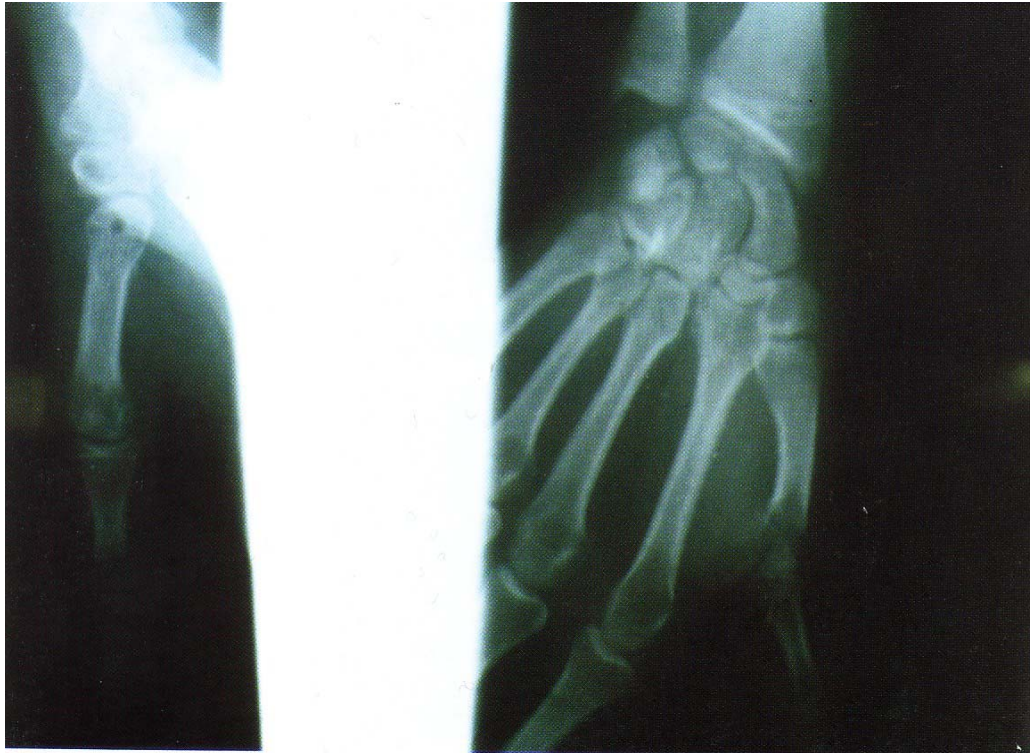

Fig. 3. PA and Lateral views 4 months after operation.
Arrow shows the hole for passage of radial split of flexor carpi radialis tendon.

DISCUSSION

The CMC joint of the thumb is a biconcave saddle, and the joint has little intrinsic stability imparted by its bony architecture alone. The joint capsule with strategic areas of thickening plays the principal role in stabilization. The joint is stabilized by four ligaments: Volar (anterior oblique), intermetacarpal, dorsoradial and dorsal oblique (posterior oblique). The ligament that is most significant in maintaining CMC stability may be the volar ligament (volar in reference to the thumbnail), which passes from the trapezium to the volar neck of the thumb metacarpal. The dorsal ligament is thin but is reinforced by the expanded insertion of the abductor pollicis longus (1-3).

Dislocation of the CMC joint is quite rare and up to now, all reported dislocations have been dorsal. Standard PA and lateral roentgenograms must be taken both for diagnosis of this dislocation and also to rule out existing other joint pathology and the relatively more frequent Bennett fracture-dislocation.

Widening of the joint space may be apparent on these routine roentgenograms (4-5).

REFERENCES

1. Green D, Hotchkiss R, Pederson W. Green's operative hand surgery, New York, 1999, Churchill Livingstone Pub.
2. Canale ST. Campbell's operative orthopedics, St. Louis, 1998, Mosby Pub.
3. Rockwood CA. Rockwood and Green's fractures in adults, Philadelphia, 1996; Lippincott-Raven Prb.
4. Jognson SR, Jones DG, Hoddinott HC. Missed carpometacarpal dislocation of the thumb in motor cyclists. *Injury*, 1987; 18: 415-6.
5. Wagner CJ. Method of treatment of Bennett's fracture dislocation. *Am J Surg*, 1950; 80: 230.