

A STEREOLOGICAL ANALYSIS OF RENAL GLOMERULI FOLLOWING CHRONIC LEAD INTOXICATION IN RAT DURING A CONTINUOUS PERIOD OF 8 WEEKS

Z. Heidari¹, H.R. Mahmoudzadeh Sagheb¹, A. R. Dezfoulian¹, M. Barbarestani² and S.M.H. Noori²

1) Department of Histology, Zahedan University of Medical Sciences, Zahedan, Iran

2) Department of Histology, Tehran University of Medical Sciences, Tehran, Iran

Abstract- Stereologic methods are used to obtain quantitative information about 3-dimensional structures from histologic sections. The aim of the present study was using new and unbiased stereologic techniques to investigate changes in volume and number of glomeruli after chronic lead acetate intoxication both quantitatively and in 3-dimensional spaces.

Lead is one of the heavy metals that has adverse effects on renal function. These effects may involve the renal tubules as well as the glomeruli. Several qualitative histologic studies have been performed regarding the effects of lead on renal tissue and the glomeruli, some of which report changes in volume and number of the glomeruli.

Male adult Wistar rats in four groups (each including 9 rats) were randomly selected. The case groups (treatment groups) were first given 0.5% and then 1% lead acetate in their drinking water for 8 weeks. The negative and positive control groups were given distilled water and 0.4% acetic acid solution in the same period respectively.

Stereologic analysis was performed based on Cavalieri's principle to determine the reference volume ($V_{Reference}$), the fraction volume of glomeruli ($V_{V_{Glom}}$), and total glomerular volume ($V_{T_{Glom}}$). Furthermore the numerical density ($N_{V_{Glom}}$) and total number of glomeruli ($N_{T_{Glom}}$) were estimated using the physical disector.

Results showed that the number of glomeruli in case group which had received 1% lead acetate in drinking water decreased significantly ($P < 0.05$), but no changes occurred in 0.5% group ($P > 0.05$). On the other hand, glomerular total volume in both 1% and 0.5% groups increased significantly after lead intoxication comparing positive and negative control groups ($P < 0.01$).

This study confirms qualitative observational histologic studies with an unbiased and exact method, and expresses the changes in the number and volume of renal glomeruli after lead intoxication.

Acta Medica Iranica: 40(2): 73-78 ; 2002

Key Words: Stereology, glomerulus, kidney, lead acetate, intoxication.

Correspondence:

H.R.Mahmoudzadeh Sagheb, Department of Histology, Zahedan University of Medical Sciences, Zahedan, Iran

Tel: +98541 3220424

E-mail: histology-iri@yahoo.com

INTRODUCTION

Before 1984, use of stereologic methods to calculate the size and number of particles was based on theories related to their form, size, and virtual 3-dimensional conformation. In other words, a presumed model for the glomerulus was considered (1). Different methods are used to determine the number and volume of the glomeruli, most of which are biased and inefficient. In recent years methods are developed that in contrast with the old ones, which were based on particle separation and counting in independent sections, work upon paired sections basis. The newer ones are unbiased and efficient (2). Volume determination by the use of Cavalieri's principles and disector technique together with the Cavalieri's method makes a direct and unbiased estimation of the number of glomeruli possible (3). Reference volume (cortex volume) and glomerular volume were estimated by the use of Cavalieri's principles in this study. The number of glomeruli was estimated using the physical disector method together with Cavalieri's method as the only unbiased stereologic way. Estimating the number and volume of the glomeruli in different groups, which were given lead acetate, and comparing them with the control ones, we indirectly investigated renal function after chronic lead intoxication.

History of lead intoxication dates back to human civilization. Silver mining in the era of Roman Empire resulted in large amounts of lead exploited together with silver. Lead intoxication at that time must have been through ingestion and using lead pigmented utensils for food transport and delivery (4). Lead is one of the heavy metals and due to its special features, has widespread usages in human life. Because of the resistance against corrosive materials, it is used for preserving corrosive liquids. Large amounts of lead are used in battery production and in radiation and vibration resistant clothes. Although lead application in the production of dyes and insecticides and adding lead to petrol is forbidden in many countries, it is still used as an additive to petrol in Iran.

In human beings lead is absorbed through the respiratory and gastrointestinal tracts and is

distributed in three main body compartments: blood, bones, and soft tissues such as liver, brain, muscles, and kidneys. GI absorption of lead and its distribution in laboratory animals such as rats is like human beings (5). A common adverse effect of lead includes renal dysfunction and involves both the tubules and renal glomeruli (6). Renal disease occurs as a result of lead intoxication. So different parts of renal tissue such as the glomeruli are involved in different ways. Glomerulosclerosis develops and blood filtration rate consequently decreases (7). Histologic studies in 2-dimensional settings have reported loss of glomeruli and increased volume of the remained ones after chronic lead intoxication (8). Reports are also available on no more changes in the glomeruli except increased glomerular endothelial and mesangial cells following lead intoxication (6). Other qualitative studies based on glomeruli diameter measurements after chronic lead intoxication in lab animals reveal cortical hypertrophy and increased GFR despite no changes in the glomeruli diameter (9).

As excretion of the waste materials produced by metabolism is mainly carried out by filtration and secretion through the glomerular capillaries, it is imperative to estimate that the number and volume of the glomeruli which indirectly point to the filtration surface; therefore the difference in total volume of the glomeruli is considered as an index of total glomerular filtration surface (10). Thus, determining the number and volume of the glomeruli bears much importance in renal function in different renal diseases.

MATERIALS AND METHODS

Male adult Wistar rats in four groups (each including 9 rats) weighing 94±10 g were randomly selected from Razi Institute. All of them lived 12 hours in dark and 12 hours in light under 22±2°C in separated cages. Food and water were made easily available for them. The case groups (treatment groups) were first given 0.5% and then 1% lead acetate in their drinking water. To avoid precipitation, lead acetate was dissolved in a solution of 0.4% acetic acid. The negative and positive control groups were given distilled water and 0.4% acetic acid solution in the same period respectively. Eight weeks later all animals underwent general anesthesia by ether and their kidneys were removed. After dissecting renal capsule, kidneys were kept in the modified Lillie's fixative solution for 72 hours to fixate. A kidney of each animal was then randomly chosen and after bathing in normal saline was molded in 7% agar. Soon after casting the kidney mold was cut in 1mm segments. Therefore the cutter would come into contact with the first renal segment

completely randomly (8). Then except for the first cut that was omitted from the samples, other segments were sent for the usual tissue passage. Paired sections from the paraffin molds with 21-micrometer intervals were prepared by the microtome and stained with H&E (11,12).

Stereology method: To calculate the reference volume (V_{Ref})—in this study the volume of renal cortex—Cavalieri's principles were applied. The first slide in each series of paired sections was selected. Its figure was produced by a microprojector and seen on the table. Then the sample was randomly covered with a transparency of arranged network of points. The points that had met the cortex were counted in all first sections of each kidney. Cortical volume was then determined using the following formula:

$$V = \frac{\sum_{i=1}^m p.a(p).t}{M^2}$$

Where ΣP , is the number of points which crossed the cortex; $a(p)$, is the neighboring zone of each point in the test system, t , is the mean section thickness; and M , is the linear magnification(12, 13). Glomerular volume was calculated in this way: First, glomeruli fraction volume ($V_{V(Glom)}$) was determined using the following formula and arranged network of points:

$$V_{V(glom)} = \frac{\sum_{i=1}^m p(glom)}{\sum_{i=1}^m p(cort)}$$

Where ΣP (glomeruli), is the number of test system points that crossed the glomeruli and ΣP (cortex), is the number of points which crossed the renal cortex. Total glomerular volume was then calculated in this way (14):

$$V_{Total(glomeruli)} = V_{(cortex)} \cdot V_{V(glomeruli)}$$

Counting the number of glomeruli by physical dissector method: Two microprojectors were used in this method. The produced picture of two consecutive control and reference slides was projected on the table at the same time. Linear magnification of 17.7 was reached. Using special dissector grade, 50 visual fields in each kidney was selected by systematic uniform random sampling (SUR) method and glomeruli were counted. In this way, if the profile of the glomerulus was detected in the reference section without detecting it in the look-up section and if the observing glomerulus hadn't crossed the forbidden lines of dissector grade, it was considered for counting; otherwise it was not counted (3). Then using the following formula, numerical density of the glomeruli was calculated:

$$NV = \frac{\Sigma Q}{\frac{a}{f} . h . \Sigma p}$$

Where ΣQ , is the number of the counted glomeruli; ΣP , the number of points and also frames

that crossed the reference space; h, the height of the dissector; and a/f, is the frame area divided by the square of magnification. Each of the dissector frames had a central point; if this point was placed in the reference space, the volume of related dissector would be added too.

To determine total number of the glomeruli, the production of glomerular density and reference volume was reached (1-3):

$$N_{\text{Total}} = N_{\text{Vglomeruli}} \cdot V_{\text{Cortex}}$$

The results of these stereologic equations underwent statistical analysis with intersubjective one way analysis of variance analysis and Tukey (HSD) and Scheffe statistical tests by SPSS 9.0 software. P value of less than 0.05 was considered significant. Results are displayed in terms of Mean \pm SEM.

RESULTS

Our findings show that the mean of total

glomerular volume after 0.5% lead acetate administration for 8 weeks equalled 13.16 ± 0.31 and that the mean glomerular volume in the group, which had been given 1% lead acetate in the same period, was 12.08 ± 0.45 , in the control group, 9.35 ± 0.19 , and in the positive controls, 9.31 ± 0.18 . Significant statistical difference was observed between the case groups and the negative and positive control groups ($P < 0.01$). In the mean time the difference between the two control groups and also between the two administration groups (0.05% vs 1% lead administration) didn't prove to be statistically significant ($P > 0.05$) (Fig. 1).

Total number of glomeruli in those given 1% lead acetate was 29962 ± 339 which had significant difference with the control (mean = 31431 ± 331) and positive control groups (mean = 31376 ± 209) ($P < 0.05$). Total number of glomeruli in those given 0.5% lead acetate was 30092 ± 365 , with no significant difference between this group and the control groups ($P > 0.05$). Regarding the same parameter, no significant difference was met between the two control and case groups ($P > 0.05$) (Fig. 2).




Fig. 1. The effect of lead on renal glomeruli volume in the case groups (Lead acetate administration for 8 weeks) (** $p < 0.01$)

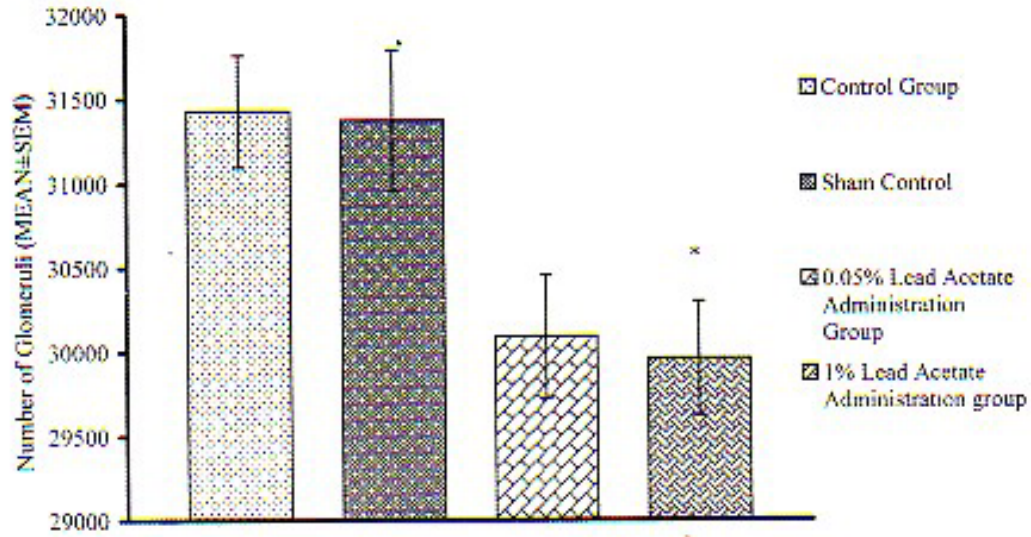


Fig. 2. Number of glomeruli following 8 weeks lead acetate administration (* $p < 0.05$)

DISCUSSION

Lead intoxication is accumulative; it develops gradually yet progressively in human and finally leads to renal failure (15). This study discusses quantitative effects of lead acetate on renal tissue in a laboratory model for a continuous period of 8 weeks. In adult human beings constant contact with lead, especially in the working environment in which lead contact is a concern, causes chronic and progressive renal damage. Interrupting continuous contact with lead only reverses part of the renal damage. Previous studies on laboratory models in regard to lead induced renal damage, demonstrate that the severity of renal injury depends on the duration and amount of lead intoxication (9).

In one study, histopathologic lesions in rat kidneys developed after ingestion of 2% lead acetate in drinking water (16). On the contrary, in the current study all the groups given higher doses of lead acetate (more than 2%) didn't drink lead rich water and died after 14 ± 3 days. It is reported that administration of 0.5% lead acetate for 2 months is not associated with any histologic or renal dysfunc-

tion; however, histologic changes in the proximal convoluted tubules developed following 1% lead acetate administration for 3 months (9). It was also noted that in lithium intoxication glomerular size would change a lot (17). This quantitative study, due to the value of glomeruli in renal function, focuses on the changes in the number and volume of glomeruli following lead intoxication. The amount of renal glomeruli under the influence of 1% lead acetate displays significant differences compared to both of the control groups, while the group which had been given 0.5% lead acetate, didn't disclose such difference. Our findings approve and emphasize the results of the qualitative researches on the significance of the presence of 0.5% and 1% lead acetate in drinking water. In a study it is shown that following administration of 1% lead acetate for 3 months in a lab model, the glomerular filtration rate (GFR) increases and renal hypertrophy and increased renal weight develops but no change in glomerular diameter follows (9,18). In different studies, increased renal weight has been reported following lead intoxication (7). In all of them, this increase in renal weight and renal hypertrophy have been

pertained to changes in the proximal convoluted tubules; yet in contrast to all of these changes, which have been based on direct observation or 2-dimensional measurements, glomerular size and in fact total glomerular volume in our study was determined in 3-dimensional space with the use of stereologic techniques. Studying case (lead acetate administration) and control groups, disclosed significant increase in the glomeruli volume in the group given lead acetate compared to the control groups. In another study on human models, disappearance of a lot of glomeruli with no consequence has been reported and it is emphasized that this is the main feature of chronic lead intoxication. Some of the remaining glomeruli have been enlarged while others maintained their normal sizes. This research was also based on direct observation in the 2-dimensional space (8). In the current study glomerular count was carried out with the use of physical dissector method in a 3-dimensional environment and showed that the decrease in the amount of glomeruli in the two case groups (0.5% and 1% lead acetate administration) was statistically significant compared to the control group. Some other studies have reported an increase in the glomerular volume following lead acetate administration, however, significant changes in histologic structure of the glomeruli are not seen; some have just noted an increase in the amount of endothelial and probably mesangial cells in the visceral layer of the Bowman's capsule (6). Although the increase in the number of endothelial and mesangial cells was based on qualitative studies, and stereologic survey is needed to approve this finding and measure the increase, the enlargement in the remaining glomeruli in the group receiving lead acetate in our study is in accordance with these results.

The level of filtration and glomerular filtration rate are very much dependant on each other (19), such that in chronic lead intoxication, the decrease in the number of glomeruli is associated with the increase in total glomerular volume; so not only is the lost filtration compensated, but the glomerular volume and volume to the number of the left glomeruli ratio are also increased. This increase is suggestive of an increase in the filtration rate.

In conclusion, the results of this study show that many of the glomeruli undergo changes during chronic lead intoxication. Therefore with regard to the importance of stereology in quantitatively determining the changes caused by lead intoxication and the histopathologic damage to the renal tissue, it is suggested that, in later studies these factors are taken into consideration: 3-dimensional measurements of other composing elements of the nephron and collecting ducts, and measuring the amount and volume of different cells quantitatively,

especially measuring glomerular basement membrane thickness.

Acknowledgments

The authors wish to thank and appreciate all the authorities of Medical Faculty of Ahwaz University of Medical Sciences for providing the facilities of this research.

REFERENCES

1. Mayhew TM, Gundersen HJG. 'If you assume, you can make an ass out of u and me': a decade of the dissector for stereological counting of particles in 3D space. *J Anat* 1996; 188: 1-15.
2. Benedtsen TF, Nyengaard JR. Unbiased estimation of particle number using sections – an historical perspective with special reference to the stereology of glomeruli. *J Microscopy* 1989; 153(1): 93-102.
3. Sterio DC. The unbiased estimation of number and sizes of arbitrary particles using the dissector. *J Microscopy* 1984; 134: 127-136.
4. Nriagu JO: Saturnine gout among Roman aristocrats: Did lead poisoning contribute to the fall of the Empire? *N Engl J Med* 1983; 308: 660-663.
5. Conrad ME, Barton JC: Factor affecting the absorption and excretion of lead in the rat. *Gastroenterology* 1978; 74: 731-740.
6. Vyskocil A, Semecky V, Fialia Z, Cizkova M, Viau C: Renal alteration in female rats following subchronic lead exposure. *J App Toxicology* 1995; 15(4): 257-262.
7. Goyer RA: Renal changes associated with lead exposure. In: *Dietary and environmental lead: Human Health. Effects.* KRMAhaffey, Ed., Elsevier, New York, pp. 315-338 1985.
8. Inglis JA, Henderson Da, Emmerson BT. The pathology and pathogenesis of chronic lead nephropathy occurring in Queensland. *J Path* 1978; 124(2): 65-76.
9. Khalil-Manesh F, Gonick HC, Cohen Ah, Alinovi R, Bergamashi E, Mutti A, Rosen VJ, Experimental model of lead nephropathy. I. Continuous high- dose lead administration. *Kidney International.* 1992; 41: 1192-1203.

10. Nyengaard JR, Benedtsen TF. Glomerular number and size in relation to age, kidney weight and body surface in normal man. *Anatomical record* 1991; 223: 194-201.
11. Kiernan JA. *Histological & histochemical methods: Theory and practice* 2nd edition 1990; pp. 10-31.
12. Hinchliffe SA, Sargent PH, Howard CV, Chan YF, Vanvelzen D. Human intrauterine renal growth expressed in absolute number of glomeruli assessed by the 'dissector' method and Cavalieri principle. *Lab Invest* 1991; 64: 777-784.
13. Gundersen HJG, Jensen EB. The efficiency systematic sampling in stereology and its prediction. *J Microscopy* 1987; 147: 229-263.
14. Michel RP, Cruz-Orive LM. Application of the Cavalieri principle and vertical sections method to lung estimation of volume and pleural surface area. *J Microscopy* 1988; 150: 117-136.
15. Wedeen RP, Maesaka JK, Weiner B, Lipat GA, Lyons MM, Vitale TF, Joselow MM. Occupational lead nephropathy. *Am J Med* 1975; 59: 630-641.
16. Vyskocil A, Panel J, Miloslav T, Ettlerova E, Semecky V, Kasparova, et al. Dose related proximal tubular dysfunction in male rats chronically exposed to lead. *J Applied Toxicol* 1989; 9(6): 305-399.
17. Marcussen N, Ottosen PD, Christensen S, Olsen S. A tubular glomeruli in lithium-induced chronic nephropathy in rats. *Lab Invest* 1989; 61(3): 295-301.
18. O'Flaherty EJ, Adams WD, Hammond PB, Taylor G. Resistance of the rat to development of lead-induced renal functional deficits. *J Toxicol Environ Health* 1986; 18(1): 61-75.
19. Schmiss A, Nyengaard JR, Benedtsen TF. Glomerular volume in type 2 (non insulin-dependant) diabetes by a direct and unbiased stereologic method. *Lab Invest* 1990; 62(1): 108-113