

IMMUNOHISTOCHEMICAL ANALYSIS OF p53 AND ITS CORRELATION TO THE OTHER PROGNOSTIC FACTORS IN BREAST CANCER

M. Etebary¹, I. Jahanzad², MA. Mohagheghi² and E. Azizi¹

1) Department of Pharmacology and Toxicology, Faculty of Pharmacy, Tehran University of Medical Sciences, Tehran, Iran

2) Institute of Cancer Research, Imam-Khomeini Hospital, Tehran University of Medical Sciences, Tehran, Iran

Abstract- *Involvement of genetic alterations in breast cancer, one of the most common types of female malignancies, has been well documented. Among the possible alterations, mutations in several genes including p53 as an important prognostic factor, have been extensively studied. Mutated p53 protein has longer half-life than the wild type protein that is detectable by immunohistochemistry (IHC). Our study included 72 tumor samples from unselected Iranian breast cancer patients. Tissue samples were stained with H & E to determine the histopathological type and malignancy grade of patients' tumors. Nuclear p53 protein levels were also determined in tissue samples by IHC using DO-7 anti-p53 antibody. We also investigated correlation between p53 immunostaining and other prognostic factors. Results of our study indicated that the pattern of p53 immunostaining was significantly related to high malignancy grade ($p=0.08$) and age at diagnosis above 45 years ($p=0.03$). In conclusion, results of the present study indicated the validity and simplicity of application of IHC in determining the status of p53 protein. Our data support the results of other studies that have suggested that over expression of p53 protein can be considered as an indicator of increased malignancy potential and worse prognosis in breast cancer patients. Acta Medica Iranica: 40(2): 88-94; 2002*

Key Words: p53, immunohistochemistry, breast cancer, prognostic factor

INTRODUCTION

Breast cancer is one of the most common types of malignancies in women and is responsible for almost 20% of all female cancers (1,2). A great majority of breast cancers are sporadic (3,4). Involvement of genetic alterations in breast cancers have been well

documented. Among the possible alterations, somatic and germline mutations and consequently changes in the protein products of several genes including p53 are considered to be very important (5,6).

The p53 gene is one of the most important tumor suppressor genes that is located on the chromosome 17 and encodes a 53 kDa nuclear protein (7,8). This gene is important for several reasons including: a) genomic stability b) transactivation of genes involved in cell cycle regulation c) DNA repair d) apoptosis e) effectiveness of chemotherapy and f) prognosis of the disease (9-14). Several investigators have shown that mutated p53 protein has longer half-life compared to wild type protein due to alteration in its conformation (10-13,15). This longer half-life enables researchers to detect the expression of the mutated p53 protein by immunohistochemical (IHC) techniques using specific antibodies against p53 protein (10,16).

Many researchers have studied the prognostic value of p53 protein expression in different types of cancers including breast cancer (12,15,17). It is noteworthy that reliable prognostic factors help oncologists to choose the most appropriate therapeutic regimen for patients individually. Therefore, in the present study we decided to determine the level of p53 protein expression by IHC and further evaluated the correlation between p53 immunostaining and other prognostic factors including histopathological type, malignancy grade, and age at diagnosis in an unselected group of Iranian breast cancer patients.

MATERIALS AND METHODS

Patients population

Our study included 72 resected breast carcinomas from female patients that were diagnosed in 1998-2000, (mean age: 40.25 years with a standard deviation of 9.166, range: 19-68) hospitalized and treated at the Imam Khomeini Cancer Institute and Jihad Breast Cancer Treatment Center.

Correspondence:

Dr. E. Azizi, Department of Pharmacology and Toxicology, Faculty of Pharmacy, Tehran University of Medical Sciences, Tehran, Iran

Fax: +9821 6461178

E-mail: aziziebr@sina.tums.ac.ir

Histopathological analysis

Tissue samples from patients were surgically obtained during mastectomy or lumpectomy. Tumor samples were then dissected and block-sized pieces were fixed in 4% paraformaldehyde for 24 h and stored in 70% ethanol at 4°C. Following fixation, samples were trimmed to 3-5 mm in thickness and embedded in paraffin to prepare sections of 5 µm for staining. The haematoxylin and eosin (H & E) that is the most widely used histological method was used to stain and analyze tissue sections (18).

Immunohistochemical analysis

Nuclear p53 protein levels were evaluated in 72 tumor samples by IHC analysis. Sections of 5 µm were mounted on slides, deparaffinized in xylol and rehydrated in graded ethanol solutions. Tissue sections were then incubated in citrate buffer (pH=6.0) for 5 min. The heat antigen retrieval technique preceded IHC staining. For blocking endogenous peroxidase activity, sections were then treated with 3% hydrogen peroxide for 15 min. After preincubation in 1% BSA in Tris buffer, sections were incubated overnight at 4°C with monoclonal mouse anti-human p53 protein (DO-7; Dako-Denmark). The DO-7 antibody recognizes an epitope at the N-terminal of the human p53 protein. The epitope for the antibody is known to reside between amino acids 19 to 26. The antibody reacts with wild type as well as the mutant type of the p53 protein. The antibody was used at a dilution of 1:150 in 1% BSA in Tris buffer. The streptavidine-biotin complex immunoperoxidase (LSAB2 detection kit, Dako-Denmark) was used to visualize the results. The ideal immunostaining conditions for antibody have been established in our preliminary experiments. The chromogen of choice was AEC (3-amino 9-ethylcarbazole) which develops a red-color following peroxidation by HRP. Positive control slides for p53 protein (Human Squamous Cell Carcinoma) were obtained from Dako (T1076; Dako-Denmark) and used in our experiments to show the quality and specificity of the DO-7 antibody. In each series, a section incubated without the primary antibody was also used as negative control.

Scoring

The cellular immunoreaction of the tissue samples were scored on the basis of the intensity of the specific nuclear staining on a four-point scale: 0= no staining, 1= weak staining, 2= staining of moderate intensity, and 3=strong staining. Only tumor tissues with score of 2 or more were considered positive in terms of p53 immunostaining. Scoring was performed by two different observers.

Malignancy grading

A modified version of the Bloom and Richardson grading system (19) was used to determine the malignancy grade of tumor samples. This system is based on equal importance of three tumor features such as tubule formation, nuclear pleomorphism and mitotic count, determining three prognostic categories including low risk (I), intermediate risk (II) and high risk (III).

Statistical methods

In order to compare p53 positive and negative groups with respect to age and categorical or ranked prognostic variables, the independent-sample t-test and the chi-square test were applied, respectively. Parameters for statistical analyses were p53 protein expression, pathological type, malignancy grade, and age at diagnosis. $P < 0.05$ was considered statistically significant unless otherwise indicated.

RESULTS

Histopathological Analysis

Histopathological type and malignancy grade of tumor samples were evaluated according to the WHO criteria and Scarff-Bloom-Richardson grading system, respectively. In our study the results of H & E staining as shown in Figure 1 indicated that tumors were variants of breast carcinomas comprising of ductal (94.4%), intraductal (4.2%), and mucinar (1.4%). The majority of the ductal carcinomas had also an invasive pattern. The results of malignancy grading of tumor samples indicated three categories including low I (16.7%), intermediate II (55.6%), and high risk III (27.8%).

Immunohistochemical Analysis of p53 Protein

Immunohistochemical analysis of the breast cancer tissue samples clearly indicated that the DO-7 antibody specifically recognized nuclear accumulation of altered p53 protein (Fig. 2). The results of immunostaining of p53 in tumor cells also showed different levels of nuclear expression of the protein, while the number of positive cells varied from tumor to tumor. In the normal glands and ducts adjacent to tumor, only a few cells were found to be weakly positive for p53 in their nuclei. Cells were considered positive if immunostaining was found in nucleus with a score of 2 or more. In our study, positive p53 nuclear immunostaining was found in 29 tumors (40.3%) versus 43 negative tumors (59.7%).

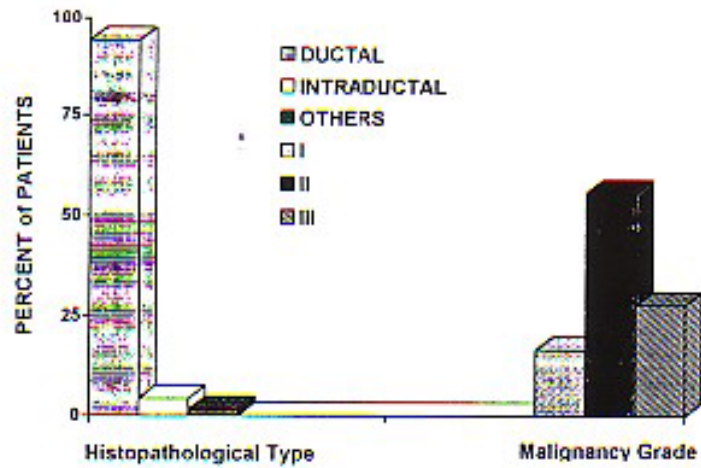


Fig. 1. Histopathological type and malignancy grade of patients' tumor samples. Following H & E staining, histopathological type and malignancy grade of tumor samples were evaluated according to the WHO criteria and the modified Scarff-Bloom-Richardson grading system, respectively




Fig. 2. Nuclear Immunostaining of p53 protein in tumor samples. Tumor samples were analyzed using IHC with DO-7 anti-p53 antibody. The LSAB-2 kit was used to detect the immunostaining pattern of p53 in tumor samples. Slides were then examined by two different observers under the microscope and photographed at 160X. (A) positive, and (B) negative tumor sample

Correlation between p53 and other prognostic factors

The relationships between p53 immunostaining and age at diagnosis, and malignancy grade are shown in figures 3 and 4, respectively. Statistical significance of the results among patients between p53 positive and negative groups in relation to the other clinical-histopathological parameters are also summarized in Table 1. These results indicate that the pattern of p53 immunostaining is significantly

related to the high malignancy grade and age at diagnosis above 45 years. Mean age of patients with positive p53 (43.48 years) was significantly ($p=0.01$) more than patients with negative p53 (38.07 years). The results indicated that positive tumor samples for p53 in this study had a higher malignancy grade, especially when we added grades II and III together for statistical evaluations against grade I. No obvious relationship was found with histological type (data not shown).

Table 1. Correlation between positive and negative p53 immunostaining and clinical histopathological parameters

	Positive p53		Negative p53		P value
	No.	(%)	No.	(%)	
Age¹					
< 45	17	(58.6)	35	(81.4)	0.03
≥ 45	12	(41.4)	8	(18.6)	
H. Type²					
Ductal Ca.	27	(93.1)	41	(95.4)	0.70
Intraductal Ca.	2	(6.9)	1	(2.3)	
Others	0	(0)	1	(2.3)	
M. Grade³					
Low	3	(10.3)	9	(20.9)	0.08
Moderate	15	(51.7)	25	(58.2)	
High	11	(37.9)	9	(20.9)	
total	29	(100%)	43	(100%)	

Note: 1) Age at diagnosis; 2) Histopathological type; 3) Malignancy grade.

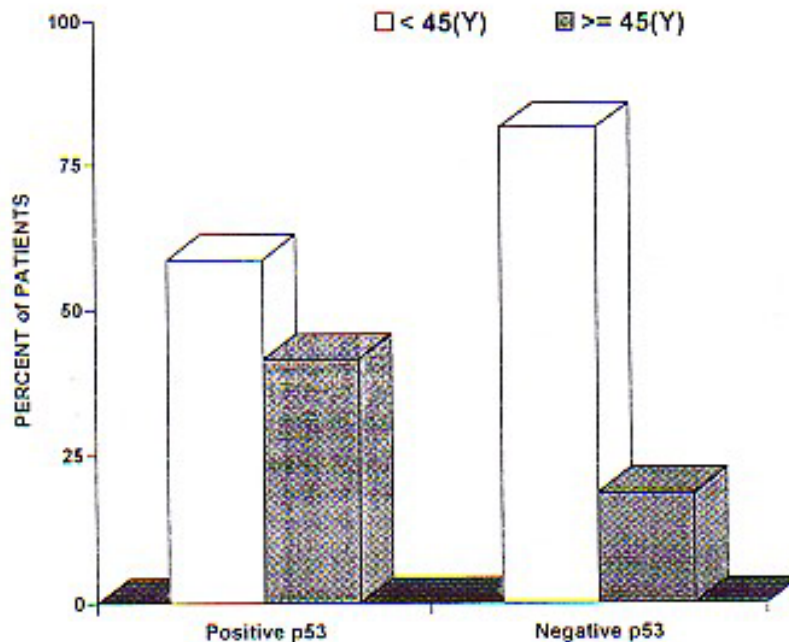


Fig. 3. Correlation between p53 protein expression and age of patients at diagnosis. Patients were divided in two groups based on their p53 immunostaining and age at diagnosis. A significant difference in age at diagnosis was seen between two groups of patients ($p=0.03$). Mean age of patients with positive p53 immunostaining was significantly more than patients with negative p53 ($p=0.01$)

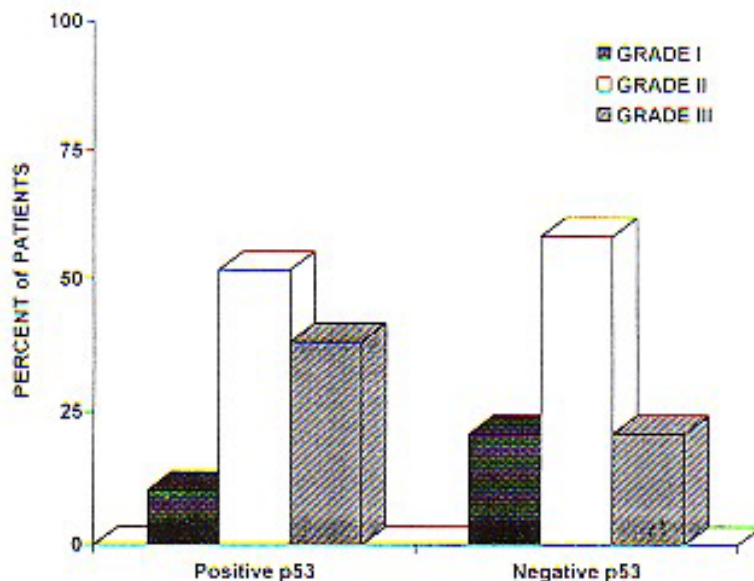


Fig. 4. Correlation between p53 protein expression and malignancy grade of patients' tumor samples. Malignancy grade in two groups with positive and negative p53 immunostaining was significantly different ($p=0.08$). Percent of tumors with grade I in patients with negative p53 was more than patients with positive p53 ($p=0.08$)

DISCUSSION

Many investigators have studied alterations in genes involved in the cell cycle regulation as important prognostic factors in different malignant tumors (10,11,13,20). Of these regulators, p53 tumor suppressor gene, a negative regulator of cell cycle has received a great deal of attention for its prognostic value in a variety of malignancies including breast cancers. This gene is one of the most frequently mutated genes in different types of cancers (10,11,15-17). Mutated p53 protein has shown to have a longer half-life than the wild type protein that is detectable by IHC techniques. Another reason for abnormal cell nuclear accumulation of p53 protein has been shown to be in response to exposure to DNA damaging agents (10). In either cases detection of abnormal overexpression of wild type or mutated p53 protein by IHC techniques can be considered as an indicator of increased malignancy potential and worse prognosis in breast cancer patients. Many independent studies, using different methodologies for evaluating the prognostic value of p53 gene alterations in breast cancers have indicated a range of 16-58% positive immunostaining versus 14-40% gene mutations (5,10,11).

In another study, the results of CDGE analysis of breast tumors showed highly significant association

between presence of p53 gene mutations and protein accumulation suggesting that positive immunostaining was mainly due to p53 mutations. Combination of IHC and PCR-SSCP methods have shown to be able to increase the efficiency for detection of p53 mutations in 7 different tumors including breast cancer cells to 100% versus 28% for FISH, 57% for IHC and 71% for PCR-SSCP. Therefore, the reliability for detecting p53 mutations by IHC was found to be high enough with particular attention to the simplicity and cost-effectiveness when compared to PCR-SSCP or FISH (6).

In the present study, we evaluated the p53 alterations as a prognostic factor by IHC techniques in tumor samples of 72 unselected Iranian breast cancer patients. We also studied the correlation between p53 immunostaining and other clinical parameters such as malignancy grade, pathological type, and age at diagnosis in these patients. In our study, the specificity of the DO-7 antibody to detect nuclear accumulation of p53 protein was confirmed by immunohistochemical staining of formalin-fixed paraffin embedded human breast tumor tissues. As previously reported by others, in our samples the p53 protein expression was also found as nuclear accumulation in the neoplastic epithelial cells (10). The results of our study indicated that 40.3% of the breast tumor samples stained positively using DO-7 antibody. These results are in close agreement with

the results of previous findings by other investigators that have used different antibodies such as CM-1 and DO-1 (21) or the same DO-7 antibody (22).

It has already been reported that in breast cancer patients a strong relationship exists between p53 alterations with poor prognosis, failure to respond to endocrine therapy, and therefore poor survival (12,15,23,24). In our study, we also noticed that tumors with positive immunostaining for p53 protein had a significantly high histopathological grade ($p=0.08$). This indicated the more aggressive behavior and hence poor prognosis for patients. Considering the type of tumor, our results indicated that the ductal carcinoma with an invasive pattern was the most common histopathological type among all tumor samples. It has been already reported that alteration in the p53 gene is found in 20-40% of invasive breast cancers (20). In this study, statistical comparison between histological type of tumors and p53 immunostaining showed no significant difference between p53 positive and negative groups. This could be as a result of very high proportion of ductal carcinomas versus other types in our tumor samples.

Age at diagnosis is another important prognostic factor especially for determining the hereditary versus sporadic types of breast cancers. Most of the cases with Li-Fraumeni syndrome (LFS), a rare dominantly inherited condition associated with germline mutation in p53 gene, develop malignancies at early age particularly under 45 years (2,4,14,25). It is also known that genes such as BRCA1 and BRCA2 (26) are responsible for developing hereditary breast and ovarian carcinomas even at earlier age (i.e. under 40 years). The results of this study indicated that in p53 positive group, percentage of patients with age above 45 years were significantly more than patients with age below 45 years ($p=0.03$). Although there is a report indicating an inverse correlation between age and p53 immunostaining (10), but more data including our results support that p53 mutations frequently occur in older patients than young ones (2,11).

It has been shown that loss of p53 function enhances cellular resistance to a variety of agents in cancer chemotherapy (23). In our study 40.3% of tumor samples showed positive p53 immunostaining that is in upper range of 16-58% of estimated alterations in p53 gene in sporadic breast cancers (11). Therefore, this relatively high level of overexpression of p53 protein is important in the prediction of responsiveness of tumor cells to cytotoxic anticancer agents that need functional p53 protein to induce apoptosis.

In conclusion, results of the present study along with previous publications indicate the validity and simplicity of application of IHC technique in determining the status of p53 protein. The authors

also believe that it is important to investigate the correlation between p53 immunostaining with malignancy grade, histopathological type, age at diagnosis, and other possible prognostic factors to predict the prognosis, drug responsiveness, and survival rate among patients with breast cancer. We are also in the process of final preparation of manuscript related to the pattern of BRCA1 protein expression, and estrogen receptor status in the same group of patients to find correlations between p53 and other important genes involved in different types of breast cancers.

Acknowledgments

We are especially grateful for the financial support of the vice chancellor for research and his colleagues at TUMS. We also appreciate assistance of officials and researchers of Imam-Khomeini Cancer Institute and Jihad Breast Cancer Treatment Center. The authors are also grateful for scientific advice of Dr. Babaei from Tarbiat Modarres University on statistical evaluations of the results.

REFERENCES

1. Pharoah DPP, Stratton FJ, Mackay J. Screening for breast and ovarian cancer: the relevance of family history. *British medical bulletin* 1998; 54(4): 823-38.
2. McPherson K, Steel CM, Dixon JM. Breast cancer-epidemiology, risk factors and genetics. *British Medical Journal* 2000; 321: 1-8.
3. Yang X, Lippman EL. Brca 1 and Brca 2 in breast cancer. *Breast cancer Res Treat.* 1999; 54: 1-10.
4. Martin AM, Weber BL. Genetic and hormonal risk factors in breast cancer. *J Natl cancer Inst* 2000; 92: 1-15.
5. Falette N, Paperin MP, Treilleux I, Gratadour AC et al. Prognostic value of p53 gene mutations in a large series of node-negative breast cancer patients. *Cancer Research* 1998; 58: 1451-55.
6. Furuwatari C, Yagi A, Yamagami O, Ishikawa M et al. A comprehensive system to explore p53 mutations. *Am J Clin Pathol* 1998; 110: 368-73.
7. Home GM, Anderson JJ, Tiniakos DG, McIntosh GG et al. p53 protein as a prognostic indicator in breast carcinomas; a comparison of four antibodies for immunohistochemistry. *British Journal of Cancer* 1996; 73: 29-35.

Analysis of p53 in breast cancer

8. Hussain SP, Harris CC. Molecular epidemiology of human cancer: Contribution of mutation spectra studies of tumor suppressor genes. *Cancer Research* 1998; 58: 4023-37.
9. Berns EMJJ, Van Steveren IL, Look MP, Smid M et al. Mutations in residues of p53 that directly contact DNA predict poor outcome in human primary breast cancer. *British Journal of Cancer* 1998; 7(7): 1130-36.
10. Wakasugi E, Kobayashi T, Tamaki Y, Ito Y et al. p21 (Waf 1/Cip 1) and p53 protein expression in breast cancer. *Am J Clin Pathol* 1997; 107(6): 684-91.
11. Gretarsdottir S, Tryggvadottir L, Jonasson JG, Sigurdsson H et al. p53 mutations analyses on breast carcinomas; a study of paraffin-embedded archival material. *British Journal of Cancer* 1996; 74: 555-61.
12. Fitzgibbons LP, Page DL, Weaver D, Thor AD. Prognostic factors in breast cancer: College of American pathologists consensus statement 1999. *Archives of Pathology and Laboratory Medicine* 2000; 124: 1-25.
13. Philips KA, Nichol K, Ozcelik H, Knight J. Frequency of p53 mutations in breast carcinomas from Ashkenazi Jewish carriers of BRCA1 mutations. *J Natl Cancer Inst* 1999; 91: 1-7.
14. Haber D. BRCA 1: An emerging role in the cellular response to DNA damage. *The Lancet* 2000; 355: 2090-91.
15. Clark JL, Nguyen PL, Jaszcz WB, Jatoi A et al. Prognostic variables in male breast cancer. *The American Surgeon*. 2000; 66: 1-10.
16. Sjalander A, Birgander R, Hallmans G, Cajander S et al. p53 polymorphisms and haplotypes in breast cancer. *Carcinogenesis* 1996; 17(6): 1313-16.
17. Wynford-Thomas D, Blaydes J. The influence of cell context on the selection pressure for p53 mutation in human cancer. *Carcinogenesis* 1998; 19: 29-36.
18. Lyon H. Hematoxylin-Eosin: An example of a common histological staining method. In: Celis JE. *Cell biology, A laboratory Handbook*, 2nd edition. San Diego: Academic Press 1998; 232-37.
19. Rosen PP. Invasive Mammary Carcinoma. In: Harris JR, Lippman ME eds. *Diseases of the breast*, 1st edition. Philadelphia: Lippincott-Raven 1996; 393-444.
20. Cremoux PD, Salmon AV, Liva S and Dendele R. p53 mutations as a genetic of typical medullary breast carcinoma. *J Natl Cancer Inst* 1999; 91: 1-4.
21. Thorlacius S, Thorgilsson B, Bjornsson J, Tryggvadottir L et al. p53 mutations and abnormal p53 expression protein in breast carcinomas related to prognosis. *Eur. J. Cancer* 1995; 31A, 1856-61.
22. Macgrogan G, Bonichon F, DE Mascarel I, Trojani M et al. Prognostic value of p53 in breast invasive ductal carcinoma: an immunohistochemical study on 942 cases. *Breast Cancer Res. Treat* 1995; 36: 71-81.
23. Lowe SW, Ruley HE, Jacks T, Housman DE. P53-dependent apoptosis modulate the cytotoxicity of anticancer agents. *Cell* 1993; 74: 957-67.
24. Isaksson E, Cline JM, Skoog L, Soderqvist G et al. p53 expression in breast and endometrium during estrogen and tamoxifen treatment of surgically postmenopausal cynomolgus macaques. *Breast Cancer Res Treat*. 1999; 53: 61-7.
25. Sedlacek Z, Kodet R, Kirz V, Seemanova E et al. Two Li-Fraumeni syndrome families with novel germline p53 mutations; Loss of the wild-type p53 allele in only 50% of tumours. *British Journal of Cancer*. 1998; 77(7): 1034-39.
26. Claus EB, Schildkraut J, Iversen ES, Berry D et al. Effect of BRCA1 and BRCA2 on the association between breast cancer risk and family history. *J Natl Cancer Inst*. 1998; 90: 1-9.