

# FAMILIAL OCCURRENCE OF LIP PITS: A CASE REPORT

M. Motesaddi Zarandi and G. Givehchi

Department of Otolaryngology, Head and Neck Surgery, Amir Alam Hospital, School of Medicine, Tehran University of Medical Sciences, Tehran, Iran

**Abstract:** Lip pits are among the rarest congenital deformities recorded. Initially reported in 1845, it's familial occurrence has been reported just once. These developmental anomalies occur either as an isolated defect or in association with other developmental deformities including cleft lip, cleft palate or both. It may be located at the commissures of the lips or in the midline of the lower lip. It is often inherited as an autosomal dominant trait with variable penetrance.

*Our report of a family in which all of the three children (two girls and a boy) and their father were involved is in concert with the latter statement.*

*Acta Medica Iranica: 40(2): 132-135; 2002*

**Key Words:** Lip pits

## INTRODUCTION

Congenital lip pits are among the rarest congenital deformities recorded (1). The first report was described in 1845 by DeMurquay (2). In 1951 Watanabe and his coworkers found a total of only 100 cases reported in the literature (3). Since that time, there has been just a single report of its familial occurrence in 18 members of a family (4). Lip pits are developmental anomalies that occur either as an isolated defect or in association with other developmental disturbances (5) such as popliteal pterygium syndrome (6), Van der Woude's syndrome (7), oral-facial-digital syndrome and Marres and Cremers syndrome (8).

Lip pits may develop at the commissures of the lips or in the midline of which the former is much more common. The latter, usually bilateral and symmetric midline depressions, develop on the vermilion border of the lower lip. These depressions represent fistulae lined by stratified squamous epithelium that traverse the underlying muscles for 5-25 mm and communicate with minor salivary glands through their excretory ducts. Viscous saliva can be expressed from the sinuses with pressure. Lip pits

### Correspondence:

M. Motesaddi Zarandi, Department of Otolaryngology Head and Neck Surgery, Amir Alam Hospital, School of Medicine, Tehran University of Medical Sciences, Tehran, Iran

Tel: +9821 6703037

Fax: +9821 6760245

E-mail: Motasaddi@yahoo.com

may be surgically excised if repeated infections become problematic or for cosmetic reasons (5).

## CASE REPORT

Our case is a representation of development of lip pits in four members of a family, discovered incidentally in one of the members visiting our clinic (Fig. 1-4).

All of the three children (8 and 15 years old girls and a 5 years old boy) and their father (45 years old) were involved. No pathology was found in their systemic and E.N.T. examinations, except for the presence of previously repaired unilateral incomplete cleft lip in the son. There was no history of either a familial marriage or similar problem in the other members of the family.

The father-missing in the photographs-had surgically excised his lip pits for cosmetic reasons.

## DISCUSSION

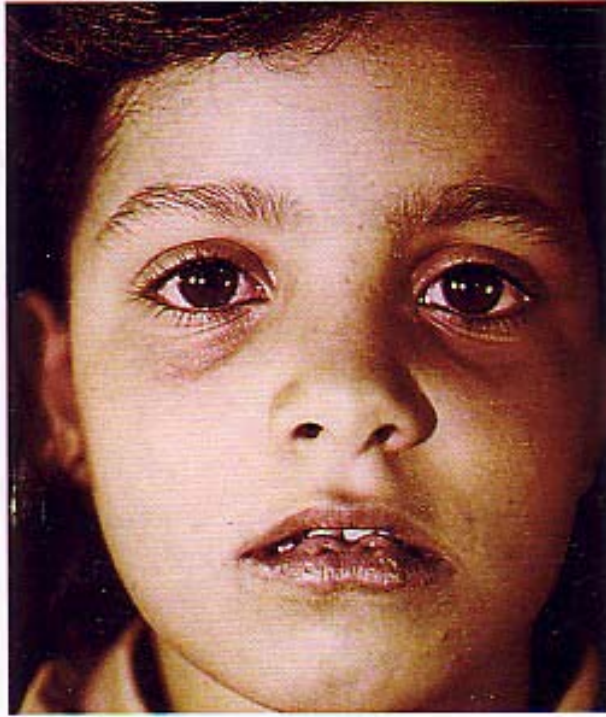Fistulae represent failure of closure of evanescent sulci that appear at 10-14th month of embryonic period (9).

The most logical explanations are the two proposed by Wang and Mc Comber (10). The anomaly is attributable to a defective gene which would explain the familial appearance and the frequent association with cleft lip, cleft palate (or both) or the anomaly is the result of retardation or inhibition of a certain phase in the normal development of embryonic lower lip, hence the constancy of location (1).

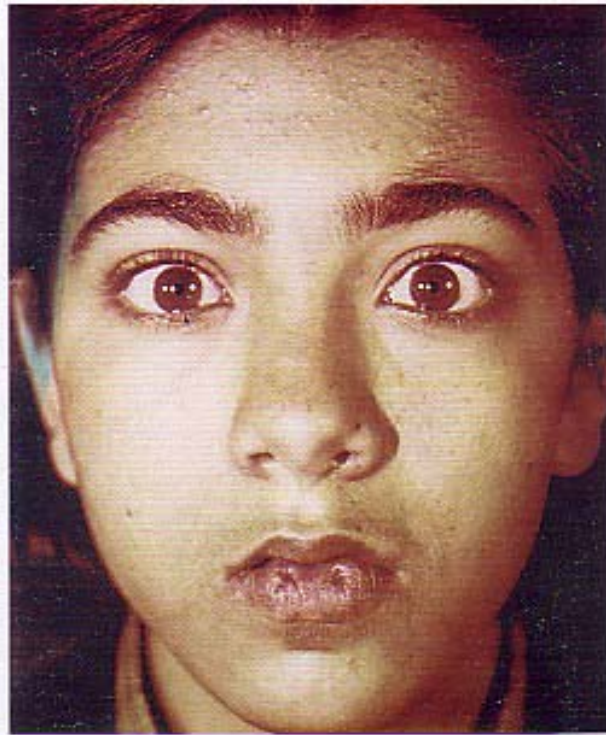
Approximately three fourth of patients with central lip pits have an associated cleft lip, cleft palate or both (5). It is often inherited as an autosomal dominant trait with variable penetrance (11) and is more common in females (1).

Our case, reporting a familial occurrence of this rare congenital deformity in all of the three siblings-male and female-of the involved father is in favour of it's autosomal dominant (AD) inheritance.

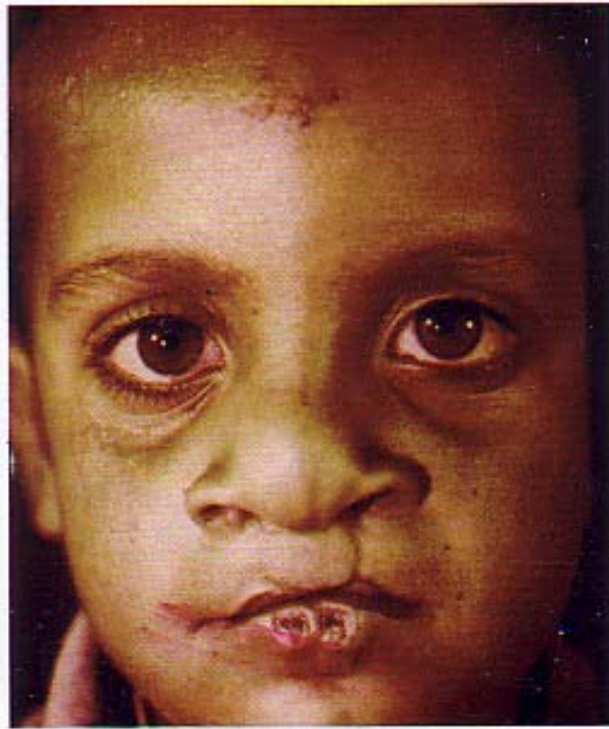Though not genetically proved yet, there is a possibility of a unique origin for a mutation responsible for many or most cases of congenital lip pits, which requires further investigations.




**Fig. 1.** lip pits in a 8 year old girl



**Fig. 2.** lip pits in a 15 year old girl



**Fig. 3.** A 5 year old boy with lip pits and previously repaired unilateral cleft lip



**Fig. 4.** All of the three involved siblings with lip pits

## REFERENCES

1. Brauen RO. General aspects of the bilateral cleft lip repair. In: Grabb WC, Rosenstein SW and Bzoch KR. Cleft lip and palate, 1 st edition. Boston: Little/Brown, 1971; 278-79.
2. DeMarquay JN. Familial lip pit. *Gaz. Med. (Paris)*. 13: 52, 1845.
3. Watanabe Y. *Oral surg. Path.* 4, 709, 1951.
4. Carter WJ and Johnson RC. Congenital pits on vermilion portion of the lower lip: Report of a case. *J. America Dent Ass* 1952; 45: 39.
5. Eisen, Lynch DP. Developmental disorders. In: Eisen D and Lynch DP. *The mouth: diagnosis and treatment*, 1 st edition. St Louis: Mosby, 1998; 52-53.
6. Herold HZ, Samuel G, Baruchin AM. Popiteal pterygium synd. *Clin Orthop* 1986; 209: 194.
7. Schinezel A, Klausler M. The Van der Woude's Synd. (dominantly inherited lip pits and clefts). *J. Med Genet* 1986; 23: 291.
8. Marres HA, Gremers CW. Congenital conductive or mixed deafness, preauricular sinus, external ear anomaly and commissural lip pits: An A. D. inherited synd. *Ann Otolrhinollaryngol.* 1991; 100: 928.
9. Waldron CA. Face, lips, tongue, teeth, Oral, soft tissue, jaws, salivary glands. In: Kissane JM. *Anderson's pathology*, 9 th edition, St Louis: Mosby, 1990' 1095-6.
10. Wang MKH, McComber WB. Congenital lip sinuses. *Plas Reconstr Surg* 1956; 18: 319.
11. Shprintzen RJ, Goldberg RB. The penetrance and variable expression of the Van der Woude's synd. Implications for genetic counseling. *Cleft palate J.* 1980; 17: 52.