

NEUROLOGIC MANIFESTATIONS AS THE PRESENTING SYMPTOMS IN LUNG CANCER

M. Ghaffarpour, Sh. Firouzbaksh, H. Glichnia Omrani and B. Mansoorian

Department of Neurology, Imam Khomeini Hospital, Faculty of Medicine, Tehran University of Medical Sciences, Tehran, Iran

Abstract- *This case series reports 100 patients with lung cancer and their presenting neurologic symptoms and signs. 78% of patients were male and 22% were female. Mean age was 62± 1.04 years with a peak age between 65 and 75 years. Most patients presented with pulmonary problems (58%) and neurologic deficits as the presenting manifestations were found to be 30% along with pulmonary symptoms and 12% lacking them. Neurologic deficits were caused by local tumor invasion, metastasis and paraneoplastic syndromes in 16%, 23% and 3% of the cases respectively. Recurrent nerve palsy was the most common presenting neurologic sign. Common metastatic sites were spinal cord (12%) and brain (11%). Local invasion was mostly found in squamous cell and brain metastasis in adenocarcinoma. In reference to spinal metastasis most patients had small cell and squamous cell carcinoma. Ophthalmoplegia as a paraneoplastic syndrome is not reported in lung cancer but one of our patients developed complete ophthalmoplegia in left eye with normal imaging studies that seems interesting and needs further investigation*

Acta Medica Iranica, 40(3);198-202: 2002

Key Words: *Lung cancer, presenting neurologic symptom, local invasion, metastasis, paraneoplastic syndrome*

INTRODUCTION

Lung cancer is the leading cause of death among malignancies in both sexes and accounts for 30% of all cancer death in men and 25% in women (1). Its peak incidence is between 55 and 65 years (1) and 90% of patients are cigarette smokers (2). Considering the great differences in prognosis and mode of therapy, primary lung cancers are divided into small cell and non-small cell carcinomas of which the latter is further divided into squamous cell carcinoma (epidermoid) and adenocarcinoma (1). Although in the past epidermoid was the most frequent histologic type, presently it has been replaced by adenocarcinoma in Western countries

Correspondance:

M. Ghaffarpour, Department of Neurology, Imam Khomeini Hospital, Faculty of Medicine, Tehran University of Medical Sciences, Tehran, Iran. P.O.Box 13145-158
Fax: +98 21 6940033
Tel: +98 21 9198634- 6940033
E-mail: ghaffarpour@yahoo.com

probably due to increased success in smoking cessation efforts (1). Lung cancer gives rise to signs and symptoms caused by local invasion, lymphoid involvement, distant metastasis and paraneoplastic syndromes (3). Peripheral and central nervous system are in danger of invasion and spread of these malignancies. Brain metastases are seen in 18 to 65% of primary lung cancers (4). This rate depends on the underlying pathology since up to 40% of small cell carcinomas and adenocarcinomas show brain metastasis at autopsy which is twice as frequent as epidermoid subtypes (5). Generally 30 to 60% of brain metastatic cancers originate from lung (6). The most common cause of spinal cord metastasis are lung malignancies and in about 3% cord compression is the first sign of metastatic lung cancer (7). Considering dura matter and spinal column metastasis this rate will increase. Clinically significant paraneoplastic syndromes are seen in less than 1% of patients (8). Sometimes patients seek medical attention because of neurologic symptoms. Thus, this study was performed for the first time at this university on 100 patients to evaluate initial neurologic manifestations of lung cancer.

MATERIALS AND METHODS

Patients were enrolled in this study according to the following inclusion and exclusion criteria.

- 1- All the patients with pathologically proven primary lung cancer.
- 2- None received chemotherapy and radiotherapy prior to the study.
- 3- No history of neurologic problem except complications of lung cancer.

One hundred patients with primary lung malignancy who came to this hospital underwent investigation. A complete history was taken, physical and pulmonary examinations with chest CT scan were performed for all cases. Biopsy samples were taken through bronchoscopy and studied in the pathology laboratory of this center. After confirmation of diagnosis, perfect neurologic examinations were done and specific attention was paid to history and initial symptoms to differentiate patients with pure pulmonary, pulmonary and neurologic and pure neurologic symptoms and signs. Ethical issues were explained to the patients. In central or peripheral nervous system involvement, brain and spinal cord imaging and electrodiagnostic

evaluation were performed respectively. After complete evaluation, neurologic manifestations of the patients were put in the following groups. Local invasion, brain metastasis, spinal cord and column metastasis, peripheral nerve metastasis and paraneoplastic syndromes.

RESULTS

Seventy-eight percent of patients were male and 22% female. Their age ranged between 37 and 80 years and the mean age was 62 ± 1.04 years (63.07 in the male and 58.4 in the female group, Table 1). The peak incidence was between 65 and 75 years (40%). Fifty-two percent had squamous cell carcinoma, 22% adenocarcinoma and 21% small cell carcinoma. The remainder included mixed type and undifferentiated carcinomas (Fig. 1). Distribution of tumors between two lungs was nearly the same (Table 2). 85% of men and 47.2% of women were smokers (74% of all cases) with 1.5 to 100 packyear¹ (mean 37.8 packyear). Thirty-eight persons were substance abusers of whom 73.6% used opium, 10.5% heroine, 2.5% grass and 2.5% morphine. At the time of diagnosis 58% of patients had only pulmonary symptoms and 42% neurologic problems. Pulmonary plus neurologic symptoms were found in 30% and pure neurologic symptoms in 12% (Fig. 2). The most frequent nonneurologic symptoms were as follows: cough (65%), dyspnea (50%), bloody sputum (42%), chest pain (21%) and superior vena cava syndrome (3%). In one of the patients weight loss was the only clinical symptom. Despite low incidence of undifferentiated and small cell carcinoma, these tumors mostly present with neurologic symptoms (Table 3). Sixteen patients had symptoms related to local invasion of nervous system of whom ten had recurrent nerve paralysis, 2 had phrenic nerve involvement, one both recurrent and phrenic nerves paralysis and three had pancoast's syndromes. All the patients with recurrent nerve paralysis complained of hoarseness in whom paralysis was confirmed by endoscopy. All of them were at the left side except one. Three patients with pancoast's syndrome sought medical attention because of pain and weakness of upper extremity at the side of tumor and in physical examination, they had sensory and motor deficits related to lower trunk of brachial plexus. Electrodiagnostic studies confirmed the diagnosis. Two cases of pancoast's syndrome showed symptoms of ophthalmic sympathetic involvement (Horner's syndrome). All of these patients had squamous cell carcinoma of upper lobes. The common pathologies in local invasion were as follows:

Epidermoid (56%), small cell carcinoma (18.5%), adenocarcinoma (12.5%) and mixed type (6.5%) and undifferentiated (6.5%) too. The most frequent brain metastatic sites were parietooccipital and parietotemporal lobes and one in dorsal midbrain. Eleven patients had neurologic symptoms due to brain metastasis as follows: acute hemiparesis (5 cases), convulsion (2 cases) headache and blurred vision (2 cases) paranoid syndrome (1 case) and miliary brain metastasis (1 case). One of our patients was a 70 years old female who initially presented with sensory problems and underwent anticoagulative therapy because of transient ischemic attack but, her consciousness gradually decreased and further studies gave rise to the diagnosis of lung adenocarcinoma and miliary brain metastasis. The major causes of brain metastasis were adenocarcinoma (45%) and then small cell and squamous cell carcinoma (55%). Manifestations of spinal column and cord metastasis were the initial symptoms in 12 cases (lumbar and back pain in 6, cervical pain in 2 cases, spastic paraparesis and sphincter dysfunction in 2, upper extremity radicular pain 1, flaccid paraparesis along with back pain and urinary problem compatible with cauda equina syndrome 1). Common locations were in thoracic region 4, cervical 2, lumbar 1 and cauda equina 1 and disseminated in 4 cases. Small cell carcinoma (41%), squamous cell carcinoma (34%), adenocarcinoma (17%) and undifferentiated type (8%) were the causal factors in metastasis to spinal cord and column. Three patients found to have paraneoplastic syndromes of whom one had complete ophthalmoplegia of the left eye, one had peripheral sensory neuropathy and the last one presented with hypoglycemia. Ophthalmoplegia was seen in a 70 years male old smoker who developed progressive diplopia, on physical examination he had complete ophthalmoplegia in left eye. In chest X-ray there was a mass in upper lobe of left lung and biopsy showed small cell carcinoma. Considering the fact that his brain and brainstem MRI, orbit and sinus CT scans were normal and no casual factor was found to explain ophthalmoplegia, this case were considered a paraneoplastic syndrome. Biopsy was required to confirm the diagnosis but patient refused. Sensory neuropathy was observed in a male smoker aged 50 years came under clinical attention because of progressive tingling and numbness of feet and then developed dysequilibrium. Diagnostic investigation gave rise to the diagnosis of localized tumor in upper lobe of right lung. Electrodiagnostic studies confirmed sensory neuropathy. Other possible causes was considered and ruled out. The third patient with paraneoplastic syndrome was a 65 years old non-smoker female who presented with episodic loss of consciousness. She had previous visits because of recurrent hypoglycemia. Diagnostic studies revealed squamous cell carcinoma of lung. Hypoglycemia resolved after surgery. In patients who presented

¹ Packyear: pack per day × years

Neurologic manifestations and lung cancer

initially with neurologic symptoms, 42.5% had squamous cell carcinoma, 21.4% adenocarcinoma,

26.2% small cell carcinoma, 4.8% undifferentiated type and 2.4% mixed type.

Table 1. Age distribution of patients with lung cancer

Additive-Relative frequency	Relative frequency	Absolute frequency	Age groups
3%	3%	3	39-35
8%	5%	5	44-40
11%	3%	3	49-45
25%	14%	14	54-50
35%	10%	10	59-55
50%	15%	15	64-60
68%	18%	18	69-65
90%	22%	22	74-70
100%	10%	10	80-75
	100%	100	Total

Table 2. Distribution of lung tumors according to anatomic sites

Additive-Relative frequency	Relative frequency	Absolute frequency	Anatomic site
26%	26%	26	RUL
38%	12%	12	RML
49%	11%	11	RLL
82%	33%	33	LUL
96%	14%	14	LLL
99%	3%	3	R&L Lungs
100%	1%	1	More than one lobe

RUL= Right Upper Lobe , RML= Right Middle Lobe , RLL = Right Lower Lobe, LUL= Left Upper Lobe, LLL= Left Lower Lobe , R= Right , L= Left

Table 3. Distribution of absolute and relative frequency of patients with lung cancer presenting with neurologic and non-neurologic symptoms according to pathology

Relative frequency of non neurologic symptoms	Absolute frequency of non-neurologic symptoms	Relative frequency of neurologic symptoms	Absolute frequency of neurologic Symptoms	Kinds of Pathology
63.5%	33%	36.5%	19	Squamous Cell Carcinoma
59.1%	13%	40.9%	9	Adenocarcinoma
47.6%	10%	52.4%	11	Small Cell Carcinoma
33.3%	1%	66.7%	2	Undifferentiated
50%	1%	50%	1	Mixed
58%	58	42%	42	Total

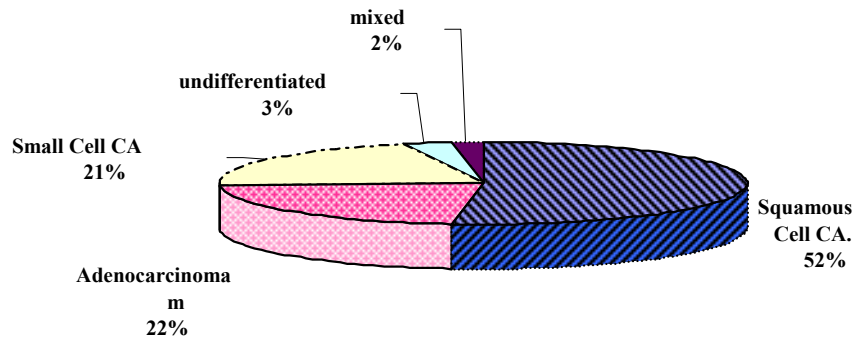


Fig. 1. Distribution of lung malignancies according to pathology

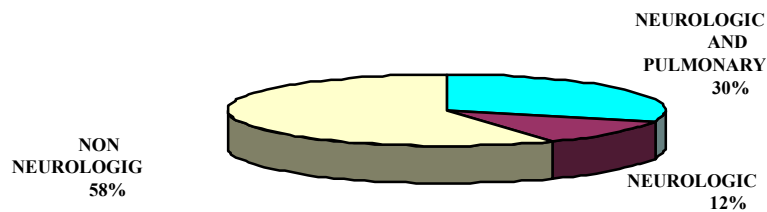


Fig. 2. Incidence of presenting symptoms in 100 patients of lung malignancies

DISCUSSION

In this study patients' peak ages were between 65 and 75 years which are higher than reference books (1). Men to women ratio was 3.5 to 1 which differs from other studies (1). Squamous cell carcinoma was the leading cause of lung cancer in our study and adenocarcinoma and small cell carcinoma were the second and third ones respectively which differs from foreign studies (1). Sixteen percent of patients had symptoms related to local invasion. Recurrent nerve paralysis was the most frequent initial neurologic symptom in patients with lung cancer (11 cases). Ten of them had left recurrent nerve paralysis which is due to the longer path at the left side. In other studies also, left side paralysis is much more common than the other side (9). In patients with brain metastasis, parietooccipital and parietotemporal lobes were more frequently involved. Other studies report the same findings (10). Symptoms related to brain metastasis constituted the initial symptoms of lung cancer in 11% of patients which is close to findings of other investigations (11,12). Three percent of patients presented with symptoms of cord compression. This rate is equal to some studies and more than some other ones (7,13). Spinal cord and column were involved totally in 12% of patients. In other studies this is about 10%. The most common involved sites in literature are thoracic vertebrae followed by

lumbosacral region which is compatible with our study (14). Finally, we had three neurologic manifestations due to paraneoplastic syndromes, one ophthalmoplegia, one peripheral sensory neuropathy and one recurrent hypoglycemia. It has been mentioned in other studies that paraneoplastic syndromes of lung cancer can present with sensory neuropathy and recurrent hypoglycemia (15) but ophthalmoplegia has not been named as a paraneoplastic syndrome of lung cancer, so we report it for the first time. Clinically significant paraneoplastic syndromes compose 1% of lung cancer manifestations (7) but in our study 3% of patients revealed this complication. One noteworthy finding is that tumor pathology in two of the patients (the one with sensory neuropathy and the one with recurrent hypoglycemia) was squamous cell carcinoma and in both of them the tumor was localized and resectable. This is due to limiting effect of antibodies producing paraneoplastic syndromes in restricting lung cancer (15). Local invasion was mostly found in squamous cell carcinoma and then small cell carcinoma. Prevalence of brain metastasis was higher in adenocarcinoma and in reference to vertebral metastasis, most patients had small cell carcinoma and squamous cell carcinoma. Two out of three patients with undifferentiated tumor developed neurologic manifestations which show the more progressive and malignant course of this pathology.

REFERENCES

1. John D Minna. Lung cancer In: Braundwald , Fauci, Kasper et al. Harrison's principles of internal medicine. 15th ed. New York: McGraw-Hill Co, 2001; 1: 562-571.
2. Win Go PA et al. Annual report to the nation on the status of cancer 1973-1996 with a special section on lung cancer and tobacco smoking. J N Nati Cancer Inst 1999; 91: 675.
3. Patel Am, Peter SG. Clinical manifestation of lung cancer. MayoClinic Proc 1993; 68: 273-277.
4. Burt M, Wronski M, Arbit et al. Resection of brain metastasis from non small cell lung CA. J Thoracic Cardiovasc Surg 1992; 103: 399-410.
5. Sen M, Demiral A, Cetingoz R et al. Prognostic factors in lung carcinoma with brain metastasis. Radiother Oncol 1998; 46: 33-8.
6. Chang DB, Yang PC, Luh KT et al. Late survival of non small cell lung cancer patients with brain metastasis, influence of treatment. Chest 1992; 301: 1293-1297.
7. Schiff D, Oneil BP. Intramedullary spinal cord metastasis, clinical features and treatment outcome. Neurology 1996; 47: 906-913.
8. Posner JB. Neurologic complication of cancer. Philadelphia: FA Davis 1995; 1: 342.
9. Adams and Victor. Principles of Neurology. 7thed New York, McGraw-Hill 2001; 3: 1457-1459.
10. Dellatre JY, Krol G, Thiler HT et al. Distribution of brain metastasis. Arch Neurology 1988; 45: 741-744.
11. Raymond Sawaya, Rajesh K, Bindal C. Metastatic brain tumors in : Andrew H Kaye, Edward R Lows Jr. Brain Tumors. 2nd ed, London: churchill livingston, 2001; P: 999-1023.
12. Balmaceda CM. Metastatic Tumors in: Rowland LP. Merrit's Neurology. 10th ed. Philadelphia: Lippincotts Wiliam and Wilkins 2000; P: 376-387.
13. Castigan W. Intramedullary spinal cord metastasis. J Neurol Neurosurg, 1985; 62:297.
14. McCormic PC, Micheal R, Fetel C. Spinal Tumors in: Lewis, P Rowland. Merrit's Neurology. 10th ed. Philadelphia: Lippincott's wiliam and wilkins 2000; P:388-397.
15. Posner JB. Paraneoplastic Neurologic syndromes in: Aminoff MJ. Neurology in General Medicine. 3rd ed. New York: churchill Livingston Co 2000; P:417-437.