

THE TERATOGENIC EFFECTS OF LORAZEPAM ON THE ORGANOGENESIS OF THE RAT FETUS

P.Pasbakhsh , K. Mehrannia and M. Barbarestani

Department of Anatomy, School of Medicine, Tehran University of Medical Sciences, Tehran, Iran

Abstract- Lorazepam has increasingly being used in our country in recent years. Pharmacologically, lorazepam belongs to the benzodiazepines known for their wide neurotropic properties. There have been several studies on the side effects of the drug as stress disorders, tumors, preconvulsive activities in case of epileptic attacks, overdose, and behavioral problems, but little is known regarding the teratogenicity of the drug and its effects on the craniofacial development.

In this study, a group of adult Wistar rats of definite average of age and weight were selected and exposed to 2 mg/kg/day to 20 mg/kg/day of lorazepam after conception (during the organogenesis in the days 9 to 18) in case and control groups. The fetuses were first studied macroscopically regarding gross anomalies, and then histologically and histochemically to exactly inspect the defects of tissue organogenesis. According to the results obtained, there was significant difference in the weight and length of the cases compared to the control group. Several anomalies of the eyes and ears (coloboma of the eyelids with protruded globes and absence of the auricle and external auditory meatus), anomalies of the skull (acrocephaly, and large rhombencephalon) were found. The craniofacial organs such as the nasal epithelium, tongue, salivary glands and the palates were also affected. According to the final analysis, there is a significant difference between the case and control groups. It was also found that taking the drug in the second half of pregnancy could affect the migration of the neural crest cells (being very sensitive) and change the mesenchymal structure of the neural crests. It also promotes the synthesis of proteins like growth hormone and growth factors. The fast, uncontrolled growth, defects the normal maturing process of the tissues during organogenesis, which ends in irreversible malformations. *Acta Medica Iranica*, 41(1): 29-32; 2003

Key Words: Ocular organogenesis, rat fetus, lorazepam, teratogenicity

INTRODUCTION

Since around 1960 an increasing number of pharmacologically active 1,4- benzodiazepine derivatives have been successfully introduced into medicine. Depending on the type of the radicals and their position, about 25 of these compounds show psychotropic efficacy and some of them have found a remarkably wide range of applications in psychiatry, as sedatives in general medicine and in premedication for surgical anesthesia (1-4).

Lorazepam belongs to the 1,3-dihydro-2-ketone group of 1,4- benzodiazepine derivatives. Lorazepam is used in medicine in comparatively small doses (1-4 mg/day for adults) as a broad-spectrum tranquilizer for treatment of anxiety and physical tension, for insomnia in association with anxiety and also for premedication before surgical anesthesia (2). Some authors regard

lorazepam as a possible teratogen inducing oral clefts and nasal septum anomalies (2) but there are disagreements in this matter. Lorazepam itself, when tested by Gillies and Lader in 1986 and by Kozaburo, et al. in 1975 was found not to have any teratogenic effects in rats and mice, but it was tested by these authors in very low doses (0.4-4 mg/kg). The aim of this study was to test teratogenic potentials of lorazepam in large doses (2-20 mg/kg/day) during the normal migration phase of cephalic neural crest cells in the eye, when they are sensitive to damage.

MATERIALS AND METHODS

In this study 48 Wistar rats weighing 200-250 g were treated by intraperitoneally injection (9th-18th) of 2-20 mg/kg/day lorazepam during the organogenesis phase (9th-18th day).

Pregnant rats were classified accordingly in case and control groups:

1- Negative control group: Included 4 pregnant Wistar rats were injected only with distilled water.

Received 15 May 2001; accepted 22 January 2003

Correspondence:

P. Pasbakhsh, Department of Anatomy, School of Medicine, Tehran University of Medical Sciences, Tehran, Iran
Tel: +98 21 6112953
Fax: +98 21 6404377
E-mail: pasbakhsh@hotmail.com

The teratogenic effects of lorazepam

2- Positive control group: Included 4 pregnant Wistar rats that were injected with 0.9% sterile distilled water plus Tween 80.

3- Case groups: They were divided into 10 further subgroups each containing 4 pregnant Wistar rats that were injected with lorazepam solution of 2-20 mg/kg/day (Table 1).

Injections were given every day at 12 o'clock with insulin syringes. On the 18th day of conception they were then anesthetized with chloroform and their fetuses were extracted. Fetuses were treated with fixation solution (Bouin's) for 24 hours. After registering number of fetuses, weight and length of each of them were determined. A stereomicroscope was used to study abnormalities of the eye, ear, and mouth. Samples were put in paraffin after fixation and undergone tissue passage with H&E. They were then studied under light microscopy.

RESULTS

No difference was seen in cases injected with 2-18 mg/kg/day lorazepam regarding ocular development and

organogenesis comparing with control groups. Yet differences in weight and length of fetuses' limbs were noticed (Table 1). Two of the samples taking 20 mg/kg/day lorazepam injection (response dose) developed auditory and ophthalmic anomalies (agenesis of external auditory meatus, auricles; coloboma palpebra and exophthalmia) (Fig 1 and 2).

Skeletal as well as craniofacial abnormalities were also noted. Limb anomalies included rotational type together with gross malformations in the number and shape of digits. Subepidermal hemorrhage was seen too. Larger hindbrain and tower skull (acrocephaly) was observed which was due to rapid and premature ossification. After analyzing ($P>0.001$) there were significant differences between case and control and sham groups (one way ANOVA). The results of the statistical analysis show that the occurrence of anomalies in the experimental group 20 mg/kg/day was 65% compared to the normal fetuses. Thus, there is a direct correlation between the high dose of the drug and the condition of the eyes (fisher exact test $p<0.001$).

Table 1. Frequency of abnormalities in the fetal rats after lorazepam injections with different dosing schedules

Experimental groups	No of rats	Total no. of fetuses	Mean weight	Mean CR	Dose (mg/kg/day)	Cleft palate	Blemish	Limb anomalies	Cleft lips	Acrocephaly	Open eyelids	Others
			(grams)	(mm)								
			14 th day	14 th day								
-five control	2	19	0.15	0.15	9.2	Distilled water	-	-	-	-	-	-
+ control	2	22	0.14	0.14	9.5	Distilled water+ tween 80	-	-	-	-	-	-
1 st group	4	50	0.99	0.99	12.1	2	-	-	-	-	-	-
2 nd group	4	46	1.25	1.25	14.5	4	-	-	-	-	-	-
3 rd group	4	50	1.20	1.20	14.8	6	-	-	-	-	-	-
4 th group	4	52	1.10	1.10	15.2	8	-	-	-	-	-	Small auricle
5 th group	4	50	1.37	1.37	14	10	-	+	-	-	-	No external auditory meatus
6 th group	4	54	1.40	1.40	13.5	12	-	+	-	-	-	No external auditory Mean+No auricle
7 th group	4	50	1.49	1.49	15.5	14	-	+	-	-	-	-
8 th group	4	46	1.50	1.50	16	16	+	+	-	+	-	-
9 th group	4	40	1.30	1.30	16.2	18	+	+	-	+	-	-
10 th group	4	52	1.50	1.50	18.5	20	+	+	-	+	+	+

DISCUSSION

Pharmacologically lorazepam belongs to the family of benzodiazepine derivatives which have a wide range of neurotropic properties. In our tests on the pregnant rat model with 2-20 mg/kg/day dosing, lorazepam appeared to affect cephalic neural crest cells during migration phase, when they are sensitive to damage (5). The impaired eyelid primordial which are also known to contain cells of the neural crest origin fail to close (6). Normally the closure takes place on the 17th day of gestation.

Calcium and phosphate aggregation may intervene with the formation of bone matrix and induce bone formation. Phosphate aggregation early in life (first years) accelerates skeletal growth. Growth hormone and calcitonin are indirect mechanisms involved in this phenomenon. Based on the results obtained from tissue histochemistry and precocious ossification process in fetuses that were under the influence of 20 mg/kg/day lorazepam, it can be concluded that lorazepam via GABA receptors, can accelerate tissue calcification by tissue aggregation of free calcium ions.

Osteogenesis is thus stimulated inducing lots of malformations in head and neck. According to table 1, fetuses given lorazepam in 20 mg/kg/day had ophthalmic disorders such as exophthalmos and open eyelids. In this experiment, the effects of the different doses of lorazepam in different groups on the process of maturation of the visual system are studied.

The results of analysis show that an increase of 85% in the incidence of malformations with the normal fetuses. Thus, this shows a direct correlation between the high doses of the drug and the condition of the eyes, in the control and the other groups, compared with the 20 mg group. High doses of the drug cause the eyes to remain open.

According to the differences of the means among the averages in the 20 mg group and the other groups, we conclude that prescribing high doses of this drug during the critical days of pregnancy induces different malformations in the head, face and the visual system, but it is not witnessed when low doses are employed. Increments in weight and length were also noted. Fetuses were not in 'C' form and instead had all erected bodies. Acrocephaly due to premature and stimulated osteogenesis was seen. The epithelium of the nose, tongue, salivary glands, and roof of the mouth were all affected by the drug. De Souza et al in 1985 (8) reported the same changes in the nasal and glossal epithelium following, the use of lorazepam. Kzabre et al in 1975 (9) and Gillies and Lader in 1986 (2), however, showed that lorazepam had no teratogenic effect; this could be due to the low dose lorazepam (0.4- 4 mg/kg/day) they had used.

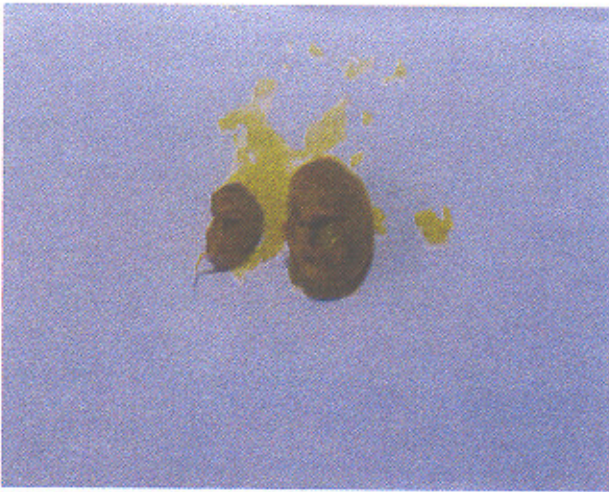


Fig. 1. 1-18-day-old rat fetuses with open eyelids after administration of 20 mg/kg/day lorazepam on the gestation day

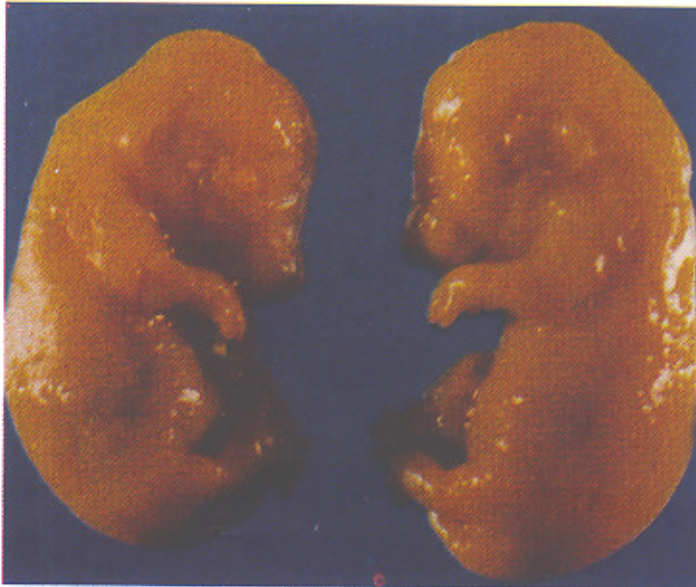

Fig. 2. Tissue structure of the rat eyeball (H&E staining, 250)
Note the open eyelids and protrusion of the eyeball

The teratogenic effects of lorazepam

In this study, lorazepam appeared to be able to affect neural crest mesenchymal component during the later part of its migration. Migration, however, continues uninhibited and later, after reaching the target sites, the insult suffered earlier will manifest itself during differentiation which is conditioned by the embryonic microenvironment in which cell-to-cell and cell-to-extracellular matrix are involved (5). There is a hypothesis that in the trans-differentiation process of the epithelial cells into the mesenchymal cells an important role is played by three endogenous transforming growth factors: TGF β 1, and β 3 (10).

It may be that lorazepam, like retinoic acid (11) is capable of interfering with the role of some of these growth factors. Abnormalities of one or more organs derived from the neural crest have been grouped under the unifying term of neurocristopathies (12). We believe that in this case the non-closure of eyelids represents examples of simultaneous neurocristopathies which are defined as conditions arising from aberrations in the early migration, growth and the differentiation in target sites of neural crest cells or their derivatives (13). Finally it is probably relevant here to touch briefly on the problem whether lorazepam should be regarded as a potential teratogen in man. In general nowadays there is a general rule in medicine that expecting mothers, if only possible, should not be prescribed with any kind of drugs at all or at least not during the first trimester of pregnancy. However, there are very often wide differences between various species and even varieties of laboratory animals and man in sensitivity to teratogens. Therefore any speculation about lorazepam as a potential teratogen for man is only valid as a warning and not as a proven recommendation.

In conclusion based on our findings and data analysis, significant differences were observed in exposure and non-exposure groups (case and control groups) regarding lorazepam. This discrepancy was more logical when comparing negative control group with case groups taking higher doses of the drug. Hence, it is recommended that administration of high dose of lorazepam to neurotic patients during pregnancy should be avoided.

REFERENCES

1. Greenblatt DJ, Shader RJ. Benzodiazepines in clinical practice. Raven Press. New York. 1974.
2. Gillies D, Lader M. Guide to the use of psychotropic drugs. Churchill Livingstone. Edinburgh. London. Melbourne and New York. 1986.
3. Muller WX. The benzodiazepine receptor. Cambridge University Press. Cambridge. 1987.
4. Nutt DJ. Benzodiazepine dependence: New insight from basic research. In: Benzodiazepines: Current concepts, biological, clinical, and social perspectives. Eds: I. Hindmarch. G. Beaumont. S. Bandon & B. E. Leonard. JohnViley & sons. Chichester. New York. Brisbane. Toronto. Singapore. 1990.
5. Erickson. CA, Perris R. The role of cell-to-cell and cell-to- matrix interactions in the morphogenesis of the neural crest Dev Biol 1993; 159: 60-74.
6. Harris MJ, McLeod MJ. Eyelid growth and fusion in fetal mouse: A scanning electron microscope study. Anat Embryo 1982; 164: 207-220.
7. Backer KL. Principles and practice of endocrinology and metabolism. Published by J. Blippin Cott Company, Philadelphia. 1st edition 1991; p: 474-77.
8. De Souza. E.B.R.R.G. Anholt. K.M.M. Murphy. S.H. Peripheral type benzodiazepine receptors in endocrine organs: autoradiographic localization in rat pituitary, adrenal and testis. Endocrinology 1985; 116: 567-573.
9. Kozaburo EX, Tanioka M. Teratogenicity of lorazepam. (WY.4036) in mice and rats. Cent Inst Exp Anim Preclin ReR 1975; 1: 25-34.
10. Pelton RW, Hogan BL. Miller DA. Differential expression of genes encoding TGF β 1, β 2, and β 3 during murine palate formation. Dev Biol 1990; 147: 456-460.
11. Abbott BD, Bimbaum LS. Retinoic acid-induced alterations in the expression of growth factors in embryonic mouse palatal shelves. Teratology Teratol 1990; 42: 597-610.
12. Bolande RP. The neurocristopathies: A unifying concept of disease arising the neural crest maldevelopment Human Pathol 1974; 5: 409-422.
13. Jones M. The neurocristopathies: Reinterpretation based upon the mechanism of abnormal morphogenesis. Cleft palate J 1990; 27: 136-140.