

EFFICACY OF TOPICAL RETINOIC ACID COMPARED WITH TOPICAL TRIAMCINOLONE ACETONIDE IN THE TREATMENT OF ORAL LICHEN PLANUS

M. Sahebamee^{*1}, M. Amanlou² and M. Bakhshi³

1) Department of Oral Medicine, Faculty of Dentistry, Tehran University of Medical Sciences, Tehran, Iran

2) Department of Medicinal Chemistry, Faculty of Pharmacy, Tehran University of Medical Sciences, Tehran, Iran

3) Department of Oral Medicine, Faculty of Dentistry, Qazvin University of Medical Sciences, Qazvin, Iran

Abstract- The purpose of this study was to compare the efficacy of retinoic acid 0.05% with triamcinolone acetonide 0.1%, both in an oral base, in the treatment of atrophic and erosive oral lichen planus. Thirty patients with clinically proven oral lichen planus were asked to participate in the study. The severity of lesions was scored from 0 (no lesion) to 5 (large erosion), and symptoms were scored ranging from 100 (asymptomatic) to 0 (impossible to live with symptoms). Patients were randomly assigned to receive either triamcinolone acetonide or retinoic acid. They were instructed to apply the medication on dried lesions four times a day. The signs and symptoms were evaluated after 1, 2, 3 and 4 weeks of treatment. The scores were analyzed by the Wilcoxon rank sum test. The stage of lesions in patients receiving topical triamcinolone acetonide (n=18) improved from an average score of 3.22 to 1.05 after 4 weeks of treatment, whereas patients receiving topical retinoic acid (n=12) showed non-significant improvement (average score 3.41 improved to 3.25). The keratotic areas in 4 patients (22.2%) receiving triamcinolone acetonide and one patient (8.3%) in the retinoic acid group were completely resolved. After 4 weeks of treatment all patients in triamcinolone acetonide group, and 50% of retinoic acid group were asymptomatic. Improvement in symptoms and signs was significantly different in the two groups ($p \leq 0.003$, $p \leq 0.0001$ respectively). The results suggest that in non-keratotic and even keratotic oral lichen planus, topical triamcinolone acetonide 0.1% in oral base reduces the severity of atrophic and erosive oral lesions more effectively than topical retinoic acid 0.05% in oral base.

Acta Medica Iranica, 42(2): 108-113; 2004

Key words: Lichen planus, triamcinolone acetonide, retinoic acid

INTRODUCTION

Oral lichen planus (OLP) is a chronic mucocutaneous disease with an unknown etiology (1). The disease affects 0.5-2% of population with a

predilection for females and a mean age at onset in the fourth to fifth decade (2). OLP appears clinically in at least six forms: reticular, plaque like, atrophic, erosive and bullous lesions that can occur separately or simultaneously (3). The oral lesions are often asymptomatic but the atrophic and erosive form of OLP can cause symptoms ranging from spontaneous soreness to severe pain interfering with eating, speech and swallowing. Histopathologically, OLP shows focal hyperkeratosis, irregular acanthosis,

Received: 14 Sep. 2002, Revised: 23 Jul. 2003, Accepted: 15 Oct. 2003

*** Corresponding Author:**

M. Sahebamee, Department of Oral Medicine, Faculty of Dentistry, Tehran University of Medical Sciences, Tehran, Iran
Tel: +98 21 6112928, Fax: +98 21 6461178
E-mail: amanlou@sina.tums.ac.ir

basal cell liquefaction degeneration, and a dense band-like infiltration of T lymphocytes (1,4). Although the cause of OLP is still unknown, it is well documented that OLP represents a cell-mediated immune response with the infiltrating cell population composed of both T₄ and T₈ lymphocytes (5). Systematic or topical therapies, including corticosteroids, retinoids, immunosuppressive, antimycotics, antimalarial and plant-derived substances such as glycyrrhizin have been used for treatment of OLP (6). The most frequently described therapy for OLP is the administration of topical or systemic corticosteroids. Topical corticosteroid drugs are often the mainstay in the treatment of oral inflammatory diseases. They are effective against inflammation and, more specifically, reduce exudation of leukocytes and formation of soluble inflammatory mediators, while helping to maintain cellular membrane integrity, inhibit phagocytosis and release of lysozymes from granulocytes and stabilize the membranes of lysosomes that contain hydrolytic enzymes. The use of systemic corticosteroids is limited by their side effects (7). The greatest problem of using topical corticosteroids in the mouth is to make them adhere to the mucosa for a sufficient time. For this reason high-potency topical corticosteroids in adhesive pastes appear the safest and most effective treatment for OLP (6) and allow long-term application without systemic side effects. Topical steroids in adhesive bases are more effective than creams or ointment (8). Systemic and topical retinoids have been used to treat OLP (9-11). The retinoids have anti-inflammatory properties, perhaps through their interactions with the arachidonic acid cascade. Retinoids have been noted to have anti-keratinizing and immuno-modulating effects, they stimulate macrophage activation and antibody-dependent cell-mediated cytotoxicity (12). Moreover, retinoids may reduce CD4 lymphocyte infiltration and increase the macrophages in OLP lesions, thus accelerating the healing process (13). For this reason retinol and its synthetic and natural analogues (retinoids) may be useful in the treatment of OLP (6). Unfortunately the systemic use of retinoids is often limited due to their side effects (6). Therefore topical retinoids have been developed and found to produce generally good results in patients with OLP (10). The

immunomodulating effect of a topical retinoids on OLP has been reported by other investigators (6,9,11) and has been successfully used to treat OLP in some cases where corticosteroids had failed to achieve satisfactory results (9). Topical retinoids and corticosteroids have promising effects in the treatment of OLP (6). Retinoic acid has never been compared with triamcinolone acetonide in a clinical trial in Iranian patients. The purpose of our study was to compare the efficacy of retinoic acid in oral base with triamcinolone acetonide in oral base for the treatment of erosive and atrophic OLP.

MATERIALS AND METHODS

Patients

Patients with erosive and atrophic OLP referring to the Oral Medicine Clinic, Faculty of Dentistry, Tehran University of Medical Sciences, were asked to participate in the study. All patients were interviewed for a thorough medical history. Any topical or systemic medication previously prescribed for treatment of OLP was stopped 1 month prior to the study. Women with childbearing potential were excluded unless they were using oral contraceptives. Patients with the diagnosis of OLP based on clinical characteristics (presence of Wickham's striae and lesions in both cheeks) were included in the study. Exclusion criteria consisted of contraindications of corticosteroid use, lesions in contact with corroding dental amalgam, and the use of any drug that could possibly cause lichenoid reaction.

Drugs

The drugs for this study were triamcinolone acetonide 0.1% and retinoic acid 0.05% both in an oral base, prepared in Department of Medicinal Chemistry, Faculty of Pharmacy, Tehran University of Medical Sciences, Tehran, Iran.

Study design

In this double-blind study, patients were randomized to receive triamcinolone acetonide 0.1% (group A) or retinoic acid 0.05% (group B) preparations. The patients were instructed to apply the medication four times daily by means of a finger

on the dried lesions for 4 weeks. The lesions were evaluated after 1, 2, 3 and 4 weeks of treatment. The severity of all lesions were scored prior to the initiation of therapy, and at each visit.

Table 1 shows the score range from 0 to 5 according to the criteria set by Thongprasom et al (14). Stages from 1 to 5 participated in the study. Patients were also instructed to score the intensity of pain on a numerical scale at the beginning and following each visit with the references made to previous scores. Pain scores ranged from 0 (no pain) to 10 (extreme pain).

The investigators remained in contact with the patients to ensure appropriate drug use, to record the results in the questionnaire and to document any adverse reactions. Patients were examined weekly for 4 weeks. Symptoms and signs were evaluated before starting therapy and at the end of every week. The symptoms were scored according to the criteria set by Tel Aviv-San Francisco scale (15,16) (Table 2). The t-test and Wilcoxon rank sum test was used for the analysis of scores. The scores ranged from 0 to 5 according to the criteria set by Thongprasom et al (14). Changes in keratotic areas were also evaluated.

Table 1. Sign stage by Thongprasom

Stage	signs
Score 5	White striae with atrophic area less than 1 cm ²
Score 4	White striae with atrophic area less than 1 cm ²
Score 3	White striae with atrophic area less than 1 cm ²
Score 2	White striae with atrophic area less than 1 cm ²
Score 1	Mild white striae, no erythematous area
Score 0	No lesion, normal mucosa

Table 2. Symptoms stage by Tel Aviv-San Francisco (TASF) scale

Stage	Symptoms
100	Asymptomatic
75	Low level of symptoms, does not interfere with usual daily activity
50	Symptoms interfere with regular daily activity
25	Sore and painful; greatly interferes with regular daily activity
0	Impossible to live with the severe symptoms

RESULTS

Thirty patients (20 women and 10 men) with atrophic, erosive or keratotic OLP participated in the study. The mean age of the patients was 45 years (range 20 to 68 years). The mean duration of lesions was 19 months (range 2 to 84 months). The patients in both groups were similar in age, and location of lesions. Eighteen patients (11 women and 7 men) received triamcinolone acetonide 0.1% (group A) and 12 patients (9 women and 3 men) received retinoic acid 0.05% (group B). The lesions were most commonly found on the mucosa of the cheeks followed by the gingiva, lips and adjacent to the retromolars.

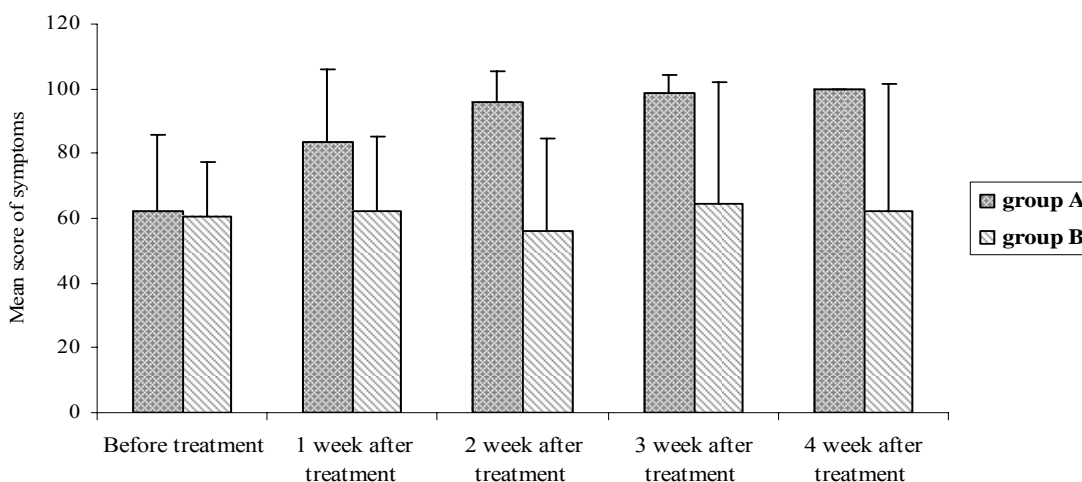


Fig. 1. Mean score of symptoms before and during 4 weeks of treatment. Group A received triamcinolone acetonide 0.1% and group B received retinoic acid 0.05% both in oral base.

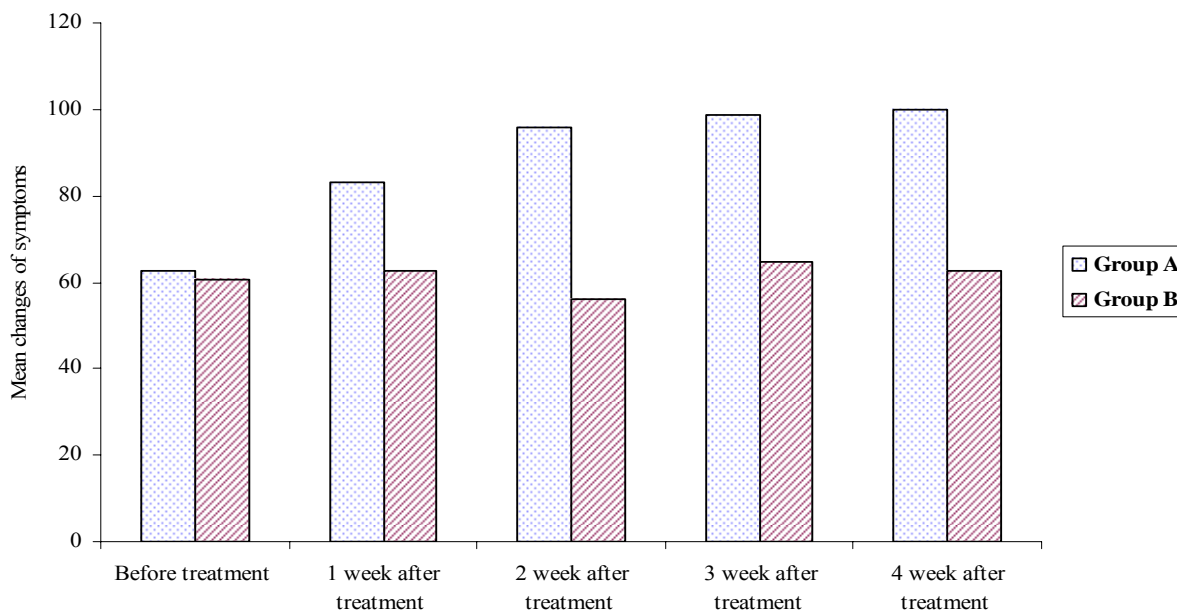


Fig. 2. Mean score of signs before and during 4 weeks of treatment. Group A received triamcinolone acetonide 0.1% and group B received retinoic acid 0.05% in oral base.

Before starting therapy, the average scores of the symptoms were 62.5 in group A and 60.41 in group B. There was no statistically significant difference in the scores of signs between the two groups. At the end of therapy, all patients in group A and 50% of group B were asymptomatic. The mean changes of symptoms before and during 4 weeks of treatment in group A and group B are shown in figure 1. Improvement of clinical signs was noted in 12 patients (66.7%) in group A and patients (33.3%) in group B that reached score 0 or 1 for signs. Patients in group A improved from the average score of 3.22 to 1.05 after 4 weeks of treatment; in group B the average score changed from 3.41 to 3.25. In figure 2, mean changes of the signs before and during 4 weeks of treatment in group A and group B are presented. The changes noted in patients receiving topical triamcinolone acetonide (group A) were significantly greater than those of the group B patients ($P \leq 0.003$ for symptoms and $P \leq 0.0001$ for signs; Fig. 2). Atrophic and erosive lesions showed improvement in the form of complete remission or mild white striae in 9 patients (50%) treated with triamcinolone acetonide (group A).

In group B, atrophic lesions in 3 patients (25%) and erosive lesions in 1 patient (8.3%) improved. Therefore, 8 patients (58.3%) showed no change or

even deterioration of their lesions. Keratotic area decreased in 6 patients (33.3%) and disappeared in 4 patients (22.2%) in group A. Complete remission of keratotic areas in group B was seen in 1 patient (8.3%).

DISCUSSION

In this study triamcinolone acetonide 0.1% was compared to retinoic acid 0.05% in oral base in the treatment of different types of oral lichen planus. Like other studies, the disease was seen more frequently in women (10,15-17). The mean age was 5 years less than other reports (10,15,18). The involvement of gingiva was more frequent than the tongue, whereas in other studies, involvement of the tongue was reported to be more prevalent than the gingiva (6,17). Maximum efficacy of triamcinolone acetonide in the control of symptoms was observed after 4 weeks, but the best clinical outcome was seen during the first week of treatment. The effects of retinoic acid on symptoms were not favorable, and even worsening in some patients. Triamcinolone acetonide was statistically more effective than retinoic acid in the relief of symptoms ($p \leq 0.003$). Triamcinolone acetonide was significantly effective

in the management of signs and 83% of patients showed improvement after 4 weeks. In order to reduce the side effects of retinoic acid, the low dose of the medication was used, similar the study of Buajeeb et al (10). Application (four times daily) of the topical retinoic acid could provide improvement in almost 33.3% of the patients after 4 weeks, while Buajeeb et al (10) reported improvement in 50% of the patients. Giustina et al reported that twice daily application of isotretinoin gel 0.1% for 8 weeks was effective in the improvement of 90% of patients with OLP (19). Significant changes in the clinical appearance of lesions were observed by 4 weeks of treatment, and reticular and plaque-like lesions that decreased in size persisted after 8 weeks of treatment, as reported previously (10,19). Our study showed that triamcinolone acetonide was more effective than retinoic acid in improvement of clinical signs ($P \leq 0.0001$). Our results also supported that triamcinolone acetonide was more effective than retinoic acid on the keratotic areas; this was in contrast with some other studies (1). In a previous study reported by Sahebjamme and co-workers, triamcinolone acetonide could decrease keratotic areas due to its immunomodulatory effects (20). The clinical efficacy of retinoic acid 0.05% was less than triamcinolone acetonide 0.1%. This might be due to different immunomodulating mechanisms in the two drugs. Although anti-inflammatory effects of retinoic acid have been reported, triamcinolone acetonide seem to have a more potent effect on the inflammatory process. In conclusion, the results of this study suggest that topical application of triamcinolone acetonide 0.1% in oral base is safe, and a more effective treatment for oral lichen planus than retinoic acid.

REFERENCES

1. Vincent S, Fotos P. Oral lichen planus. The clinical, historical and therapeutic features of 100 cases. *J Oral Surg Oral Med Oral Pathol* 1990; 70: 165-171.
2. Scully C, El-Kom M. Lichen planus. Review and update on pathogenesis. *J Oral Path Med* 1985; 14: 431-438.
3. Dusek JJ, Frick WG. Lichen planus. Oral manifestations and suggested treatments. *J Oral Maxillofac Surg* 1982; 40: 240-244.
4. Boisnic S, Frances C, Branchet MC, Szpirqlas H, Charpentier YL. Immunohistochemical study of oral lesions of lichen planus. Diagnostic and pathophysiologic aspects. *Oral Surg Oral Med Oral Pathol* 1990; 70: 462-465.
5. Eversol LR. Immunopathology of oral mucosal ulcerative, desquamative, and bullous diseases. Selective review of the literature. *Oral Surg Oral Med Oral Pathol* 1994; 77: 555-571.
6. Carrozzo M, Gandolfo S. The management of oral lichen planus. *Oral Dis* 1999; 5: 196-205.
7. Muzio LL, Valle AD, Mignogna MD, Pannone G, Bucci P, Bucci E, Sciubba J. The treatment of oral aphthous ulceration or erosive lichen planus with topical clobetasol propionate in three preparations: a clinical and pilot study on 54 patients. *J Oral Pathol Med* 2001; 30: 611-617.
8. Ungphaiboon S, Maitani Y. In vitro permeation studies of triamcinolone acetonide mouthwashes. *Int J Pharmaceut* 2001; 220: 111-117.
9. Woo Ty. Systemic isotretinoin treatment of oral and cutaneous lichen planus. *Cutis* 1985; 35: 385-393.
10. Buajeeb W, Kraivaphan P, Poburksa C. Efficacy of topical retinoic acid compared with topical flucinolone acetonide in the treatment of oral lichen planus. *J Oral Surg Oral Med Oral Pathol* 1997; 83: 21-25.
11. Regezi JA, Ellis CN, Stewart JCB, Giustina TA. Histologic changes associated with topical use of isotretinoin on oral lichen planus. *J Oral Surg Oral Med Oral Pathol* 1985; 61: 479-484.
12. Ferguson MM, Simpson NB, Hammersley N. The treatment of erosive lichen planus with a retinoid-estretinate. *Oral Surg Oral Med Oral Pathol* 1984; 58: 283-287.
13. Baudet-Pommel M, Janin-Mercier A, Souteyrand P. Sequential immunopathologic study of oral lichen planus treated with tretinoin and etretinate *Oral Surg Oral Med Oral Pathol* 1991; 71: 197-202.
14. Thongprasom K, Luangjarmekorn L, Sererat T et al. Relative efficacy of flucinolone acetonide compared with triamcinolone acetonide in treatment of oral lichen planus. *J Oral Pathol Med* 1992; 21: 456-458.
15. Silverman SJr, Gorsky M, Lozada-Nur F. A prospective follow study of 570 patients with oral lichen planus: persistence, remission, and malignant association. *Oral Surg Oral Med Oral Pathol* 1985; 60: 30-34.
16. Gorsky M, Raviv M. Efficacy of etretinate (Tigason) in symptomatic oral Lichen Planus *Oral Surg Oral Med Oral Pathol* 1992; 73: 52-55.
17. Scully C, Boeyl M, et al. Update on oral lichen planus etiopathogenesis and management. *Crit Rev Oral Biol Med* 1998; 9: 86-122.

18. Silverman SJr, Gorsky M, Lozada-Nur F, Giannoti K. A prospective study of findings and management in 214 patients with oral lichen planus. *Oral Surg Oral Med Oral Pathol* 1991; 72: 665-670.

19. Giustina TA, Stewart JCB, Ellis Cn, Regezi JA, Annesley T, Woo Ty. Topical application of isotretinoin gel improves oral lichen planus. *Arch Dermatol* 1986; 122: 534-536.

20. Sahebamee M, Rabiee M. Steroid therapy in oral lichen planus. Thesis 1995.