

# MUCOEPIDERMOID CARCINOMA OF THE LARYNX: REPORT OF A RARE LARYNGEAL TUMOR

S. Z. Madani-Kermani

Department of Pathology, Amir Alam Hospital, School of Medicine, Tehran University of Medical Sciences, Tehran, Iran

**Abstract-** Mucoepidermoid carcinoma is a neoplasm of salivary gland origin, and its laryngeal occurrence is extremely rare. This malignant tumor is composed of two distinct cell types, the epidermoid and mucus cells. Prognosis is largely dependent on the histologic pattern. In this report, an extremely rare laryngeal cancer and its clinicopathologic features are described.

*Acta Medica Iranica*, 42(2): 149-150 ; 2004

**Key Words:** Laryngeal mucoepidermoid carcinoma, salivary gland carcinoma, mucoepidermoid carcinoma of the larynx

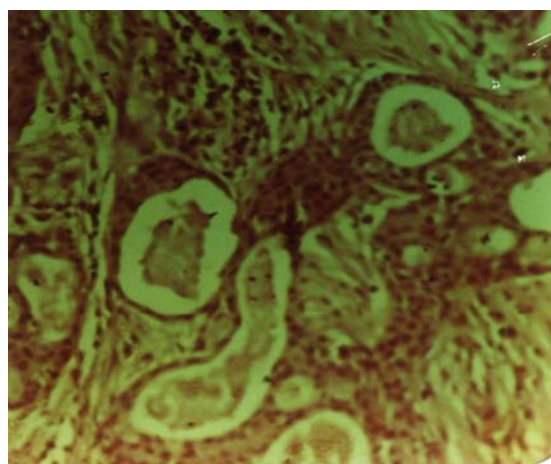
## INTRODUCTION

Mucoepidermoid carcinoma is an exceedingly rare laryngeal neoplasm; to date, less than 100 cases have been reported in the literature (1-4). The tumor occurs between the ages of 45-75 years and may rarely arise in children (5). Men are affected more commonly than women (6,7). Clinical symptoms are similar to those of squamous cell carcinoma (SCC); patients frequently complain of hoarseness, and occasionally of dyspnea. Mucoepidermoid carcinoma of the larynx originates from submucosal glands and may attain a size of up to 5 cm in greatest dimension. The supraglottic area is the most common site involved (8). Microscopically, their appearance is similar to mucoepidermoid carcinoma of the salivary gland. They exhibit two distinct cell types: the mucin-producing and squamous cells in varying proportions arranged in solid or cystic nests. A clear cell type has also been reported (9,10). Architectural patterns vary from largely cystic in low grade to largely solid in high grade tumors. Mucoepidermoid carcinoma has to be differentiated from adenosquamous carcinoma as described by Gerughty et al (11). Adenosquamous

carcinoma is a high grade tumor and biologically aggressive; it is composed of two separate components, adenocarcinoma and squamous carcinoma, and sometimes mixed areas (11).

## Case report

The patient was a 34 year old male who was admitted with the chief complaint of hoarseness and dyspnea of eight months duration. Laryngoscopic examination, revealed irregular lesion involving the left true vocal cord. Excisional biopsy was performed and the pathology report was mucoepidermoid carcinoma (Fig. 1).



**Fig. 1.** Microscopic pattern (44×10) mucoepidermoid carcinoma

Received: 18 Dec. 2002, Revised: ---, Accepted: 16 Apr. 2003

### Corresponding Author:

S. Z. Madani-Kermani, Department of Pathology, Amir Alam Hospital, School of Medicine, Tehran University of Medical Sciences, Tehran, Iran  
Tel: +98 21 6708103-5, 416

## DISCUSSION

Mucoepidermoid carcinoma must be distinguished from the much more frequent cancer of the larynx, i.e., SCC. The presence of intercellular junctions and keratin production are in favor of the diagnosis of SCC. Additionally, the latter does not usually contain goblet cells as in mucoepidermoid carcinoma.

Our case was a mucoepidermoid carcinoma of intermediate grade, and did not pose any diagnostic difficulty. Mucoepidermoid carcinoma should be graded after careful sampling. Laryngectomy, total or partial, with or without neck dissection, is indicated based on histologic grading. Low grade tumors generally have a good prognosis, but the recurrence rate has been reported to be about 50% in one series (8). The overall 5 year survival rate for all mucoepidermoid carcinomas in the larynx and hypopharynx is reported to be 77% in the series reported by Damiani et al (8).

## REFERENCES

1. Luna MA; Ferlito A. Salivary gland neoplasm In: ed surgical pathology of laryngeal neoplasms, London: Chapman and Hall Medical 1996. p.257-294.
2. Heffner DK. Sinonasal and laryngeal salivary gland lesions. In: Ellis GL, Auclair PL, Gnepp DR, editors. Surgical pathology of salivary glands Philadelphia: WB Saunders: 1991; P: 544-559.
3. Cohen J, Guillaumondegui OM, Batsakis JG, *et al.* Cancer of minor salivary glands of the larynx. Am J Surg 1985; 150: 513-518.
4. Snow RT, Fox AR. Mucoepidermoid carcinoma of the larynx. J am osteopath Assoc 1991; 91:182- 184.
5. Mitchell DB, Humphreys S, Kearn S DB. Mucoepidermoid carcinoma of the larynx in a child. Int J Pediatr Otorhinolaryngol 1988; 15: 211-215.
6. Ferlito A, Recher G, Bottin R. Mucoepidermoid carcinoma of the larynx, A clinicopathologic study of 11 cases with review of the literature ORL. J Otorhinolaryngol Relat Spec 1981; 43: 280- 299.
7. Ho kj, Jones JM, Herrera GA. Mucoepidermoid carcinoma of the Larynx, a light and electron microscopic study with emphasis on histogenesis. South Med J 1984; 77: 190- 195.
8. Damina J, Damiani KA, Hauck K, Hyams vy. Mucoepidermoid adenosquamous carcinoma of the larynx and hypopharynx: A report of 21 cases. Otolaryngol Head Neck Surg 1981; 89: 235- 243.
9. Gomes V, Costapelli L, Cimino G, *et al.* Mucoepidermoid carcinoma of the larynx. Eur Arch Otorhinolaryngol 1990; 248: 31- 34.
10. Seo IS, Warfel KA, Tomich CE, *et al.* Clear cell carcinoma of the larynx. A variant of mucoepidermoid carcinoma, Ann Rhinolaryngol 1980; 89: 168-172.
11. Geraghty RM, Hennigar GR, Brown FM. Adenosquamous carcinoma of the nasal, oral and laryngeal cavities. A clinicopathologic survey of ten cases, Cancer 1968; 22: 1140-1155.

