

THYROID GLAND INVOLVEMENT IN CANCER OF THE LARYNX: A FIVE-YEAR MULTICENTER STUDY

E. Razmpa^{1*}, B. Naghibzadeh² and J.Mehdizadeh¹

1) Department of Otorhinolaryngology, School of Medicine, Tehran University of Medical Sciences, Tehran, Iran

2) Department of Otorhinolaryngology, School of Medicine, Shiraz University of Medical Sciences, Shiraz, Iran

Abstract- Intra-operative management of thyroid gland in laryngeal cancer is controversial. To determine the rate of thyroid involvement in patients with laryngeal cancer treated by radical surgical excision, we reviewed the records during 1996-2000 in Imam Khomeini Hospital, Cancer Institute, and Amir Alam Hospital. We studied several factors such as age, gender, and tumor location, presence of thyroid involvement, tumor staging and tumor grading. Thyroid involvement was confirmed by pathologic findings. Two hundred and eighty patients were included in this study. The results showed that only 4.64% of patients (13 cases of 280) treated by laryngectomy had thyroid involvement. Direct invasion was responsible for thyroid involvement in all cases. It was most prevalent in the sixth decade of life and seen in stages 3 and 4 of laryngeal cancer. Thyroid involvement appeared more in men, and in all cases cancer was squamous cell carcinoma. We recommend limited indications for laryngectomy and thyroid lobotomy, including glottic tumor with subglottic invasion, subglottic tumor, intralaryngeal tumor with transcartilage invasion, tumor of sinus piriformis (in stage 4), glottic and supraglottic tumors stage III or IV, which should be individualized. In suspected cases such as those with abnormal thyroid consistency, the decision should be made during laryngectomy .

Acta Medica Iranica, 42(3): 181-184; 2004

Key words: Laryngeal cancer, thyroid involvement, lobectomy, laryngectomy

INTRODUCTION

Although there are few reports of thyroid involvement from pathologic samples in patients with laryngeal cancer who have undergone laryngectomy (1), it is common to excise the thyroid lobe during laryngeal radical surgical excision (2,3). This protocol may lead to hypothyroidism and if associated with radiotherapy, the probability of hypothyroidism is up to seventy percent (1-3). Although some surgeons believe that leaving a small part of thyroid gland can compensate for its

function, sometimes hypothyroidism occurs despite large tissue remnants of thyroid because of ischemia or fibrosclerotic changes in the remnant tissue. Hypothyroidism is an insidious disease, missed easily and its complications such as cardiac, psychiatric and wound healing disorders may be troublesome. Unnecessary thyroid surgery should therefore be avoided (4,5).

There is no report on this subject from Iran, with few reports from other countries (4-8), and a study on the rate of thyroid involvement in patients treated by laryngectomy seemed necessary. The purpose of this study was determining the rate of thyroid involvement in patients treated by laryngectomy, in order to prevent unnecessary excision of thyroid gland, leading to important complications such as hypothyroidism (9-11).

Received: 6 Apr. 2003, Revised: 5 Nov. 2003, Accepted: 3 Mar. 2004

*** Corresponding Author:**

E. Razmpa, Department of Otorhinolaryngology, Tehran University of Medical Sciences, Tehran, Iran
Tel: +98 21 8724578, Fax: +98 21 8729422
E-mail: info@razmpa.com

MATERIALS AND METHODS

A descriptive retrospective study was performed in the department of otorhinolaryngology in Imam Khomeini Hospital, Amir Alam Hospital and Cancer Institute, Tehran, during 1996-2000.

The records of 280 patients were reviewed for age, gender, tumor location, thyroid involvement and its route, tumor pathology, tumor stage, tumor grade, and involved thyroid lobe. Thyroid involvement was confirmed by pathologic findings

RESULTS

There were 13 (4.64%) cases of thyroid involvement after laryngectomy (Table 1). Thyroid involvement had a higher prevalence in the 6th decade of life, and occurred in stages 3 and 4 of laryngeal cancer (Fig. 1). According to pathologic reports, the thyroid was involved directly and not by metastasis. Laryngeal tumors in the subglottic area invaded thyroid more commonly (Fig. 2). In all cases of thyroid involvement, the laryngeal cancer was

squamous cell carcinoma (SCC). In more than two-thirds of thyroid involvements, only one lobe of thyroid gland was involved. Laryngeal tumors with thyroid involvement were in grade 1 and 2 in more than 90% of our cases.

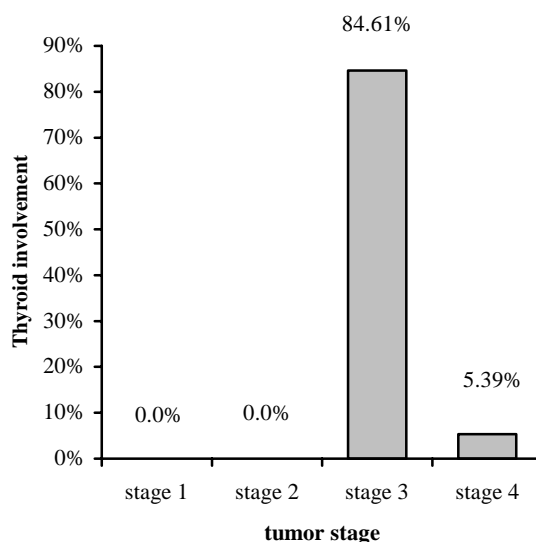


Fig. 1. Relative rate of thyroid involvement according to laryngeal tumor stage.

Table 1. Thyroid involvement in patients treated by laryngectomy

Patient no.	Age	Gender	Tumor location	TNM	stage	grade	No. of involved thyroid lobe	Route of involvement
1	58	male	Glottic	T3N0M0	III	G2	Single lobe	Direct invasion
2	77	male	Glottic	T3N0M0	III	G1	Single lobe	Direct invasion
3	68	male	Glottic	T3N0M0	III	G1	Double lobes	Direct invasion
4	70	male	Glottic	T3N0M0	III	G2	Single lobe	Direct invasion
5	67	male	Glottic	T3N0M0	III	G1	Double lobes	Direct invasion
6	70	male	Glottic	T3N0M0	III	G2	Single lobe	Direct invasion
7	61	male	Glottic/ supraglottic	T4N1M0	IV	G2	Single lobe	Direct invasion
8	43	male	Glottic/ supraglottic	T3N0M0	III	G1	Single lobe	Direct invasion
9	67	male	Glottic/ supraglottic	T4N0M0	IV	G1	Single lobe	Direct invasion
10	66	male	Transglottic	T3N0M0	III	G1	Single lobe	Direct invasion
11	53	male	Subglottic	T3N0M0	III	G2	Single lobe	Direct invasion
12	66	male	Subglottic	T3N0M0	III	G3	Double lobes	Direct invasion
13	60	male	Subglottic	T3N0M0	III	G2	Double lobes	Direct invasion

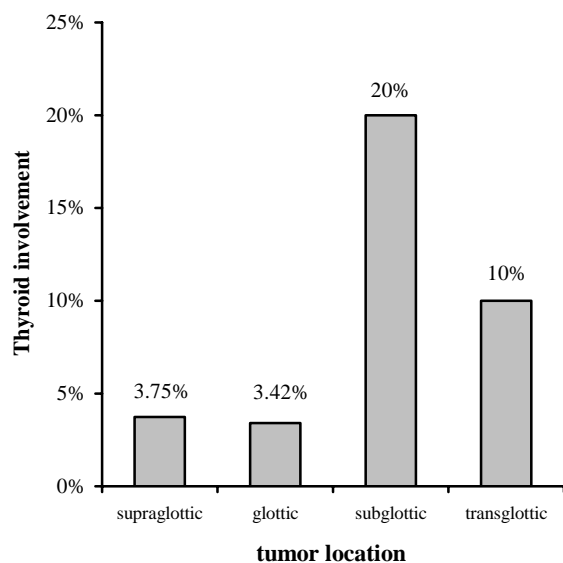


Fig. 2. Relative rate of thyroid involvement according to laryngeal tumor location.

DISCUSSION

This study on thyroid involvement in 280 cases after laryngectomy was performed in the department of otorhinolaryngology in Imam Khomeini Hospital, Amir Alam Hospital and Cancer Institute, Tehran, during 1996-2000 and thirteen (4.64%) cases showed thyroid involvement.

There are a few other reports concerning rate of thyroid involvement in laryngeal cancer (12-17). Croce *et al.* reported 5 cases of thyroid involvement (14.2%) among 35 patients (4). In a study by Gilbert *et al.*, there were 23 (14%) cases in 173 patients (5). Croce *et al.* in another study described 7 (30%) cases with thyroid involvement in 23 patients with laryngeal cancer (6). Brennan *et al.* reported 20 (8%) cases of thyroid involvement among 247 patients (7). Thyroid involvement was found in 18% of patients in Yuen *et al.* study (9) and Biel *et al.* reported a thyroid involvement of 5% among 261 patients (16).

The highest prevalence of thyroid involvement was seen in the 6th decade. Other foreign sources believe that laryngeal cancer has its highest prevalence in the 6th decade of life (8).

The subglottic area was the most common location for laryngeal cancer with thyroid

involvement (20%, 3 of 15 patients). Although glottic area is usually considered as the site with the highest involvement rate, some studies have found subglottic and transglottic areas as the most common involved sites. In a study by Gilbert *et al.*, 21 cases of invasion to the subglottic area were seen among 23 patients (more than 91%) (5). In Yuen *et al.* study, thyroid involvement occurred often in subglottic area (9), and in Brennan *et al.* study, thyroid involvement was seen in the transglottic area in all cases (7).

Thyroid involvement after laryngectomy was seen more commonly in grades 1 and 2 of laryngeal cancer, meaning that thyroid involvement is more prevalent in lower grades. In reference texts, it is noted that subglottic tumors are more differentiated than supraglottic ones and have a lower growth rate.

In reviewed articles, there was no report of tumor grade in thyroid involvement, but references generally believe that the higher the grade of the laryngeal tumor, the more prevalent is thyroid involvement. In our study, among 13 patients with thyroid involvement, 6 cases were in grade 1, 6 in grade 2 and only 1 patient was in grade 3. The thyroid was involved in all cases by direct invasion of laryngeal cancer (Table 1), although metastatic spread has been reported in other series. Invasion of the thyroid gland is seen more rarely than cartilaginous invasion in resected specimens, but aggressive neoplasms can infiltrate the thyroid gland parenchyma (1). In Beil and Maisel's study, direct invasion of the tumor caused thyroid involvement (16). In Gilbert's study 15 cases out of 23 (65.2%) had thyroid involvement because of direct invasion of the tumor (5). In Croce's study, tumors had invaded the thyroid directly in 4 out of 5 cases (4).

Among 13 cases of thyroid involvement after laryngectomy, 11 were classified in stage III and 2 in stage IV (Fig. 1). In a study by Brennan *et al.*, all cases with thyroid involvement were in stages IV and T3, T4 (7). In Gilbert *et al.* study, thyroid involvement occurred in stages III and IV (5).

All 13 cases of thyroid involvement were men. Paparella reported a male to female ratio of 12 to 1 for laryngeal cancer (8). Croce reported thyroid involvement only in men (6). Smolarz *et al.* reported 106 men with laryngeal cancer in comparison with 14 women (18).

Thyroid gland and cancer of larynx

From the 13 cases of thyroid involvement, 9 cases showed single lobe and 4 showed double lobe involvement; in the majority of cases (two thirds) one lobe was involved (Table 1). In other sources, there is no data of the rate of thyroid lobe involvement. In all cases of involvement, the laryngeal tumor was SCC.

According to the provided statistical analysis, and the low rate of thyroid involvement in patients after laryngectomy, we suggest these indications for thyroid lobectomy during laryngectomy:

a) Glottic tumors with distribution of over 1cm of the subglottic area

b) Subglottic tumors

c) Intra laryngeal tumors with invasion of transcartilage

d) Tumors of piriformis sinus in stage IV

e) Glottic and supraglottic tumors stage III or IV
Other cases should be individualized and in suspected cases such as those with abnormal thyroid consistency, the decision should be made during laryngectomy.

To prevent unnecessary excision of the thyroid gland leading to important complications such as hypothyroidism, we suggest saving the thyroid gland in conditions other than those listed above.

REFERENCES

1. Fried MP. The larynx: a multidisciplinary approach. 1st ed, Boston: Little, Brown; 1988. p. 231.
2. Baily BJ, Pazos A. Head and neck surgery-otolaryngology. 3rd ed. Philadelphia: JP Lippincott; 2001.
3. Ballenger JJ, Snow JB. Otolaryngology: head and neck surgery. 15th edition. Philadelphia: Lippincott Williams and Wilkins; 1996.
4. Croce A, Moretti A, Bianchedi M, Boccia MM, de Vincentiis M. Thyroid gland and carcinoma of the hypopharyngeal-laryngeal region. *G Chir.* 1991 ; 12(10): 489-492.
5. Gilbert RW, Cullen RJ, van Nostrand AW, Bryce DP, Harwood AR. Prognostic significance of thyroid gland involvement in laryngeal carcinoma. *Arch Otolaryngol Head Neck Surg.* 1986 ; 112(8): 856-859.
6. Croce A, Moretti A, Bianchedi M. Thyroid gland involvement in cancer of the larynx. *Acta Otorhinolaryngol Ital.* 1991; 11(4): 429-435.
7. Brennan JA, Meyers AD, Jafek BW. The intraoperative management of the thyroid gland during laryngectomy. *Laryngoscope.* 1991 ; 101(9): 929-934.
8. Paparella MM, Shumric DA, Gluckman JL, editors. *Otolaryngology.* 3rd edition. Philadelphia: W.B Saunders, 1991. p. 2314- 2359.
9. Yuen AP, Wei WI, Lam KH, Ho CM. Thyroidectomy during laryngectomy for advanced laryngeal carcinoma -- whole organ section study with long-term functional evaluation. *Clin Otolaryngol.* 1995 ; 20(2): 145-149.
10. Keim WF, Shapiro MJ, Rosin HD. Study of postlaryngectomy stomal recurrence. *Arch Otolaryngol.* 1965; 81: 183-186.
11. Modlin B, Ogura JH. Post laryngectomy tracheal stomal recurrences. *Laryngoscope.* 1969; 79(2): 239-250.
12. Harrison DF. Laryngectomy for subglottic lesion. *Laryngoscope.* 1972; 85: 1208-1210.
13. Tucker G Jr. Some clinical inferences from the study of serial laryngeal sections. *Laryngoscope.* 1963; 73: 728-748.
14. Welsh LW. The normal human laryngeal lymphatics. *Ann Otol Rhinol Laryngol.* 1964; 73: 569-582.
15. Hollinshead WH. *Anatomy for surgeons: the head and neck.* 1st ed. Philadelphia: Lippincott-Raven Publishers; 1982. p. 504.
16. Biel MA, Maisel RH. Indications for performing hemithyroidectomy for tumors requiring total laryngectomy. *Am J Surg.* 1985; 150(4): 435-439.
17. Kasai N, Shinozaki N, Uchida M, Sakamoto A, Hosoya T, Ogawa S. The metastatic patterns of thyroid carcinoma—on the cases with typical local dissection. *Nippon Gan Chiryō Gakkai Shi.* 1979; 14(7): 1116-1121.
18. Smolarz K, Malke G, Voth E, Scheidhauer K, Eckel HE, Jungehulsing M, Schicha H. Hypothyroidism after therapy for larynx and pharynx carcinoma. *Thyroid.* 2000; 10(5): 425-429.