

# ASSESSMENT OF BALLOON VALVULOPLASTY IN COMPARISON WITH SURGICAL VALVOTOMY FOR CONGENITAL AORTIC STENOSIS

P. Akbari Asbagh<sup>\*1</sup> and A. Shahmohammadi<sup>2</sup>

1) Department of Pediatric Cardiology, Imam Khomeini Hospital, School of Medicine, Tehran University of Medical Sciences, Tehran, Iran

2) Department of Pediatrics Cardiology, Shahid Rajaie Heart Hospital, School of Medicine, Iran University of Medical Sciences, Tehran, Iran

---

**Abstract-** Soon after successful results of balloon valvuloplasty in treatment of congenital pulmonary stenosis, use of this technique for relief of congenital aortic stenosis (AS) was attempted in different parts of the world. With the purpose of assessment the value of valvuloplasty in comparison with surgical valvotomy in relief of congenital AS, we retrospectively studied 115 patients with valvar AS, 48 of whom underwent balloon valvuloplasty (mean age 9.63 years), and 67 subjected to surgical aortic valvotomy (mean age 10.32 years), in a six year period from 1991 to 1997 at Rajaie heart hospital. Comparison of balloon valvuloplasty with surgical valvotomy revealed that reduction in the mean pressure gradient in balloon valvuloplasty group was greater than those subjected to surgical valvotomy (73.54 vs. 45.03 mmHg,  $P < 0.0001$ ). Decreased incidence of aortic insufficiency and mortality in balloon valvuloplasty in comparison with surgical valvotomy are other notable points in this study. Although it is difficult to compare the results of the two procedures and determine their different indications, our successful experience with balloon valvuloplasty for congenital AS and the safety of this procedure encourage us to use this technique for the patients with congenital AS more than ever. These results must be supported by future studies.

*Acta Medica Iranica*, 42(4): 289-294; 2004

**Key words:** Congenital aortic stenosis, balloon valvuloplasty, surgical valvotomy

---

## INTRODUCTION

In 1961 Dotter and Judkins for the first time described the use of transluminal technique for treatment of arteriosclerotic obstruction when they dilated a stenotic peripheral vessel (1). Balloon atrial septostomy was introduced by Rashkind and Miller in 1966 (2), and in 1980 Martin *et al.* described the first trial of percutaneous transluminal angioplasty for peripheral pulmonary arterial stenosis (3).

---

Received: 10 July 2001, Revised: 23 Nov. 2002, Accepted: 3 Feb. 2004

**\* Corresponding Author:**

P. Akbari, Department of Pediatric Cardiology, Imam Khomeini Hospital, School of Medicine, Tehran University of Medical Sciences, Tehran, Iran  
Tel: +98 21 927723, Fax: +98 21 2236189  
E-mail: rv\_1980@yahoo.com

In 1982, Kan introduced a transcatheter technique for balloon pulmonary valve dilation (4). Subsequently the first successful balloon valvuloplasty for congenital aortic stenosis (AS) was performed by Lababidi in 1983 (5, 6).

At present, balloon valvuloplasty is considered a useful procedure in primary treatment strategy of patients with congenital AS because its results approximate the results of surgical valvotomy but with less risk and much less morbidity (7-12). Balloon valvuloplasty is the procedure of choice as intermediate palliation for moderate to severe aortic stenosis. If balloon valvuloplasty is contraindicated, surgical valvotomy has a limited role in initial therapy. If balloon valvuloplasty is unsuccessful or contraindicated because of aortic insufficiency (AI),

the Ross operation (removal of the stenotic aortic valve and placement of a pulmonary autograft in the aortic position and a pulmonary homograft in the pulmonary position) would be the treatment of choice (13). In present study we compared the results of balloon valvuloplasty against surgical valvotomy in relief of congenital valvar AS.

## **MATERIALS AND METHODS**

This retrospective study accomplished at Rajaie heart hospital by reviewing existing data in hospital charts of 156 patients who categorized as having congenital AS in a six year period, from 1991 to 1997. The data included here are based on history, physical examination, chest x-ray, electrocardiogram, and Doppler echocardiography (pre and post balloon valvuloplasty and pre and post surgical valvotomy).

As we mentioned earlier, in this study we compared the results of balloon valvuloplasty against surgical valvotomy in relief of congenital valvar AS. All patients had AS at valvular level and AS was documented mainly by the evidences of Doppler echocardiography and catheterization (angiography).

Valvuloplasty was performed in cases with severe stenosis, defined by the presence of a pressure gradient  $>70$  mmHg, detected in catheterization room or derived by echocardiography (14, 15), or when electrocardiographic alterations (of the T wave or ST segment) or clinical symptoms (dizziness and syncope with no other causes, significant chest pain) were present, accompanied by a pressure gradient  $>50$  mmHg (16, 17). The procedure was also performed in neonates or young infants (between 1 and 6 months of age) with AS and severe ventricular dysfunction, independent of the transvalvular gradient, because in these situations gradient is underestimated due to the low systemic cardiac output. We did not perform valvuloplasty in the presence of moderate and severe aortic regurgitation, other associated intracardiac lesions requiring immediate surgery or a hypoplastic left ventricle requiring palliative surgery (18-20).

Balloon valvuloplasty was performed after routine sedation and use of local anesthesia. The classic retrograde femoral route was used; the catheter was

inserted into the femoral artery and advanced to the ascending aorta. After measuring aortic pressure, the catheter was advanced into the left ventricle. Left ventricular pressure was measured and a left ventricular cineangiogram was recorded. A balloon with a diameter 10% smaller than the aortic annulus diameter was chosen and advanced into the left ventricle. A long guidewire was advanced through the catheter and tip of it was passed out. While the tip of the guidewire was kept in the left ventricle, the catheter was removed. The balloon catheter was mounted at the end of the guidewire, inserted into femoral artery and advanced over the wire into the left ventricle. The balloon was rapidly inflated until the waist disappeared and then rapidly deflated (12-15).

Valvotomy was performed after general anesthesia and mid-sternotomy by open commissurotomy, without myomectomy. The commissurotomy was done with cardiopulmonary bypass. The pressure gradient measured across the aortic valve in apical 5 chamber and suprasternal view, using Bemouli equation (pressure gradient =  $4V^2$ ). All patients underwent right and left cardiac catheterization. In some patients with severe AS or severely deformed valve, measurements of left ventricular pressure were unsuccessful. In these cases gradient measurement obtained only by Doppler echocardiography.

We used paired-samples *t* test for comparative measurement of mean pressure gradient across aortic valve, pre and post balloon valvuloplasty as well as pre and post surgical valvotomy. Finally comparison the measurement of these two techniques carried out by independent samples *t* test.

## **RESULTS**

We reviewed data of 156 patients with diagnosis of AS admitted to our hospital from 1991 to 1997. Seventeen patients (10.9%) with subvalvular and 6 (3.9%) with supra-valvular AS were excluded. Of the remaining 133 patients with valvular AS, we excluded 18 patients with severe AI and associated congenital cardiac anomalies.

Among the remaining 115 patients with valvular

aortic stenosis, 67 patients underwent surgical valvotomy and 48 subjected to balloon valvuloplasty. The characteristics of these two groups have been shown in table 1.

The mean ages were  $9.63 \pm 2.84$  and  $10.32 \pm 3.44$  years for balloon valvuloplasty and surgical valvotomy groups, respectively ( $P > 0.05$ ). Mean pressure gradient across the aortic valve before valvuloplasty was  $119.31 \pm 45.19$  mmHg that dropped to  $40.77 \pm 24.72$  mmHg ( $P < 0.001$ ). Mean pressure gradient was  $81.21 \pm 36.01$  mmHg before surgical valvotomy that reached to  $39.18 \pm 26.92$  mmHg after surgery ( $P = 0.001$ ). In comparison between two techniques, the mean gradient reduction was significantly greater in patients who underwent valvuloplasty than those subjected to surgical valvotomy;  $78.54$  vs.  $45.03$ ,  $P < 0.0005$  (Fig. 1).

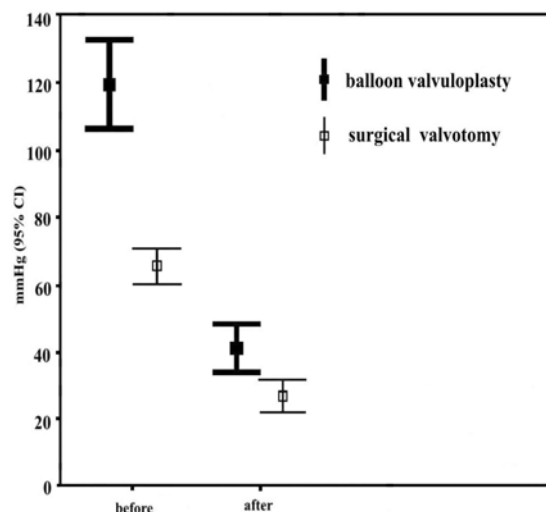
The residual AS after balloon valvuloplasty and after surgical valvotomy at different stages is shown in table 2.

In balloon valvuloplasty group, follow up (mean duration  $\pm$  SD,  $3.6 \pm 1.9$  yr) revealed that 2 patients (4.2%) needed valve replacement and 7 (14.6%) needed repeat balloon valvuloplasty due to occurrence of moderate stenosis. There was no mortality in this group.

In surgical valvotomy group, follow up (mean duration  $\pm$  SD,  $3.4 \pm 2.3$  yr), revealed that 12 (17.9%) needed valve replacement. There were 2 deaths (2.9%) in this group; one patient due to septicemia and brain abscess and the other one because of cerebral hemorrhage secondary to use of warfarin after valve displacement.

**Table 1.** Some characteristics of the studied patients with congenital aortic stenosis

Parameter	Valvuloplasty	Valvotomy
	(n=48)	(n=67)
Pressure Gradient before procedure (mmHg)	119.3 :45.2	81.2 $\pm$ 36.0
Follow up duration (yr)	3.6 $\pm$ 1.9	3.4 $\pm$ 2.3
Range of age (yr)	1-14	4 mo-15
Mean $\pm$ SD of age (yr)	9.6 $\pm$ 2.8	10.3 $\pm$ 3.4



**Fig. 1.** Pressure gradients across the aortic valve before and after balloon valvuloplasty and surgical valvotomy.

## DISCUSSION

Congenital AS is characterized by narrowing of the aortic valve orifice, leading to left ventricular hypertrophy and predisposing the patient to exercise intolerance and myocardial dysfunction.

Valvular AS is the most common type of AS that consists 65 to 75% of left outflow abnormalities and accounts for 3 to 6% of all congenital cardiac anomalies. The male to female ratio is 4:1.

The basic hemodynamic abnormality in left ventricular obstruction is due to pressure gradient across the aortic valve (obstruction level), which is reverse proportional to degree of valvular obstruction (7, 8).

Use of balloon valvuloplasty is a relatively new technique for relief of aortic valve obstruction (21-23). Since the initial description of balloon dilation of the aortic valve in children by Lababidi *et al.* (5), several investigators have reported good short- and medium- term results of balloon aortic valvuloplasty (9-12, 23-27).

For comparing results of valvuloplasty with valvotomy, aside from different indications for these techniques, we must consider many other factors such as patient's age, type and severity of AS, presence of other congenital heart diseases, and especially, duration of follow up (9,28).

## Balloon valvuloplasty in comparison with surgical valvotomy

**Table 2.** Residual Aortic stenosis, post-balloon valvuloplasty and surgical valvotomy\*

Group	Mild AS	Moderate AS	Severe AS
	PG: 25-50 mmHg	PG: 50-75 mmHg	PG> 75 mmHg
Valvuloplasty (n= 48)	24 (50.0%)	8 (16.6%)	6 (12.5%)
Valvotomy (n= 67)	6 (8.9%)	34 (50.7%)	18 (26.8%)

Abbreviations: AS, aortic stenosis; PG, pressure gradient.

\*P value< 0.0005 by chi square test.

The low mortality associated with balloon dilation is relatively similar to that seen with operative valvotomy and at least the primary results of this procedure are similar to surgical valvotomy data (11,29,30). The reduction of pressure gradient is often about 50% or greater and even in 90% of the cases the pressure gradient drops below 50 mmHg (9, 31-35). But creation of AI or progression of mild AI to severe one is common; about 10-38% of patients develop mild to severe AI (7, 9, 36, 37). The mortality in this technique is similar or less in comparison with surgical valvotomy. Deaths have occurred more commonly in the patients with critical AS (38, 39). Mild complications have been reported in 24-27% of the patients; injury to femoral artery is the most common encountered complication (7-8, 40-43).

On the other hand, the standard surgical technique in severe AS after infancy is open valvotomy. Commissurotomy is done with cardiopulmonary bypass. Almost all patients develop significant reduction in pressure gradient and remarkable clinical improvement. However, long terms follow up of these patients has revealed some problems such as residual AS, moderate to severe AI, need of repeat surgery and infective bacterial endocarditic. About two thirds of patients develop moderate to severe AI after valvotomy for congenital valvar AS. According to different studies, the immediate and short time mortality is about 2-9% (44,45) and has been variable in long-term follow up (up to 30 years) between 4 to 33% (28-32).

Gatzoulis *et al.* compared the contemporary results of balloon dilatation and surgery for valvar AS in infants and children in a five year period from 1988 to 1993. Thirty-four children underwent

attempted balloon valvuloplasty (group 1, age 1 day-16 years), eight of whom were neonates with critical AS. During the same period, 17 children underwent direct surgical valvotomy (group 2, seven neonates). Successful balloon valvuloplasty was achieved in 33 (97%) with immediate reduction in the systolic pressure gradient from 82 to 34 mm Hg (mean). There were two deaths in this group (both neonates), the second in a preterm neonate from necrotising enterocolitis. Complications requiring intervention in group 1 were aortic regurgitation in one and femoral artery injury in two. Follow up from four months to five years showed sustained results in most cases. There were two neonatal deaths in the surgical group. When the two groups were compared there was no significant difference in mortality, morbidity, or need for reintervention within 12 months. It is concluded that balloon dilatation for valvar AS is effective and safe for the entire pediatric population and its results compare favorably with those of surgery (25).

In another study, McCrindle *et al.* evaluated outcomes of surgical aortic valvotomy versus transcatheter balloon aortic valvuloplasty in 110 neonates with critical AS in a study by the Congenital Heart Surgeons Society from 1994 to 1999. Mean percent reduction in systolic gradient was significantly greater with balloon valvuloplasty (65±17%) than surgical valvotomy (41±32%  $P<0.001$ ). Important aortic regurgitation was more often present after balloon valvuloplasty (18%) than surgical valvotomy (3%;  $P= 0.07$ ). Time-related survival after valvotomy was 82% at 1 month and 72% at 5 years, with no significant difference for surgical valvotomy versus balloon valvuloplasty, even after adjustment for differences in patient and disease characteristics. In conclusion, they showed that surgical valvotomy and balloon valvuloplasty for neonatal critical AS have similar outcomes. There is a greater likelihood of important aortic regurgitation with balloon valvuloplasty and of residual stenosis with surgical valvotomy (30). Results of other studies showed that use of balloon valvuloplasty postponed demand for surgical valvotomy or valve replacement and could be a substitute for surgery (5, 8, 22).

In our study reduction in the mean pressure gradient in balloon valvuloplasty group was significantly greater than those subjected to surgical

valvotomy (73.54 vs. 45.03 mmHg,  $P < 0.005$ ). By considering that the mean gradient pressure was even greater before valvuloplasty in comparison with surgical valvotomy (119.31 vs. 81.21 mmHg), we believe this difference is very important. Moreover, frequency of AI and mortality in balloon valvuloplasty group were less than those underwent surgery.

This study as well as other studies in this field (5,8,10,13-15), show that presently balloon valvuloplasty is a suitable procedure in primary treatment strategy in patients with congenital AS. Although, it is difficult to compare the results of the two procedures and determine their differential indications, our successful results of balloon valvuloplasty for congenital AS and the advantage of relief safety of this procedure encourage us, more than ever, to use this technique primarily for the patients with congenital AS. Obviously, these results must be supported by future well-conducted studies.

## REFERENCES

- Dotter CT, Judkins MP. Transluminal treatment of arteriosclerotic obstruction. Description of a new technic and a preliminary report of its application. *Circulation*. 1964; 30: 654-670.
- Rashkind WJ, Miller WW. Creation of an atrial septal defect without thoracotomy. A palliative approach to complete transposition of great arteries. *JAMA*. 1966, 196(11): 991-992.
- Martin EC, Diamond NG, Casarella WJ. Percutaneous transluminal angioplasty in non-atherosclerotic disease. *Radiology*. 1980; 135(1): 27-33.
- Kan JS, White RI Jr, Mitchell SE, Gardner TJ. Percutaneous balloon valvuloplasty: a new method for treating congenital pulmonary-valve stenosis. *N Engl J Med*. 1982; 307(9): 540-542.
- Lababidi Z. Aortic balloon valvuloplasty. *Am Heart J*. 1983; 106(4 Pt 1): 751-752.
- Lababidi Z, Wu JR, Walls JT. Percutaneous balloon aortic valvuloplasty: results in 23 patients. *Am J Cardiol*. 1984; 53(1): 194-197.
- Laston LA. Aortic stenosis valvar, supra-valvular and fibromuscular subvalvar. In: Garson AI, Bricker IT, Mc Namara DG, editors. *The science and practice of pediatric cardiology*. 1<sup>st</sup> ed. Lea and Febiger; 1998. p. 1257-1273.
- Fioman EF. Aortic stenosis. In: Adams FH, Emmanouilides GC, editors. *Heart diseases in infants, children and adolescents*. 2<sup>nd</sup> ed. Baltimore: Williams and Wilkins; 1995. p. 439-443.
- Pedra CA, Pedra SR, Braga SL, Esteves CA, Moreira SM, dos Santos MA, Bosisio U, Silva MA, Elias PF, Santana MV, Fontes VF. Short- and midterm follow-up results of valvuloplasty with balloon catheter for congenital aortic stenosis. *Arq Bras Cardiol*. 2003; 81(2): 120-128.
- Mechmeche R, Cherif A, Sassi R, Ezzar T, Boussaada R, Mourali S, Sghaier M, Fajraoui M, Farhati A. Immediate and mid-term results of balloon valvuloplasty in congenital aortic stenosis. Ten case reports. *Tunis Med*. 2002; 80(12): 759-763.
- Gao W, Zhou A, Wang R, Yu Z, Li F, Huang M, Yang J. Percutaneous balloon aortic valvuloplasty in the treatment of congenital valvular aortic stenosis in children. *Chin Med J (Engl)*. 2001; 114(5): 453-455.
- Echigo S. Balloon valvuloplasty for congenital heart disease: immediate and long-term results of multi-institutional study. *Pediatr Int*. 2001; 43(5): 542-547.
- Hsu DT. Congenital valvar aortic stenosis. *Curr Treat Options Cardiovasc Med*. 1999; 1(4): 335-340.
- Rao PS. Balloon valvuloplasty for aortic stenosis. In: Rao PS, editor. *Transcatheter therapy in pediatric cardiology*. 1<sup>st</sup> ed. New York: Wiley-Liss; 1993. p. 105-127.
- Yeager SB, Flanagan MF, Keane IF. Catheter interventions: balloon valvotomy. In: Lock JE, Keane IF, Perry SB, editors. *Diagnostic and interventional catheterization in congenital heart disease*. 2<sup>nd</sup> ed. Boston: Kluwer Academic Publishers; 1999. p. 151-178.
- Beekman RH, Rocchini AP, Gilon JH, Mancini J. Hemodynamic determinants of the peak systolic left ventricular-aortic pressure gradient in children with valvar aortic stenosis. *Am J Cardiol*. 1992; 69(8): 813-815.
- Lima VC, Zahn E, Houde C, Smallhom J, Freedom RM, Benson LN. Non-invasive determination of the systolic peak-to-peak gradient in children with aortic stenosis: validation of a mathematical model. *Cardiol Young*. 2000; 10(2): 115-119.
- Rhodes LA, Colan SD, Perry SB, Jonas RA, Sanders SP. Predictors of survival in neonates with critical aortic stenosis. *Circulation*. 1991; 84(6): 2325-2335.
- Leung MP, McKay R, Smith A, Anderson RH, Arnold R. Critical aortic stenosis in early infancy. Anatomic and echocardiographic substrates of successful open valvotomy. *J Thorac Cardiovasc Surg*. 1991; 101(3): 525-526.
- Lofland GK, McCrindle BW, Williams WG, Blackstone EH, Tchervenkov CI, Sittiwangkul R, Jonas RA. Critical aortic stenosis in the neonate: a multi-institutional study of management, outcomes and risk factors. *Congenital Heart Surgeons Society. J Thorac Cardiovasc Surg*. 2001; 121(1): 10-27.

## Balloon valvuloplasty in comparison with surgical valvotomy

21. Radteke W, Lock J. Balloon dilation catheters. *Pediatr Clin North Am.* 1990; 37(1): 193-213.
22. Sullivan ID, Wren C, Bain H, Hunter S, Rees PG, Taylor JF, Bull C, Deanfield JE. Balloon dilatation of the aortic valve for congenital aortic stenosis in childhood. *Br Heart J.* 1989; 61(2): 186-191.
23. Walls JT, Lababidi Z, Curtis JJ, Silver D. Assessment of percutaneous balloon pulmonary and aortic valvuloplasty. *J Thorac Cardiovasc Surg.* 1984; 88(3): 352-356.
24. Yamaguchi M. Congenital aortic stenosis. *Nippon Geka Gakkai Zasshi.* 2001; 102(8): 595-601.
25. Gatzoulis MA, Rigby ML, Shinebourne EA, Redington AN. Contemporary results of balloon valvuloplasty and surgical valvotomy for congenital aortic stenosis. *Arch Dis Child.* 1995; 73 (1):66-69.
26. Marcon F, Michalski H, Weber JL, Worms AM. Mid-term results of balloon percutaneous valvuloplasty in the treatment of aortic valve stenosis in children and adolescents. *Arch Mal Coeur Vaiss.* 1993; 86(5): 563-569.
27. Demkow M, Ruzyllo W, Ksiezzycka E, Szaroszyk W, Lubiszewska B, Przyluski J, Rozanski J, Wilczynski J, Hoffman P, Rydlewska-Sadowska W. Long-term follow-up results of balloon valvuloplasty for congenital aortic stenosis: predictors of late outcome. *J Invasive Cardiol.* 1999; 11(4):220-226.
28. Brown JW, Ruzmetov M, Vijay P, Rodefeld MD, Turrentine MW. Surgery for aortic stenosis in children: a 40-year experience. *Ann Thorac Surg.* 2003; 76(5): 1398-1411.
29. Elshershari H, Alehan D, Demircin M, Pasaoglu I, Bilgic A. Surgical outcome of congenital valvar aortic stenosis. *Turk J Pediatr.* 2002; 44( 4): 304-311.
30. McCrindle BW, Blackstone EH, Williams WG, Sittiwangkul R, Spray TL, Azakie A, Jonas RA. Are outcomes of surgical versus transcatheter balloon valvotomy equivalent in neonatal critical aortic stenosis? *Circulation.* 2001; 104 (12 Suppl 1): I 152-158.
31. Dettler C, Fischlein T, Feldmeier C, Nollert G, Reichart B. Aortic valvotomy for congenital valvular aortic stenosis: a 37-year experience. *Ann Thorac Surg.* 2001; 71(5): 1564-1571.
32. Alexiou C, Langley SM, Dalrymple-Hay MJ, Salmon AP, Keeton BR, Haw MP, Monro JL. Open commissurotomy for critical isolated aortic stenosis in neonates. *Ann Thorac Surg.* 2001; 71(2): 489-493.
33. Rao PS, Thapar MK, Wilson AD, Levy JM, Chopra PS. Intermediate-term follow-up results of balloon aortic valvuloplasty in infants and children with special reference to causes of restenosis. *Am J Cardiol.* 1989; 64(19): 1356-1360.
34. Moore P, Egito E, Mowrey H, Perry SB, Lock JE, Keane JF. Midterm results of balloon dilation of congenital aortic stenosis : predictors of success. *J Am Coll Cardiol.* 1996; 27(5): 1257-1263.
35. Mccrindle BW. Independent predictors of immediate results of percutaneous balloon aortic valvotomy in children. *Valvuloplasty and Angioplasty of Congenital Anomalies (VACA) Registry Investigators.* *Am J Cardiol.* 1996; 77(4): 286-293.
36. Somerville L. Aortic stenosis and incompetence. In: Anderson RH, McCartney FI, Shinebourne EA, Tynan M, editors. *Pediatric cardiology.* 1<sup>st</sup> ed. Edinburgh: Churchill Livingstone; 1987. p. 977.
37. Vogel M, Benson LN, Burrows P, Smallhorn JF, Freedom RM. Balloon dilatation of congenital aortic valve stenosis in infants and children: short term and intermediate results. *Br Heart J.* 1989; 62(2): 148-153.
38. Fyler DC, Nadas AS. *Nadas' pediatric cardiology.* Philadelphia: Hanley and Belfus; 1992. p. 493-512.
39. Waller BF, Girod DA, Dillon JC. Transverse aortic wall tears in infants after balloon angioplasty for aortic valve stenosis: relation of aortic wall damage to diameter of inflated angioplasty balloon and aortic lumen in seven necropsy cases. *J Am Coll Cardiol.* 1984; 4(6): 1235-1241.
40. Witsenburg M, Cromme-Dijkhuis AH, Frohn-Mulder IM, Hess J. Short- and midterm results of balloon valvuloplasty for valvular aortic stenosis in children. *Am J Cardiol.* 1992; 69(9): 945-950.
41. Perry SB, Zeevi B, Keane JF, Lock JE. Interventive catheterization of left heart lesions, including aortic and mitral valve stenosis and coarctation of the aorta. *Cardiol Clin.* 1989; 7(2): 341-349.
42. Sholler GF, Keane JF, Perry SB, Sanders SP, Lock JE. Balloon dilation of congenital aortic valve stenosis. Results and influence of technical and morphological features on outcome. *Circulation.* 1988; 78(2): 351-360.
43. Abdolrezaq K. Results of balloon dilation of congenital aortic stenosis in Shahid Rajaie hospital in 1991-1992. Tehran: Iran University of medical sciences publication; 1992.
44. Lawson RM, Bonchek LI, Menashe V, Starr A. Late results of surgery for left ventricular outflow tract obstruction in children. *J Thorac Cardiovasc Surg.* 1976; 71(3): 334-341.
45. Sandor GG, Olley PM, Trusler GA, Williams WG, Rowe RD, Morch JE. Long-term follow-up of patients after valvotomy for congenital valvular aortic stenosis in children: a clinical and actuarial follow-up. *J Thorac Cardiovasc Surg.* 1980; 80(2): 171-176.