

## A Case of Cystic Arrhenoblastoma of the Ovary

*Jehan S. Saleh, B.A., M. D.<sup>1</sup>*

---

**T**he arrhenoblastomata are the chief masculinizing neoplasma of the ovary. This type of ovarian neoplasm was first described by Robert Myer (1930) and it was called arrhenoblastoma because of its masculinizing effect on the patient. Arrhenoblastoma of the ovary is most frequently encountered during the second and third decades of life. The oldest recorded case in literature is sixty, and the youngest sixteen years of age.

According to Robert Myer these masculinizing neoplasms are derived from certain male directed cells which persist in ovary from the early stages of gonadogenesis. These interesting ovarian neoplasms show a wide variety in their histologic pattern. On the basis of this wide histologic variation they have been divided into three types. At one extreme, are the typical or highly differentiated tumors, the so called «Testicular Adenomas», and at the other, the undifferentiated or atypical forms, resembling the histological structure of sarcoma. The third form which holds an intermediate position between the two extremes, presents both tubular areas resembling those seen in the typical cases as well as the sarcoma-like tissue associated with atypical tubules.

The undifferentiated atypical arrhenoblastoma is associated with the most pronounced masculinizing effects. These neoplasms vary in

---

(1) Prof. of Gynecology, Faculty of Medicine, Tehran University.

size from a walnut to the size of a human head. Usually such tumors are hard in consistency, but the case under discussion was mostly cystic, and somewhat firm and solid in the region of the hilum.

The degree of masculinization produced by these tumours is inversely proportional to the maturity of the tubules. In other words, the highly differentiated neoplasms which are composed of perfectly formed tubules do not show masculinizing effects, while the undifferentiated or atypical forms rise to varying degrees of heterosexual manifestations.

#### CASE REPORT

A nineteen year old girl referred to my private clinic complaining of amenorrhea, unusual growth of hair all over the body, deepening of the voice, and atrophy of the breasts. Her first menstrual period started at the age of thirteen, and lasted from four to five days. Her periods had been quite regular until two years ago, when the flow started to diminish and stopped entirely within a few months. This episode was coincidental with a trip to the south where she developed typhoid fever and the doctors had contributed the amenorrhea to her sickness at the time. The persistence of amenorrhea together with local symptoms of pelvic discomfort and defeminization; abundant growth of hair and gradual deepening of voice had induced her to seek medical advice. On examination it was quite evident that her feminine body contours were quite lost and masculinized. The head hair was rather thin, while the abundance of hair on the face and the body was striking and profuse. The patient's eyebrows were thick and bushy and her features quite coarse and heavy. The skin was thickened and pigmented, and on the whole, she gave the impression of a swarthy male. Her skeletal changes included an alteration of the body framework with development of the male type of pelvis. The external genitalia were normal except for a hypertrophied clitoris which measured about five centimeters in length. According to the patient's story, the growth of her clitoris had been gradual in the past two years.

Pelvic examination revealed a normal uterus in anteflexion with

a large mass in the left adnexa, about the size of a grapefruit, somewhat fixed and attached to the side of the uterus. No masses were felt on the right side. Physical examination in general was otherwise non-contributory. Blood chemistry and urine analysis were normal except for 17 Ketosteroids in the urine which had increased to 19 mg. in a liter. Considering the sexual reversion in a previously normal female and the presence of a large palpable ovarian mass, a diagnosis of arrhenoblastoma of the ovary was made and the patient was operated under general anaesthesia on August 5, 1956. A midline incision was made, the pelvis explored, and a large ovarian mass  $30 \times 20$  cm. in size was found deep in the pelvis on the left side, somewhat adherent to the uterus, but otherwise mobile. This mass was removed easily, and the other pelvic organs inspected and found to be absolutely normal. Abdominal exploration revealed no abnormal findings.

#### PATHOLOGICAL FINDINGS

**GROSS :** The surface of the tumour was smooth and lobulated in one place. A thin capsule had covered a rather cystic mass which was only firm and hard in a small portion. On section, the solid area was firm in consistency, yellowish in color, and scattered areas of necrosis could be seen. This tumour was macroscopically atypical, being mostly cystic in consistency. The inner cyst walls were lined with a rather smooth but somewhat irregular membrane. The cyst contained a light straw colored clear fluid. (Figs. 1, 2, 3).

**MICROSCOPIC :** Microscopic examination by the University Pathologists, Drs. Armine and Shamssa, showed a tumour composed of solid cords of cells. The connective tissues surrounding the tubules were rather oedematous and contained a few spindle cells isolated and in groups. Some of the cells resembled the interstitial cells of Leydig. (Figs. 4, 5, 6, 7, 8).

This patient had an uneventful post-operative recovery and was discharged after ten days. She has referred to the Clinic only once since the time of her operation. A remarkable change in the reduction

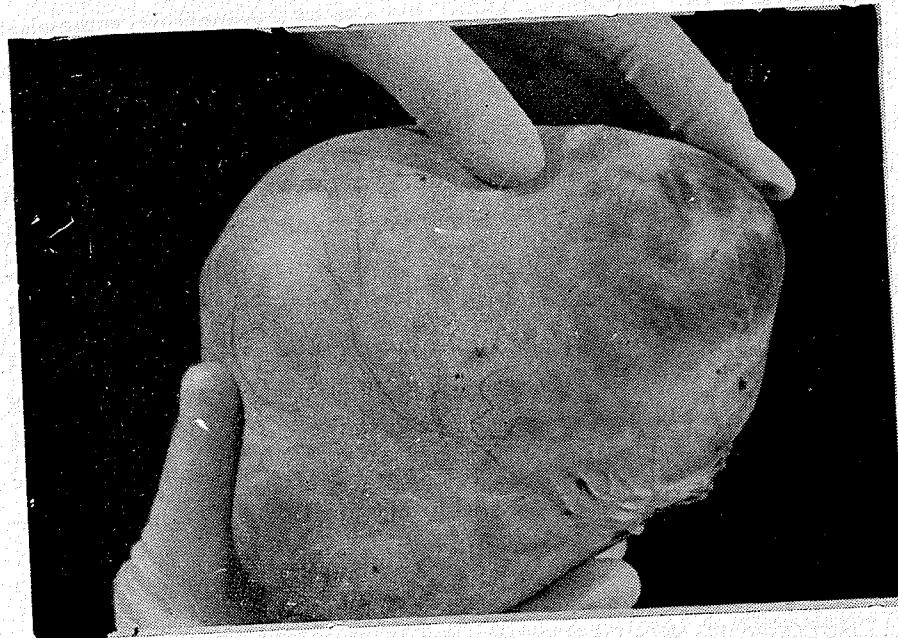


Fig. 1.— Gross picture of the cystic arrhenoblastoma.



Fig. 2.— Gross picture of another surface showing hilum of the ovary.



Fig. 3.— Section of the tumour showing cystic formation with microcysts projecting into the lumen of the larger cysts.

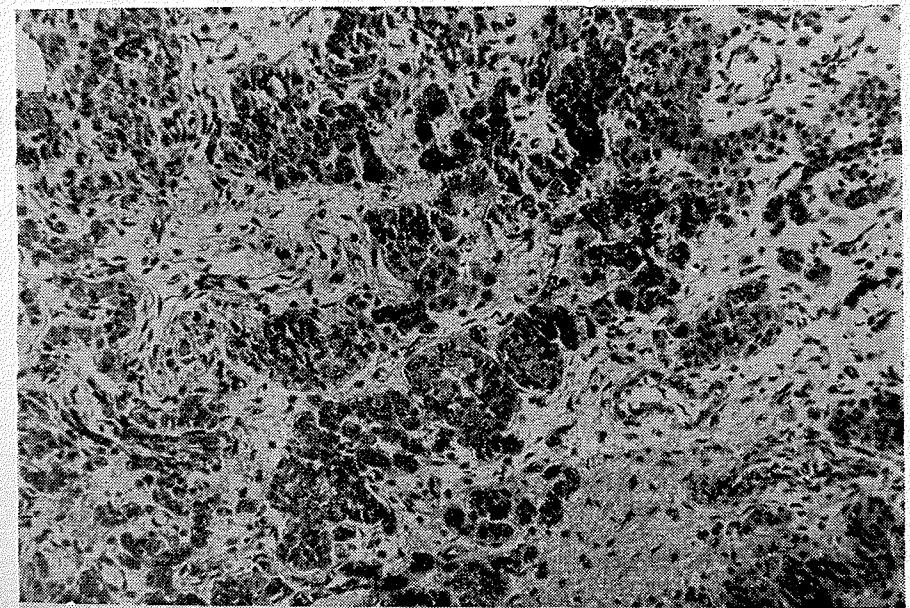


Fig. 4.— Microscopic picture (low power) showing mainly a tubular arrangement.



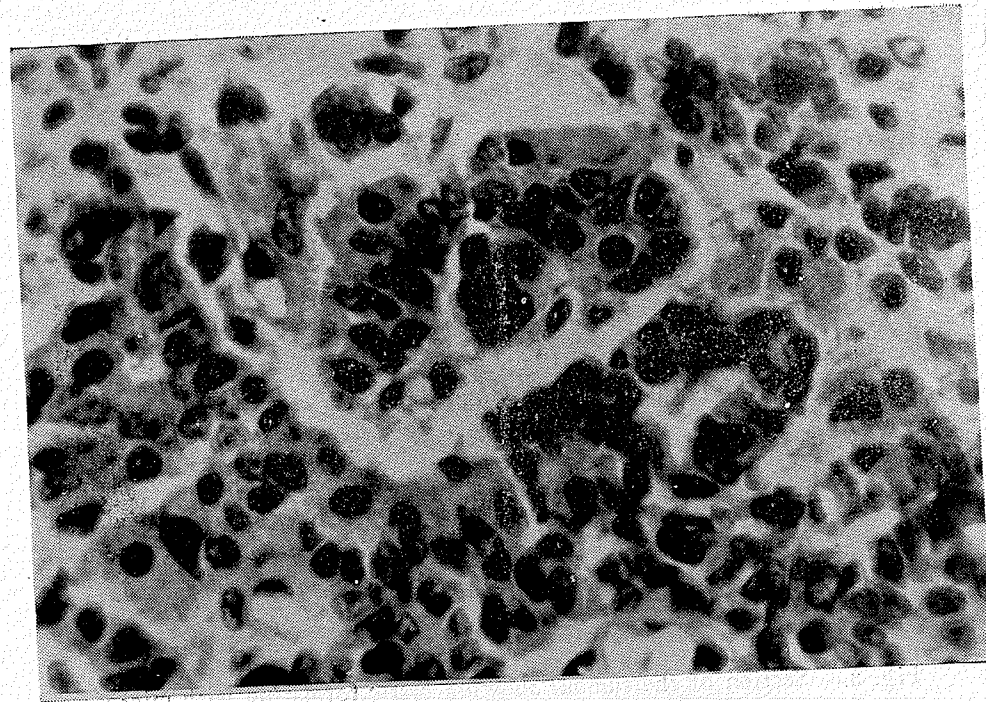


Fig. 5.—Microscopic picture (high power).

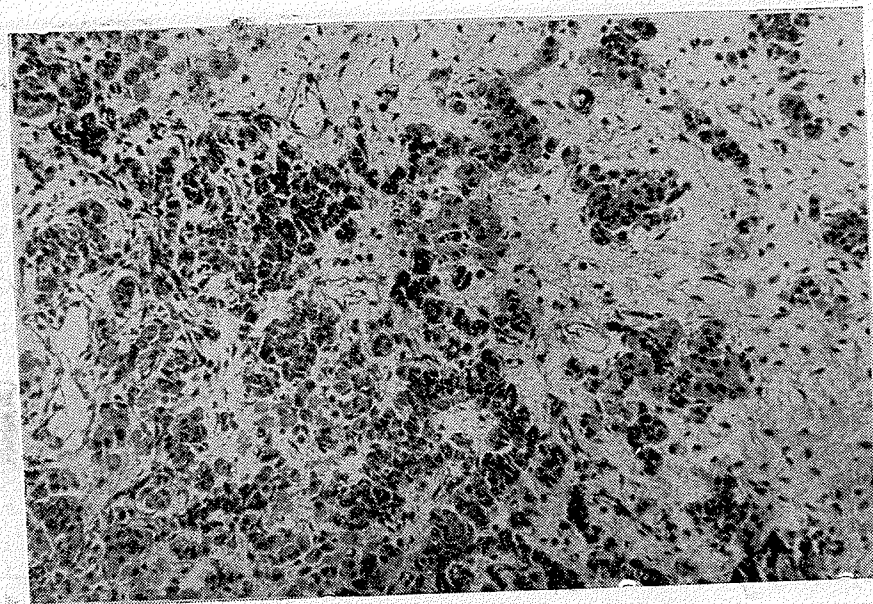


Fig. 6.— Cord like arrangement of cells in island form with imperfect tubule formation. Two types of cells are differentiated:  
 a) cells containing lipid, and resembling the interstitial cells of Leydig.  
 b) basophilic Sertoli cells.

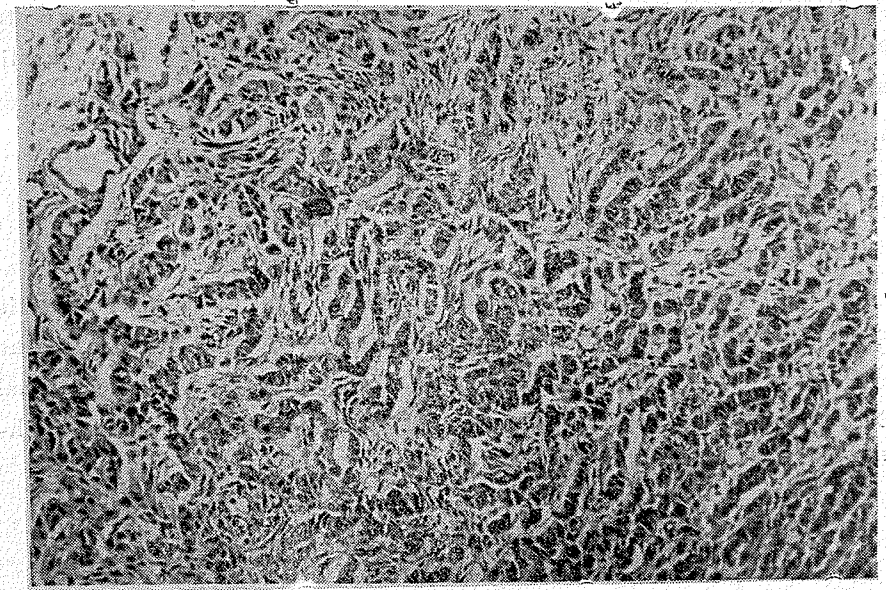


Fig. 7.— The tumour is composed of solid cords of cells.

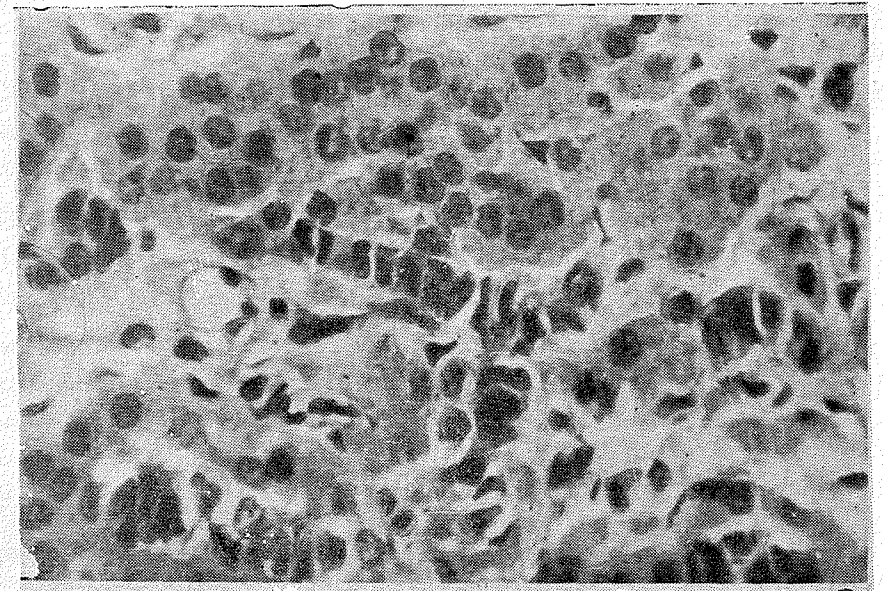


Fig. 8.— Microscopic picture (high power). The interstitial cells of Leydig are seen.

liale où la consanguinité joue un rôle important, comme le confirme notre observation. Des observations assez nombreuses ont attesté que cette affection était en relation avec les pseudo-xanthes élastiques de la peau et d'autres dégénérescence vasculaires de la choroïde accompagnées d'élastose sénile, de diabète ou de maladie de Paget.

Les stries angioïdes de la rétine, toujours bilatérales, sont situées dans les couches profondes de la rétine, et les lésions vasculaires jouent un grand rôle dans ce syndrome.

En définitive, la strie angioïde semble devoir être considérée comme la manifestation d'une lente dégénérescence du tissu élastique de la lame vitrée de Bruch.

Nous avons eu l'occasion de suivre un jeune malade dont nous vous citons l'observation.

M. Y.K., 20 ans, se présente à notre service pour une baisse progressive de la vision. Le fond d'œil droit a montré quelques anneaux gris ardoisé et gris foncé situés à quelque distance autour de la papille. A première vue, nous avons failli les prendre pour des vaisseaux, surtout à cause de leur disposition radiée, mais ils n'en avaient ni la couleur, ni le calibre régulier. Leur prolongement irrégulier atteignait la périphérie de la rétine. Ces trajets pigmentés aux bords encochés donnaient l'impression de dents de scie irrégulières (Planche I, fig. 1). Plus loin, par endroits, ces lignes angioïdes se rejoignaient et formaient des arcs irréguliers, en forme d'hexagones ou en nids d'abeilles (Planche I, fig. 2); elles présentaient ailleurs des aspects très irréguliers. Un large trait pigmenté, en forme de croissant, entourait le bord temporal de la papille. Quelques lacunes pigmentées étaient irrégulièrement disséminées dans les autres parties de la rétine.

Au fond de l'œil gauche, la papille semblait légèrement pâle, et un demi-cercle d'exsudat gris-blanc entourait la macula avec quelques points d'hémorragie (Planche II, fig. 1):

Outre les pigmentations angioïdes caractéristiques, on notait quelques taches d'hémorragie de différentes étendues dans les régions supéro-externe et supéro-interne de la papille, le long de la branche nasale supérieure de l'artère centrale et à la partie temporale inférieure (Planche II, fig. 2). La rétine semblait œdématisée surtout au-dessous

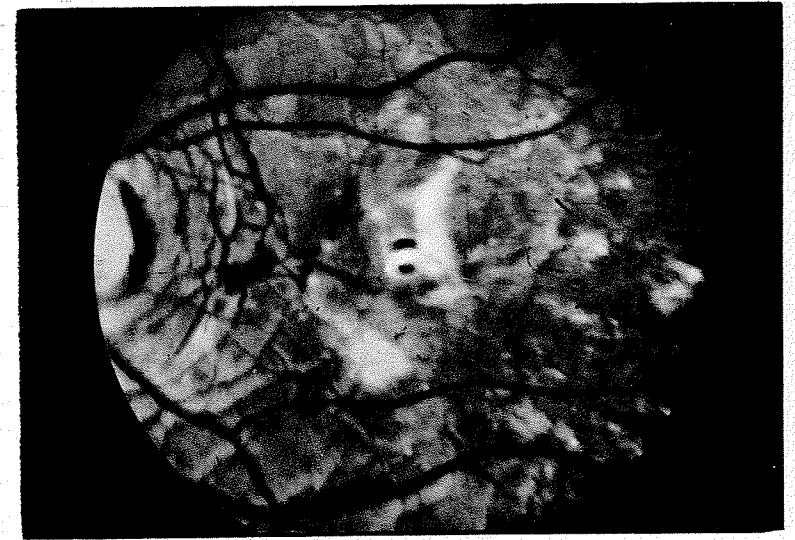

Fig. 1

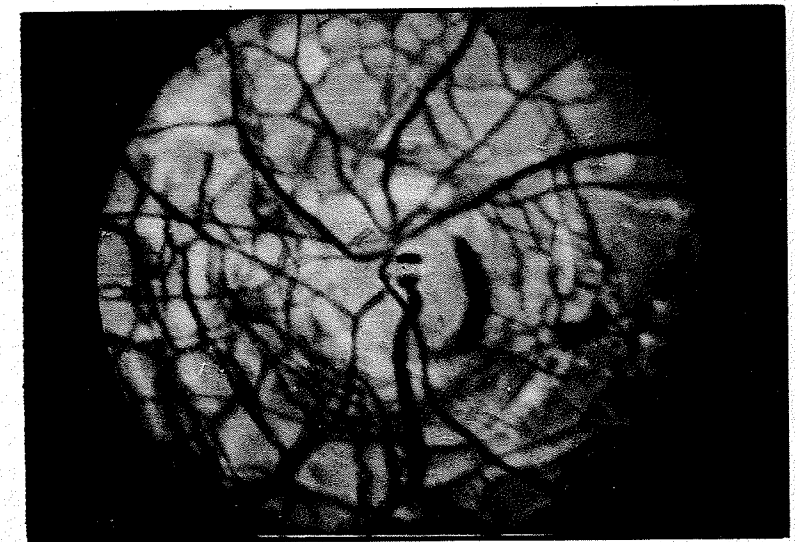


Fig. 2

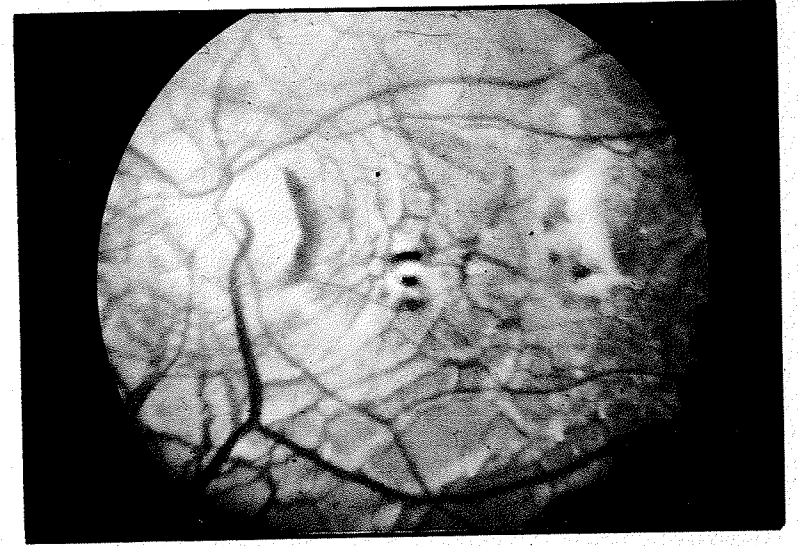


Fig. 1

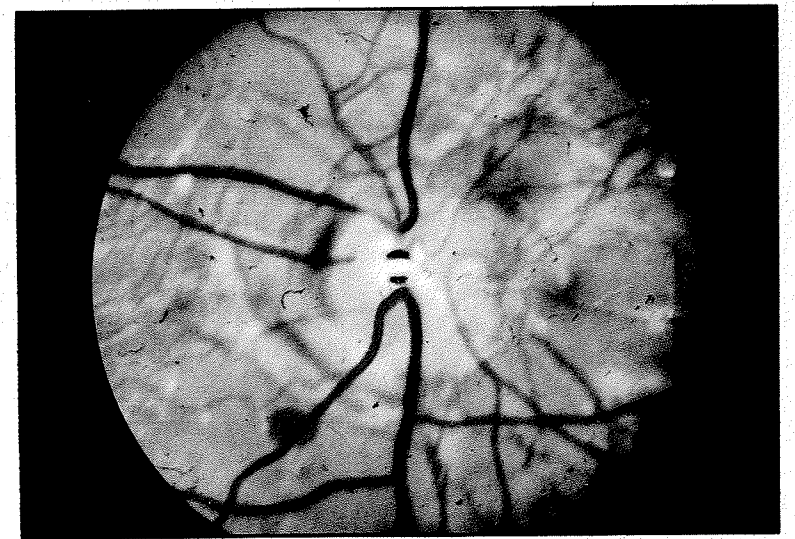


Fig. 2

2



de la papille. On remarquait également une légère artérite sur l'une des branches nasales à une certaine distance du bord interne de la papille.

Né de parents consanguins, notre jeune malade présentait aussi des manifestations cutanées surtout sous forme de pseudo-xanthome élastique ou de sclérodermie, situées surtout sur le cou, aux creux axillaires, aux plis de laine, dans la région interne des cuisses et aux creux poplités (Planche III, fig. 1, 2 et 3). La peau d'aspect parcheminé présentait en outre de petits éléments jaunâtre faisant saillie comme une tête d'épingle. D'autres examens cliniques et de laboratoires n'ont rien signalé.

Il s'agit donc d'une affection et d'une dégénérescence diffuse du tissu élastique qui touche en même temps la lame vitrée, et la région maculaire. Si à un moment donné, cette dégénérescence se manifestait juste dans la macula, elle donnerait lieu à une lésion du même type que la dégénérescence maculaire sénile de Danis et Copez.

En conclusion, nous pouvons dire que les vraies stries angioïdes sont la manifestation d'une dégénérescence des fibres élastiques dans le cadre de l'élastorrhexie systématisée. La consanguinité et l'hérédité paraissent jouer un rôle très important dans cette affection qui se manifeste à l'âge moyen de la vie. Au cas où les stries se trouvent associées à un pseudo-xanthome, on est en présence du syndrome de Gromblad - Standberg, compliqué parfois d'altérations vasculaires et qui semble devoir être classé dans le groupe des affections mésodermiques familiales. Cependant, à côté de cette affection, il est possible de rencontrer des stries d'aspect très semblable indiquant des lésions qui frappent également la vitrée choroïdienne mais dont l'étiologie est différente.

#### RÉSUMÉ

Les auteurs ont suivi un malade dont la vision avait lentement baissé. Ils en décrivent les altérations trouvées à l'examen ophtalmologique et portent le diagnostic de stries angioïdes de la rétine.

Le malade présentait également des lésions cutanées qui montraient l'existence d'une affection générale.

Pour terminer, les auteurs ont décrit les formes associées de la strie angioïde de la rétine et son rapport avec d'autres affections mésodermiques familiales.

SUMMARY

The authors have observed one patient whose vision has slowly been lessened. They have written all the ophthalmoscopic changes which would help in diagnosis of a angioïd striæ of the retina.

The patient showed some skin lesions as well, which proved the existence of a general affection.

At the end, the authors have written all the associated forms of the disease and other familial and mesodermic affections which may be seen with it.

BIBLIOGRAPHIE

- Bailliant-Traité d'opht. 1939, T.V. 391.
- Balzer-Arch. de phy. 1884.
- Bonnet-Arch. opht. 1935. 225.
- Bonnet, P. -Stries angioïdes de la rétine- S.F.O. 1938, 516-520.
- Bonnet et Paufique- B.S.O.P. 1934, 222.
- Duke Elver-Text Book of Oph. 1945, III, 2413.
- Francheschetti et Roulet-Stries angioïdes de la rétine S.F. O. 1935, 416.
- Gromblad-Acta-opht. 1929.
- Lopes d'Andrade-B.S.O.P. 1940, 41.
- Montiho H. S.F.O. 1947-228.
- Renard-Rapport S.F.O. 1946.
- Touraine-Presse médicale 2.5-Avril 1941, 361.
- Vignalon-Extension des stries angioïdes de la rétine, Bul. S.O.F. 1954, 454.
- Voisin et G. Lombard-Pseudo-xanthome élastique et lésions maculaires sans stries angioïdes, S.F.O. 1954, III.

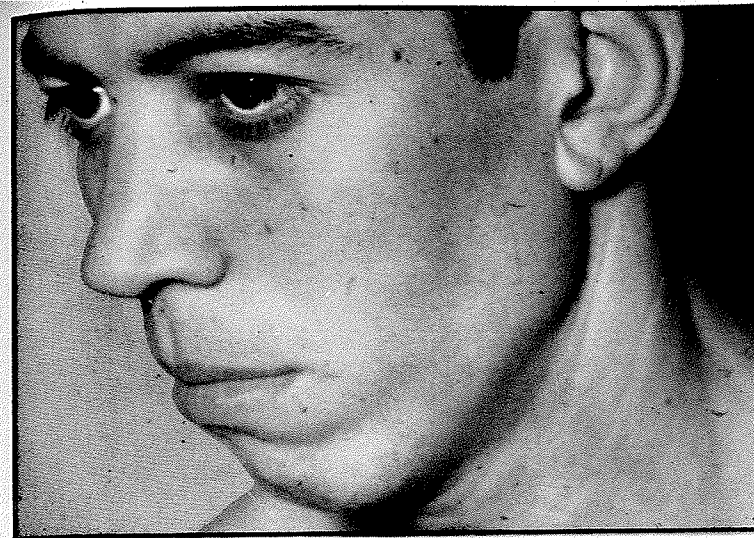


Fig. 1

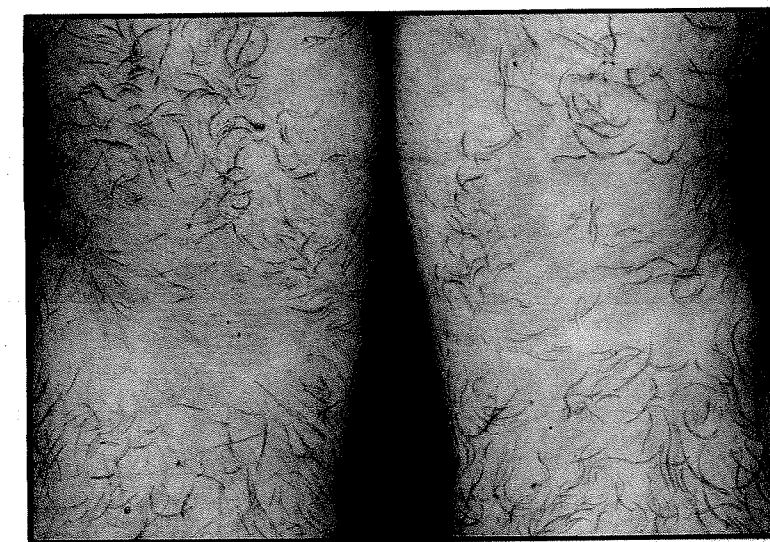

Fig. 2

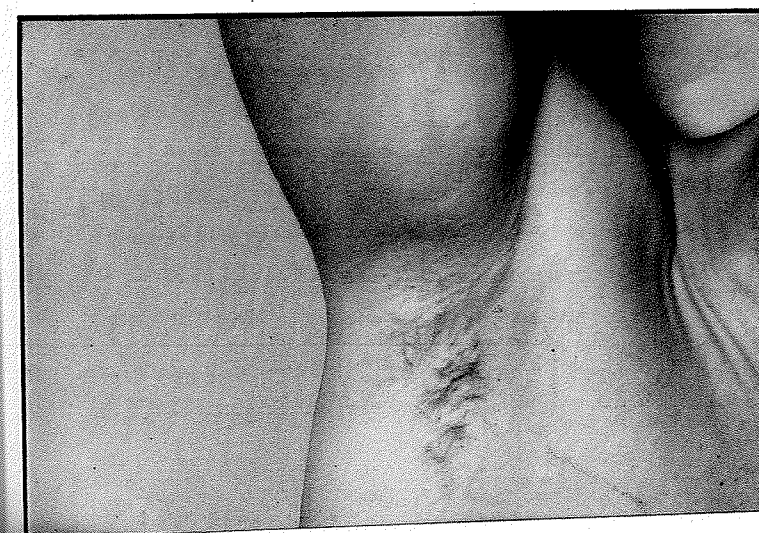

Fig. 3