

# MANAGEMENT OF TRACHEOBRONCHIAL INJURY: CASE PRESENTATION AND REVIEW OF THE LITERATURE

H. R. Davari\*, and S. A. Malekhossini

Department of Surgery, Nemazee Hospital, School of Medicine, Shiraz University of Medical Sciences, Shiraz, Iran

**Abstract-** Tracheobronchial injuries are uncommon and their successful diagnosis and treatment often requires high level of suspicious. Surgical repairs should be individualized for each type of injury. This article reviews diagnosis and management of traumatic injuries to the trachea and major bronchi. From March 26, 1991 to March 20, 2003, twenty-seven patients with major airway trauma were managed in Nemazee hospital, Shiraz, Iran. Afterwards these patients were prospectively studied, for a period of 10 years. The mechanism of injury was blunt trauma in 13 patients, stab wound in 6, gunshot in 2 patients, and iatrogenic in 6. Two patients had associated esophageal injury. Twenty-one patients were male and 6 were female. Eight patients had major bronchial injury, 13 had cervical tracheal injury and 6 had mediastinal tracheal injury. Six patients had re-implantation of main bronchus (5 right and 1 left), and two patients had repair of bronchus with concomitant bi-lobectomy in one of them. In cases of tracheal injury, 12 patients had primary repair of trachea with distal tracheostomy in two. However, 7 patients were managed conservatively with later sleeve resection of trachea and laryngotracheal anastomosis in three patients. There was no morbidity but three patients died. Tracheobronchial injury is extremely challenging due to its early threat to life. A high level of suspicious and the liberal use of bronchoscope are critical in the diagnosis of tracheobronchial injuries. Avoidance of iatrogenic complications, primary repair and liberal use of autogenous tissue for wrapping or buttressing increases successful rate.

*Acta Medica Iranica*, 43(4): 291-298; 2005

**Key words:** Trauma, tracheobronchial injury, reimplantation

## INTRODUCTION

Tracheobronchial injuries are rare, but potentially life threatening. It requires early diagnosis, skillful airway management, and prompt surgical repair. The trachea can be injured anywhere along its course, but the most common locations are the neck and near the carina. Injuries to the major bronchi are usually within 2.5 cm of carina and right-sided injuries are probably more common than left sided injuries. This article describes cases with major airway trauma who had survived the trauma until our operation room.

## MATERIALS AND METHODS

From March 26, 1991 to March 20, 2003, twenty-seven patients with trachea or major bronchial injury were managed in Nemazee hospital. In a prospective study, demographic characteristics, like age, sex distribution, etc. and clinical findings, cause and location of injuries, associated injuries, airway management, surgical treatment and the outcomes were studied.

## RESULTS

Twenty-seven patients were studied, 21 were male and 6 female. The age ranged from 1 to 60 years. Diagnosis was delayed between 3 days to 2.5 years in 6 patients with blunt injury.

Received: 30 Jun. 2003, Revised: 25 Sep. 2004, Accepted: 20 Dec. 2004

**\* Corresponding Author:**

H.R. Davari, Department of Surgery, Nemazee Hospital, School of Medicine, Shiraz University of Medical Sciences, Shiraz, Iran  
Tel: +98 711 6263054, +98 917 1131232,  
Fax: +98 711 6263054  
E-mail: davarih@sums.ac.ir

## Management of tracheobronchial injury

**Table 1.** Mechanisms of Injury

Mechanism of injury	No
Blunt Trauma	13
Penetrating	
Stab Wound	6
Gun Shot	2
Iatrogenic	
Re-intubation after tonsillectomy	1
Intubation & general anesthesia*	3
Therapeutic Bronchoscopy**	1
Surgery***	1
<b>Total</b>	<b>27</b>

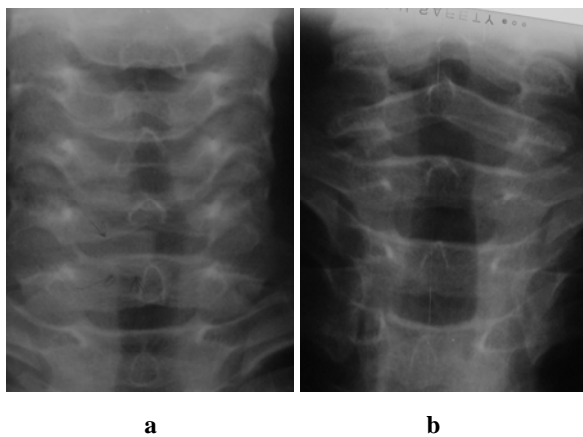
\* Rupture/perforation of the mediastinal trachea during general anesthesia

\*\*Bronchoscopy for removal of the foreign bodies

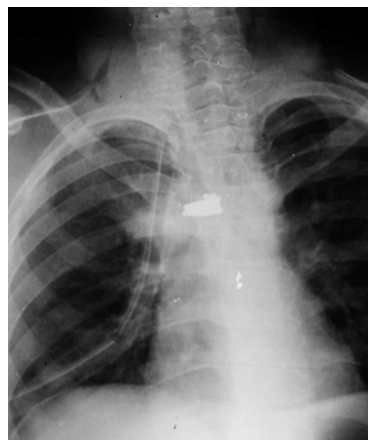
\*\*\* Tracheal laceration during transhiatal esophagectomy

The mechanism of injury was blunt trauma in 13 patients, stab wound in 6, gunshot in 2 and iatrogenic in 6 (Table1). We operated two interesting cases, a motorcycle driver and another one a boy sitting in front of his father. They had blunt injury to their neck, caused by careless driving without light at night and crashing with a metallic chain at the entrance of an alley. These patients were referred to us after 2 to 3 months with unrecognized diagnosis in the motorcycle driver man and conservative orotracheal intubation in the boy (Fig. 1).

Four patients had associated injuries, 2 cervical esophageal injuries, one concomitant thoracic duct and left intercostal artery injury. One patient had spleen, left kidney and diffuse compact head injury, and the other one had internal jugular vein tearing.



**Fig. 1. (1a)** Blunt Trauma (Hit by a chain), Laryngotracheal stricture **(1b)** Sleeve resection, 3 months after stent removal



**Fig.1.** Bullet injury. Perforation of the right main bronchus and mediastinal trachea. Median sternotomy plus anterolateral thoracotomy (repair plus thymic flap).

Figure1 shows the chest X-ray (CXR) of a patient with bullet injury to his chest with perforation of the trachea and right main bronchus. The locations of injuries to the tracheobronchial tree are shown in Table 2.

### Surgical interventions

The operation performed in each patient is shown in Table 3 and Figures 3 and 4. Five of the simple lacerations were repaired by surgery residents. Fifteen other patients had major operation in which 5 were done by pediatric surgeon and general surgeons and the rest (10 other patients) were performed by our thoracic surgeon (Fig. 1, 2, 3, 4). One lung ventilation was used in five patients (double lumen in 4 and bronchial intubation in one).

Various incisions including, 11 oblique and collar neck incision, 10 classic posterolateral thoracotomy, 1 median sternotomy plus right anterolateral, and 1 left trapdoor, were used. Sleeve resection of trachea and laryngotracheal anastomosis was acquired in 3 out of 7 of the patients who were managed conservatively.

**Table 2.** Location of the Injury

Location	No
Trachea	
Cervical	13
Mediastinal	6
Main Bronchus	
Right	7
Left	1
<b>Total</b>	<b>27</b>

**Table 3.** Type of surgical repairs

Type of Repair			No
Trachea	Cervical	Repair	9
		Conservative	1
		Sleeve Resection	3
	Mediastinal	Repair	3
		Conservative	3
Main Bronchus	Re-implantation	6	
	Repair +/- Resection	2	
Total			27

One patient had bi-lobectomy and repair of his right upper lobe performed by a pediatric surgeon, and in another one right main bronchus and carina repair were done and buttressed by thymic flap (Table3).

Primary cervical tracheal repair was done for 12 patients and distal tracheostomy in two. Five Patients were managed primarily with transient tracheostomy or orotracheal intubation. Later laryngotracheal resection and anastomosis were needed in 3 patients with placement of stent in one patient (Table3).

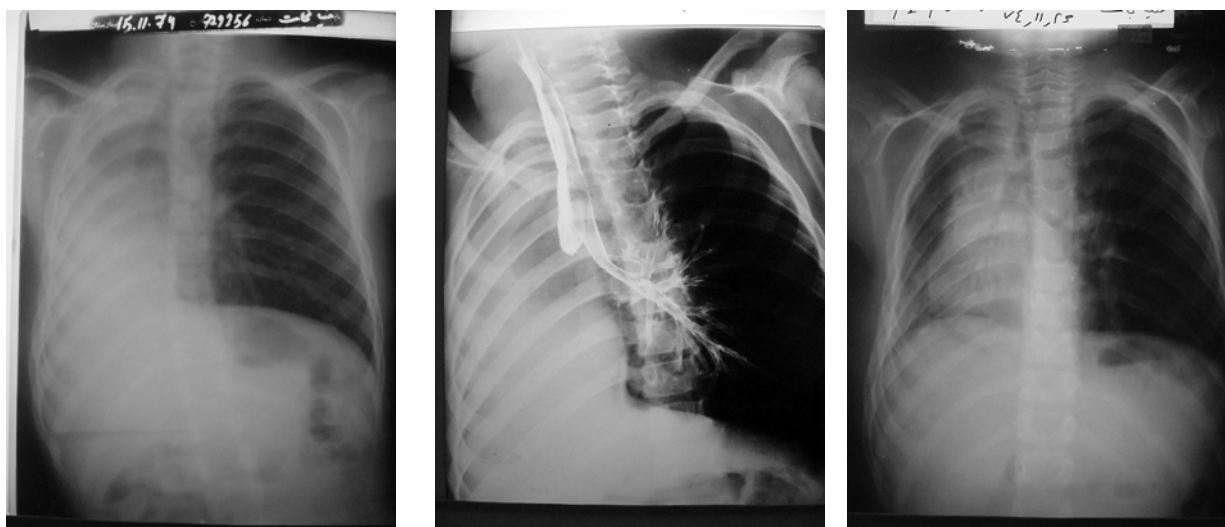
### Associated injury management

Two patients had associated esophageal injury. In the first patient who had sustained stab wound,

simple repair was done. In the second case, in which injury was caused by gun shot, cervical esophagostomy, gastrostomy, jejunostomy was performed, and tracheal wound was managed by tracheostomy and with staged colon interposition. Unfortunately, after removal of the tracheostomy tube, the patient developed tracheal stricture. Therefore sleeve resection was performed in his 3<sup>rd</sup> operation and the procedure was successful. We used 6<sup>th</sup> intercostal muscles and one thymus flap for supporting repair of distal trachea or the main bronchus.

### Mortality

Three patients died .One with bi-lobectomy and repair of right upper lobe died from respiratory failure, one week post-operation. The second patient died at the end of the operation because of diffuse compact head injury, concomitant with visceral injury. The third patient was in a one year old boy who was a case of iatrogenic tracheobronchial injury, caused by an otolaryngologist during removal of foreign bodies. He was afterwards managed by a pediatric surgeon with tube thoracostomy and mechanical ventilation. He had sudden respiratory arrest most probably due to a mucus plug.



**Fig. 3. (3a, 3b)** Complete transection of the right main bronchus, 2.5 years after trauma **(3c)** Reimplantation of the bronchus.

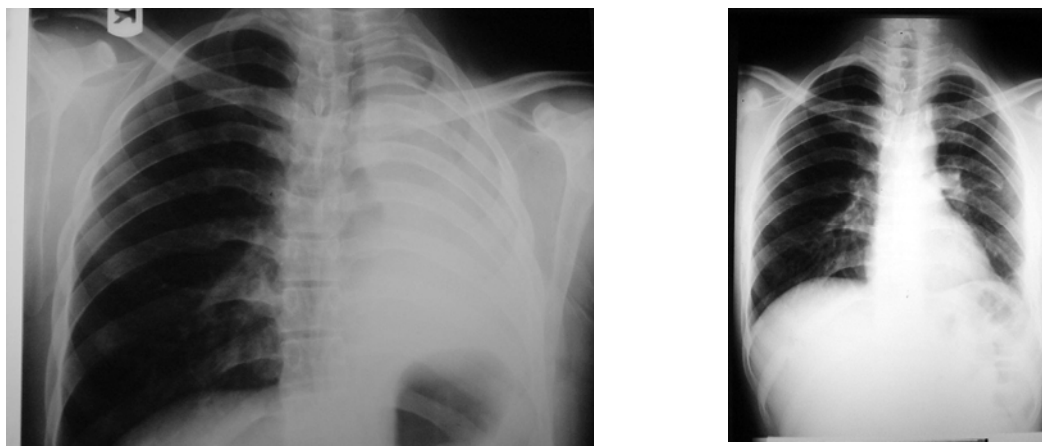


Fig. 4. (4a) Complete transection of the left main bronchus, diagnosis 45 day after trauma. (4b) Re-implantation

## DISCUSSION

### Etiology

Tracheobronchial injury was considered rare until the last three decades. These lesions are now becoming far more common or are being more often recognized, most probably because of the increasing incidence of motor vehicle accidents and rapid transportation system, which allows more patients to reach the hospital alive. However, these injuries are still uncommon. The etiology of tracheobronchial injury is as the instruments and circumstances by which it occurs. Blunt and penetrating injuries account for the vast majority; however, iatrogenic injuries such as mediastinoscopy, transtracheal oxygen therapy, and mechanical ventilation have been reported (1). Other uncommon causes are razor slash, strangulation, electrical injuries, burns, and caustic injuries. Penetrating injuries occur most commonly in the cervical trachea (75%) followed by the thoracic trachea (25%) (1). Stab wounds or gunshot wounds may injure major bronchi and are almost always associated with other injuries, especially injuries to the great vessels (2) Tracheobronchial injury appears to occur approximately in 1% to 2% of the individuals sustaining blunt injury and 2% to 9% of those sustaining penetrating injury to the thorax (1). Kirsh and Orringer proposed the mechanism for blunt thoracic injuries that cause disruption of the main bronchus and intrathoracic trachea (3) The proximity of trachea and bronchi to arteries, veins, esophagus,

and spinal column make injury to these organ systems, inevitable. Early reports showed a paucity of associated injuries, probably due to early death. By 1976, Kirsh and Orringer reported that at least 50% of patients had associated injuries (3). Recent reports showed that 75% to 100% of patients suffering blunt tracheobronchial trauma have associated injuries (4-6). Injury to the esophagus is perhaps the most frequent associated injury from both penetrating and blunt causes. Feliciano and coworker (s) reported 23 cases of combined tracheal and esophageal injury from penetrating causes (20 gun shot wounds, 3 stab wounds) (7). Of equal importance was the observation of concomitant spinal column injury, 26% (6 of 23) (7).

In our cases, we had only two esophageal injuries .Paucity to other associated injury in our study may be due to dying of patients with severe injuries prior to their arrival in the hospital. Major urban trauma centers with 2500 to 3000 admissions per year can therefore expect to see 2 to 4 cases of cervicothoracic tracheal injury per year.

The true incidence of these injuries in our country has not yet been reported, however we estimate that it should be more common than that found in western countries. Our center, as a referral center for south of Iran, has more than four to five thousands trauma admission per year and 27 cases of tracheobronchial trauma within 10 years. We expected to see more upper airway trauma in near the future because of increased number of motor vehicles and below standard roads and driving skills.

## **Sign and Symptom**

Cough, stridor, dyspnea, hemoptysis, and change in voice are all associated with tracheal injury. When there is an open wound, exit of bloody air bubbles through it may be dramatic. When the skin is intact, most of these symptoms are also seen, but instead of the exit of bloody air, emphysema of the neck and mediastinum or pneumothorax is observed.

Accurate diagnosis of tracheobronchial injury necessitates an understanding of the mechanism of injury and mandates simultaneous evaluation of associated injuries. Blunt injuries, which seem to result from deceleration, are usually not associated with other major chest injuries and the diagnosis is frequently delayed. Whereas penetrating wounds are relatively easy to diagnose, blunt injuries are frequently unrecognized during the early period after injury. In our cases, there was delay in diagnosis between 3 days to 2.5 years.

## **Initial evaluation and management**

Initial evaluation and management of patients with suspected cervicothoracic airway injury must occur simultaneously and proceed expeditiously from the moment of injury identification in the field to restoration of airway continuity through reconstruction in the surgical theater. Management of the airway should be entrusted to the most experienced member of the anesthesiology, trauma, or thoracic team, not the newest fledging in the emergency room. There are those who recommend immediate mandatory cervical exploration for penetrating injuries (8,9). Others recommend judicious endoscopy to avoid unnecessary exploration (10). Carduci performed a superb study on delineating the consensus and controversies of penetrating neck trauma (11). Golueke and coworker (s) prospectively randomized 160 patients' neck wounds to mandatory exploration or selective operation. There were no differences in length of stay, morbidity, or mortality (12). Thompson and coworker (s) described urgent thoracotomy for diagnosis and management of pulmonary or tracheobronchial injury (13). We have more often explored the neck when penetrating injuries occur, and selectively operated when blunt cervical injuries or thoracic tracheobronchial injuries were suspected

based on an index of suspicion and bronchoscopy. When cervical tracheal injury is suspected, rapid confirmation should be attempted. In penetrating wounds, immediate surgical exploration is indicated because of possible associated injury, or asphyxia secondary to aspirated blood (14). With a large neck wound, a tube can frequently be passed into the tracheal wound and an airway thus established. Suction of blood and secretions is necessary prior to forced ventilation. Without a large anterior neck wound, orotracheal intubation with a small tube should be carefully attempted. The administration of muscle relaxants or general anesthesia prior to obtaining an airway is very dangerous. Orotracheal intubation should be attempted in all cases except for those with massive maxillofacial trauma. The endotracheal tube, unless carefully controlled, can pass through the tracheal wound into the soft tissues, resulting in complete airway obstruction. Orotracheal intubation can be accomplished in the vast majority of cases. Even when there is total disruption of the trachea and retraction of the distal end into the superior mediastinum, orotracheal intubation is successfully accomplished using the flexible bronchoscope as described by Graver and coworker (s) (15). An airway must be attained initially while in-line stabilization of the spine is performed; compression of injured vascular structure in the neck should occur simultaneously. If the injury is intrathoracic, tube thoracotomy for evacuations of a hemothorax or elimination of a pneumothorax should be performed. After recognizing the airway injury and securing the airway, hemodynamic instability should be corrected and management of associated injuries should occur. Once the airway is secure, general anesthesia and attention to vascular trauma is practical. With the caveats in mind, flexible bronchoscopy, if not previously performed, should be done in the surgical suite to define the injuries.

## **Tracheal injury**

Management of cervicothoracic tracheal trauma evolved slowly until Grillo and Mathisen defined the technique of tracheal surgery. Symbas has described innovative management techniques for both penetrating and non-penetrating tracheal trauma (16,17,19). Penetrating wounds fall into three groups:

## Management of tracheobronchial injury

1. Small anterior wounds, 2. posterior injuries, and 3. extensive tracheal destruction. Anterior wounds, smaller than one half the circumference of the trachea or involving two rings of it, may be treated simply by passing a tube through the defect as a tracheostomy (4). Extension of the wound may be necessary for this to be accomplished. Such a tube can usually be removed in 4 to 6 days. Larger anterior injuries and most posterior perforations should be definitively repaired. Lacerations should be repaired with absorbable sutures with knots tied on the outside. Extensive injuries may be managed by resection of two to four rings and re-anastomosing. On rare occasions, silicone tubes can be used for management of tracheal injuries at a distant time from the injury, or when there is concurrent laryngeal injury. Once the primary repair is accomplished, autogenous tissue should be used to wrap the repair. Perforation may be patched with autogenous tissue. This provides buttressing of the repair and separation of the suture line from nearby vascular structure and the esophagus. Virtually all of the strap muscles can be utilized to wrap the cervical trachea and separate it from the esophagus (1). In the thorax, intercostal muscles, serratus anterior, or latissimus muscle can be used. Antibiotics (three doses, or occasionally longer if gross contamination has occurred) is started for the patients, before operation. Extubation occurs in the operating room or as soon as respiratory physiology allows. Lee did not immobilize the neck by suturing the chin to the chest when a resection and primary repair was performed in the trauma population (1). A variety of incisions can be utilized for exposing the trachea. In our cases, various incisions including collar and oblique neck incisions, classic thoracotomy, median sternotomy, and trap door incision were used. Generous collar incision with extension to a median sternotomy, was performed allowing visualization of the entire trachea. These also allow a simultaneous laparotomy for control of hemorrhage, if necessary. The superior vena cava and aortic arch can be mobilized and the posterior pericardium entered in order to provide access to the carina, as illustrated by Symbas (16). The goal is to avoid further iatrogenic trauma to the trachea; thus, avoidance of cricothyroidotomy and tracheostomy is desirable. Tracheostomy tube placed

through a penetrating tracheal wound has been used for establishment of the airway. This is acceptable and generally expeditious. Others have recommended placement of a distal tracheostomy to protect a more proximal repair. As anesthetic techniques have evolved, this is no longer necessary. Grady Memorial Hospital in Atlanta (17) and Charity Hospital in New Orleans (2) no longer perform tracheostomy for protection of a tracheal repair. We can extubate the patient after repairing the trachea unless there is massive maxillofacial trauma or severe pulmonary parenchymal damage (i.e., pulmonary contusion).

## Bronchial injury

Diagnosis of bronchial injury is best established by bronchoscopy. Because of the nature of multiple injuries, a flexible bronchoscope through an endotracheal tube is usually used. However, the diagnosis may well be missed by a flexible bronchoscope (19), so that in those cases in which there is high degree of suspicion and flexible bronchoscopic examination has been negative by two observers on two occasions, Pate recommends rigid bronchoscopy (4). If the above studies were negative and strong suspicion exists, a bronchogram may be done (4). Because water-soluble contrast medium seems more irritating to the lung, Dionosil is preferred. It is important to remember that when bronchial injury is suspected, use of the ventilator, especially with positive end expiratory pressure or continuous positive airway pressure may be fatal. One must be sure that well functioning thoracostomy tubes are in place before the patient is placed on the ventilator. Because more than three fourth of the injuries occur in the major bronchi close to carina, anesthesia may be a serious problem during surgical repair. It may be successful to use a double lumen tube or even intubating a single bronchus prior to thoracotomy. We used one-lung ventilation in 5 cases. When this cannot be accomplished safely, several sizes of sterile endotracheal tubes should be available at the operative field, and as soon as the chest is entered, controlled of the bronchi is obtained by the cooperation of the anesthesiologist and the surgeon. Exposure of the mediastinal trachea, the carina, and the right main bronchus is best achieved through a right posterolateral thoracotomy through

the fourth intercostal space. The proximal left main bronchus can be dealt with through a right thoracotomy; however, complete transection of the left main bronchus is best exposed through a standard left thoracotomy (20). Management consists of maintaining adequate, but not excessive, ventilation, antibiotics, and repair of the bronchus or pulmonary resection. Pneumonectomy is not recommended in trauma patient because of 100% mortality rate; therefore repair is the preferred method (20). It is recommended to repair bronchial injury and it can be repaired proximal to sub-segmental bronchi. Laceration in distal bronchi can be resected.

### Complications

The majority of complications are due to delay in diagnosis, iatrogenic injuries, and failure to recognize associated injuries. Bronchial injury is missed more frequently and may lead to pulmonary infection, incomplete re-expansion of the lung, or tracheobronchial strictures (21-23). Delay in diagnosis may necessitate pulmonary resection for stenosis at a later time (24). Long delays can, however, occasionally be repaired with a successful outcome (25). Bertelesen and coworker (s) revealed that more than 75% of the patients sustaining this injury from non-penetrating causes die at the scene or are dead on arrival at the emergency department<sup>26</sup>. More recent series of combined penetrating and non-penetrating injuries reveal that even after reaching the hospital and undergoing surgical correction, death occurs in 14% to 25% of the patients (5,6,16,17). Death is generally due to associated injuries and not to the tracheobronchial injury.

### Acknowledgment

The authors would like to thank the Office of Research Development of Nemazee Hospital and Dr. Hooman Yarmohammadi for editorial assistance.

## REFERENCES

1. Lee RB. Traumatic injury of the cervicothoracic trachea and major bronchi. *Chest Surg Clin N Am.* 1997 May; 7(2):285-304.
2. Kelly JP, Webb WR, Moulder PV, Everson C, Burch BH, Lindsey ES. Management of airway trauma. I: Tracheobronchial injuries. *Ann Thorac Surg.* 1985 Dec; 40(6):551-555.
3. Kirsh MM, Orringer MB, Behrendt DM, Sloan H. Management of tracheobronchial disruption secondary to nonpenetrating trauma. *Ann Thorac Surg.* 1976 Jul; 22(1):93-101.
4. Pate JW. Tracheobronchial and esophageal injuries. *Surg Clin North Am.* 1989 Feb; 69(1):111-123.
5. Flynn AE, Thomas AN, Schecter WP. Acute tracheobronchial injury. *J Trauma.* 1989 Oct; 29(10):1326-1330.
6. Ramzy AI, Rodriguez A, Turney SZ. Management of major tracheobronchial ruptures in patients with multiple system trauma. *J Trauma.* 1988 Sep; 28(9):1353-1357.
7. Feliciano DV, Bitondo CG, Mattox KL, Romo T, Burch JM, Beall AC Jr, Jordan GL Jr. Combined tracheoesophageal injuries. *Am J Surg.* 1985 Dec; 150(6):710-715.
8. Palmer MT, Turney SZ. Tracheal rupture and atlanto-occipital dislocation: case report. *J Trauma.* 1994 Aug; 37(2):314-317.
9. Roon AJ, Christensen N. Evaluation and treatment of penetrating cervical injuries. *J Trauma.* 1979 Jun; 19(6):391-397.
10. Chavez CM, Anas P, Conn JH. Surgical approach to injuries of the cervical trachea. *South Med J.* 1972 Jun; 65(6):659-660.
11. Branco JMC. Thoracoscopy as a method of exploration in penetrating injuries of the thorax. 1986; 15:208-15.
12. Golueke PJ, Goldstein AS, Sclafani SJ, Mitchell WG, Shaftan GW. Routine versus selective exploration of penetrating neck injuries: a randomized prospective study. *J Trauma.* 1984 Dec; 24(12):1010-1014.
13. Thompson DA, Rowlands BJ, Walker WE, Kuykendall RC, Miller PW, Fischer RP. Urgent thoracotomy for pulmonary or tracheobronchial injury. *J Trauma.* 1988 Mar; 28(3):276-280.
14. Pate JW, Casini M. Penetrating wounds of the neck: explore or not? *Am Surg.* 1980 Jan; 46(1):38-43.
15. Grover FL, Ellestad C, Arom KV, Root HD, Cruz AB, Trinkle JK. Diagnosis and management of major tracheobronchial injuries. *Ann Thorac Surg.* 1979 Oct; 28(4):384-391.

## Management of tracheobronchial injury

16. Symbas PN, Justicz AG, Ricketts RR. Rupture of the airways from blunt trauma: treatment of complex injuries. *Ann Thorac Surg.* 1992 Jul; 54(1):177-183.
17. Symbas PN, Hatcher CR Jr, Boehm GA. Acute penetrating tracheal trauma. *Ann Thorac Surg.* 1976 Nov; 22(5):473-477.
18. Symbas PN, Hatcher CR Jr, Vlasis SE. Bullet wounds of the trachea. *J Thorac Cardiovasc Surg.* 1982 Feb; 83(2):235-238.
19. Reddin A, Mirvis SE, Diaconis JN. Rupture of the cervical esophagus and trachea associated with cervical spine fracture. *J Trauma.* 1987 May; 27(5):564-566.
20. Battistella FD, Benfield JR. Blunt and penetrating injuries of the chest wall, pleura. And lungs. In Shields TW, Locicero III J, Ponn RB, eds. *General thoracic surgery.* 5<sup>th</sup> ed. Philadelphia: Williams & Wilkins 2000:815-31.
21. Courad L, Velly Jf, Martigne C, and coworker (s). posttraumatic disruption of the laryngo-tracheal junction. *Eur J Cardiothorac Surg.* 1989; 3:441-4.
22. Mansour KA, Lee RB, Miller JI Jr. Tracheal resections: lessons learned. *Ann Thorac Surg.* 1994 May; 57(5):1120-1124.
23. Wagner RB, Slivko B. Highlights of the history of nonpenetrating chest trauma. *Surg Clin North Am.* 1989 Feb; 69(1):1-14.
24. Taskinen SO, Salo JA, Halttunen PE, Sovijarvi AR. Tracheobronchial rupture due to blunt chest trauma: a follow-up study. *Ann Thorac Surg.* 1989 Dec; 48(6):846-9.
25. Shabb BR, Taha AM, Nabbout G, Haddad R. Successful delayed repair of a complete transection of the right mainstem bronchus in a five-year-old girl: case report. *J Trauma.* 1995 Jun; 38(6):964-966.
26. Bertelsen S, Howitz P. Injuries of the trachea and bronchi. *Thorax.* 1972 Mar; 27(2):188-194.