

# EVALUATION OF THE INCIDENCE AND OUTCOME OF FETAL HYDRONEPHROSIS PRENATALLY DIAGNOSED BY ULTRASOUND

M. Pourissa<sup>\*1</sup>, S. Refahi<sup>1</sup> and H. Nazari<sup>2</sup>

1) Department of Radiology, School of Medicine, Tabriz University of Medical Sciences, Tabriz, Iran

2) Department of Radiology, School of Medicine, Ardebil University of Medical Sciences, Ardebil, Iran

---

**Abstract-** The outcome and proper management of fetal hydronephrosis have not been completely defined. The purpose of this study was to determine incidence and outcome of infants with a history of prenatal hydronephrosis diagnosed by ultrasound. In a three-year period from 2000 to 2003 we identified 211 cases (271 renal units) of fetal hydronephrosis in which renal pelvic anteroposterior diameter was more than normal diameter at various stages of pregnancy. Incidence of fetal hydronephrosis was 3.8 percent in the 55500 fetuses screened by ultrasound. A total of 187 fetuses (240 renal units) followed up underwent postnatal sonography and only in ten cases renal pelvic anteroposterior diameter was greater than 15 mm that required surgical correction. The most important advantage of knowing that a fetus has ultrasound findings of persistent hydronephrosis is ability to begin timely evaluation of the newborn to identify severity of hydronephrosis and prevent progressive deterioration of renal function.

*Acta Medica Iranica*, 43(5): 336-338; 2005

**Key words:** Hydronephrosis, prenatal ultrasound, outcome

---

## INTRODUCTION

Fetal hydronephrosis is the most common fetal anomaly detected on prenatal ultrasound. With the growing use of ultrasound in obstetrics, the number of otherwise healthy fetuses who are diagnosed with fetal hydronephrosis is increasing. As a result, more infants with history of fetal hydronephrosis are presenting to pediatricians, nephrologists and urologists but outcome and proper management of this condition have not been completely defined. Reports describing the postnatal outcome of this finding have several important limitations, including

the failure to define hydronephrosis specifically or consistently and inclusion in the outcome review of only surgically related diagnoses, such as ureteropelvic junction obstruction (1).

The incidence of hydronephrosis detected prenatally is 1-1.4%. The normal renal pelvic anteroposterior diameter (RPAD) increases gradually during gestation, from 5 mm at 24 week to 10 mm by 32 week (2). It has been stated that postnatal ultrasonography should not be performed in the early neonatal period. It has been recommended that, when ultrasound is negative within 48 hours of birth, the study should be repeated at approximately 1 week of life. These recommendations address the concern that significant hydronephrosis may be missed due to neonatal oliguria, resulting in delayed therapy and irreversible renal damage. When these recommendations were made, early surgical repair was done on many kidneys found to be persistently

Received: 31 Oct. 2004, Revised: 8 Jan. 2005, Accepted: 14 Feb. 2005

**\* Corresponding Author:**

M. Pooreisa, Department of Radiology, School of Medicine, Tabriz University of Medical Sciences, Tabriz, Iran  
Tel: +98 411 3324626, +98 9141142628  
Fax: +98 411 3345591  
E-mail: masoudpe@yahoo.com

hydronephrotic even when hydronephrosis was not severe (3). The purpose of this study was to determine incidence and outcome of infants with a history of prenatal hydronephrosis.

## MATERIALS AND METHODS

From 2000 to 2003, we evaluated 55500 women at various stages of pregnancy referred to our medical center for prenatal ultrasound due to a range of primary indications. Regardless of the indication for ultrasound, the fetal kidneys were visualized in each case after obtaining informed consent. When hydronephrosis was suspected, a detailed anatomical evaluation of the fetus was performed and the grade of hydronephrosis was determined. The diagnosis of hydronephrosis was made when fetal RPAD was greater than normal diameter at any stage of gestation. Possible postnatal outcomes were discussed with the family by a pediatric nephrologist. All neonates with prenatal hydronephrosis underwent abdominal ultrasound after birth. Prenatal hydronephrosis was categorized as mild, moderate, severe and highly severe when RPAD was < 5 mm, between 5 mm and 10 mm, between 10 mm and 15 mm and greater than 15 mm, respectively.

The follow up examination was performed after birth, and findings were compared to results of prenatal ultrasound.

## RESULTS

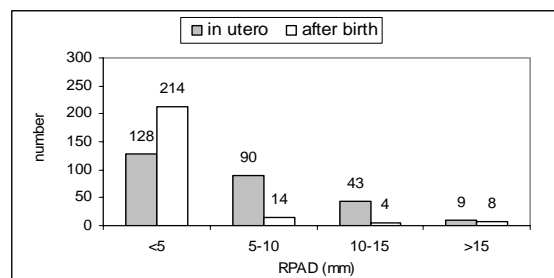
We evaluated 55500 cases by prenatal ultrasound and 211 (271 renal units) were found to have fetal hydronephrosis according to the previously described criteria. Fetal hydronephrosis was bilateral in 60 cases (28%) and unilateral in 151 (72%). Right renal hydronephrosis was found in 94 cases (62%) and left in 57 (38%). In our study 77% of the fetuses were male and 23% were female (3:1 ratio). Prenatal hydronephrosis was considered mild in 128 renal units (47.3%), moderate in 90 (33.3%), severe in 43 (15.9%) and highly severe in 9 (3.6%).

Three fetuses had associated anomalies, and other pregnancies and births were uncomplicated. Three fetuses died after birth because of associated renal

dysplasia, secondary oligohydramnios and pulmonary hypoplasia. Twenty one cases were not returned to medical center for further postnatal evaluation and were excluded from study. Among 187 infants (240 renal units) who were followed up, 214 renal units (89%) became mild, 14 (6%) moderate, 4 (1.5%) severe and 8(3.5%) highly severe (Fig. 1). In our study incidence of fetal hydronephrosis was 3.8% in the 55500 fetuses screened by ultrasound. Among 240 renal units, only 10 instances in which RPAD was greater than 10 mm required surgical correction.

## DISCUSSION

There is no doubt that ultrasound plays a pivotal role in helping us to understand urinary tract abnormalities. Fetal urinary tract abnormalities are reported in up to 1 per 100 pregnancies, making it one of the most commonly diagnosed prenatal malformations. Disagreement continues over treatment of patients during pregnancy when fetal hydronephrosis is diagnosed (4). Therefore, evaluation and treatment of neonatal hydronephrosis remain controversial (2). Prenatal ultrasonographic detection of fetal genitourinary abnormalities was first reported in 1970 by Garrett *et al.* In the series of Coplen *et al.* hydronephrosis comprised 50% of detected prenatal abnormalities (5). Previous studies correlated prenatal hydronephrosis with ureteropelvic junction obstruction and vesicoureteral reflux but few compared specific measurements of prenatal hydronephrosis with postnatal outcome (1). Comparison of incidence of hydronephrosis between our study and that of others showed that hydronephrosis in our study had a higher incidence (2, 6).



**Fig. 1.** Number of hydronephrotic kidneys. RPAD, renal pelvic anteroposterior diameter.

## **Incidence and outcome of fetal hydronephrosis**

The severity of hydronephrosis was based on the anteroposterior renal pelvic diameter and on gestational age (4). Fetal outcome clearly depends on severity and whether there is unilateral or bilateral hydronephrosis (5). Grades of hydronephrosis change between the prenatal and postnatal sonograms. To our knowledge, this is the first study to examine potential differences in the degree of hydronephrosis on serial sonograms performed during pregnancy and after birth in newborns with a history of prenatal hydronephrosis (7). There is no contraindication to early neonatal renal ultrasonography (3). Fetuses with high grade hydronephrosis should undergo miscellaneous examinations and monitoring until hydronephrosis resolved. Early identification of these patients is important to ensure adequate follow up care (1). Ultrasonic follow up indicated that hydronephrosis:

1) Resolved generally almost in all renal units which were in the mild and moderate hydronephrosis groups.

2) Recovered or improved in a small number of renal units with severe hydronephrosis.

3) Remained unchanged or became worse almost in the all of renal units with highly sever hydronephrosis.

These data suggest that when the RPAD is less than 5 mm, hydronephrosis can be considered to be physiologic; if the RPAD is 5-10 mm, screening with long intervals till recovery is necessary; and cases with anteroposterior diameter in the range of 10-15

mm should be followed up in short intervals. When renal pelvic dilatation is more than 15 mm surgical correction should be down immediately.

## **REFERENCES**

1. Stocks A, Richards D, Frentzen B, Richard G. Correlation of prenatal renal pelvic anteroposterior diameter with outcome in infancy. *J Urol.* 1996 Mar; 155(3):1050-1052.
2. Aslan AR, Kogan BA, Mandell JB. Neonatal hydronephrosis. *Curr Opin Urol.* 1998 Nov; 8(6): 495-500.
3. Docimo SG, Silver RI. Renal ultrasonography in newborns with prenatally detected hydronephrosis: why wait? *J Urol.* 1997 Apr; 157(4):1387-1389.
4. Feldman DM, DeCambre M, Kong E, Borgida A, Jamil M, McKenna P, Egan JF. Evaluation and follow-up of fetal hydronephrosis. *J Ultrasound Med.* 2001 Oct; 20(10):1065-1069.
5. Coplen DE. Prenatal intervention for hydronephrosis. *J Urol.* 1997 Jun; 157(6):2270-2277.
6. Morin L, Cendron M, Crombleholme TM, Garmel SH, Klauber GT, D'Alton ME. Minimal hydronephrosis in the fetus: clinical significance and implications for management. *J Urol.* 1996 Jun; 155(6):2047-2049.
7. Wiener JS, O'Hara SM. Optimal timing of initial postnatal ultrasonography in newborns with prenatal hydronephrosis. *J Urol.* 2002 Oct; 168(4 Pt 2):1826-1829.