

MULTICENTRIC RETICULOHISTIOCYTOSIS: A CASE REPORT

Z. Rezaieyazdi^{*1}, M. Sandooghi¹, H. Mansouri Torghabe² and A. Derhami³

1) Department of Rheumatology, Ghaem Hospital, School of Medicine, Mashhad University of Medical Sciences, Mashhad, Iran

2) Department of Hematology, School of Medicine, Tarbiat Modarres University of Medical Sciences, Tehran, Iran

3) Department of Pathology, School of Medicine, Mashhad University of Medical Sciences, Mashhad, Iran

Abstract- Multicentric reticulohistiocytosis (MRH) is a rare proliferative histiocytic disease of unknown cause with potentially disabling nature. Primary manifestations are involvement of skin and joints. The articular destruction can lead to permanent joint deformities. Our patient was a 47 year-old woman with bilateral symmetrical polyarthritis and reddish- brown papulonodular cutaneous lesions. The diagnosis of multicentric reticulohistiocytosis was confirmed by histological examination. Both skin and articular manifestations were only partially treated with oral corticosteroids, monthly bolus cyclophosphamide, weekly methotrexate and knee synoviorthesis with nitrogen mustard.

Acta Medica Iranica, 43(5): 372-376; 2005

Key words: Reticulohistiocytosis, multicentric, treatment, proliferative histiocytic disease

INTRODUCTION

Multicentric reticulohistiocytosis (MRH) is a rare disease with unknown etiology. It usually occurs in whites and is more common in 40-60 years old women (2).

MRH primarily affects skin, mucous membranes and joints. It may be associated with constitutional symptoms such as fever, weight loss and fatigue. Hallmarks of the disease are nodular eruptions affecting various parts of the body with a predilection for hands and destructive deforming symmetrical polyarthritis. Erosive arthritis begins at the margins of the joints, progressing to osseous defects and to severe joint destruction. The disease is characterized by reactive tissue infiltration of lipid-laden histiocytes and multinucleated giant cells (3).

There is no standard treatment protocol for this rare but potentially disabling disease. Alkylating agents, especially cyclophosphamide or methotrexate have been shown to be very useful in treating this disorder.

CASE REPORT

A previously healthy 47-year-old woman presented in September 2002 with pain and swelling in both knees. She was treated with analgesic and physiotherapy with the impression of osteoarthritis, but there was no improvement. Five months later, she developed gradual weight loss, myalgia, pain and swelling in hands, wrists and shoulders.

She had 30-minute morning stiffness. After the onset of skin lesions, the patient was referred to a rheumatologist. Papular lesions were first seen on index fingers and gradually progressed to proximal of upper extremity, scalp, around ears, lips and nose. Her family history was negative for autoimmune disorders.

Received: 16 Mar. 2004, Revised: 20 Oct. 2004, Accepted: 5 Feb. 2005

*** Corresponding Author:**

Z. Rezaieyazdi, Department of Rheumatology, School of Medicine, Mashhad University of Medical Sciences, Mashhad, Iran
Tel: +98 511 8444876
Fax: +98 511 8444876
E-mail: rezaieyazdi-z@mums.ac.ir

Physical examination revealed swelling, tenderness and limited range of motion in wrists, metacarpophalangeal, proximal and distal interphalangeal joints, knees and elbows. Both shoulders were tender and had limited range of motion. Tenosynovitis was seen in ankles and she had a painful neck. Discrete and groups of reddish-brown, nonscaly, nontender, firm papules and nodules ranging from 2-6 mm in diameter were seen on the auricles, inner canthus, nose, scalp, anterior chest (V shape) and particularly on fingers (Fig. 1).

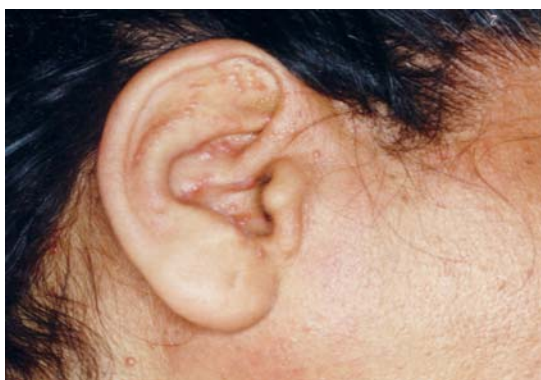The nail folds showed small papules, arranged around the nail resembling coral beads. Nasal mucosa was also involved. The remainder of history and examinations were largely unremarkable. The results of the following investigations were either negative or normal: Complete blood cell count, echocardiography, urine and stool examinations, serum biochemical tests, liver, renal and thyroid function tests, C reactive protein, antinuclear antibody, rheumatoid factor and VDRL. PPD skin test was negative. The erythrocyte sedimentation rate was 13 mm/h. Total cholesterol, LDL, HDL and triglycerides were 205, 130, 40 and 149 mg/dl, respectively. Ultrasonography of abdomen and pelvis and mammography were normal.

Roentgenograms of affected joints revealed mild osteopenia, marginal erosions in proximal and distal interphalangeal joints without narrowing of joint spaces. Chest X-ray was normal. Bone marrow aspiration and biopsy were normal. Result of Pap smear was reported as Class I. Twenty mm bloody joint fluids was aspirated from knee joint with white cell count of 10800/mm, 92% lymphocyte, 4%

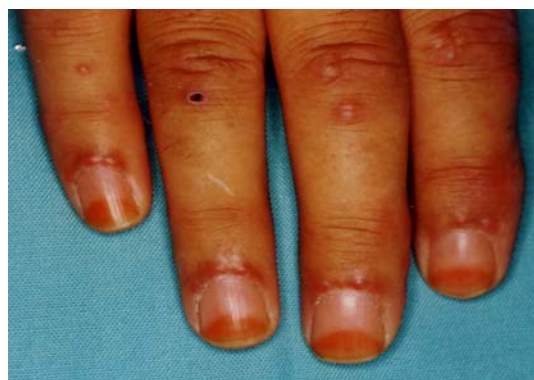polymorphonuclear and 4% monocyte. Knee synovial biopsy was done and demonstrated hyperplasia of synovial membrane with subsynovial edema and mononuclear infiltration with predilection of histiocytes without giant cells. Cytology was negative for malignant cells.

Histopathologic examination of a biopsy specimen obtained from a cutaneous nodule showed that all parts of dermis were occupied by mononuclear or multinucleated histiocytes with eosinophilic cytoplasm, also stained by periodic acid Schiff (Fig. 2). Immunohistochemical stain for 8-100 was negative. The microscopic findings of these multinucleated histiocytes were consistent with our clinical diagnosis of MRH. There was no evidence of visceral involvement, and no malignancy could be detected. The patient was treated with prednisolone 0.5 mg/kg/day; monthly bolus dose of cyclophosphamide infusion (1000 mg) and methotrexate 10 mg/week was also begun. After 4 weeks of treatment, there was striking alleviation of symptoms in all joints except knees. Triamcinolone acetonide was injected intra-articularly in both knees ultrasonographically.

After 6 months there was a 60% regression of skin lesions and complete improvement of auricular, scalp and neck lesions. Prednisolone was gradually reduced to 15mg/day. Joint symptoms regressed except for the right knee, for which chemical synovectomy with injection of nitrogen mustard was done. There was waxing and waning of skin lesions during follow up. Unfortunately, in spite of therapy complete improvement was not achieved and radiographic lesions with erosions were progressive (Fig. 3).



A



B

Fig. 1. (A) Coral beads papules around the nail and scattered lesions on fingers (location of biopsy is on ring finger) (B) Small papules on ear.

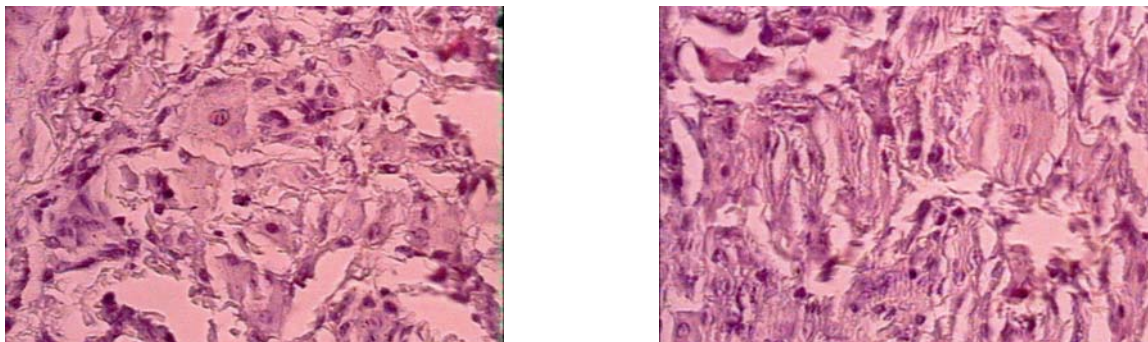


Fig. 2. Photomicrograph of a biopsy specimen from the finger, demonstrating a diffuse dermal histiocytic infiltration (hematoxylin and eosin, magnification $\times 100$).

DISCUSSION

MRH has a worldwide distribution, with a female predominance (60-75%) (2). Caro and Seneor first described this disorder in 1952 as reticulohistiocytosis granuloma (4). Goltz and Layman originally coined the term MRH in 1954 because of multifocal origin and systemic nature of the process. It usually begins during the fourth decade of life with polyarthritis (50% of cases), cutaneous lesions (25%) or concurrent arthritis and skin manifestations (25%).

The polyarthritis is usually diffuse, symmetric, progressive and destructive with predilection for distal interphalangeal joints (2). The disease is rare and fewer than 200 cases have been reported in medical literature (5). To the best of our knowledge this is the second case report of MRH from Iran (6).

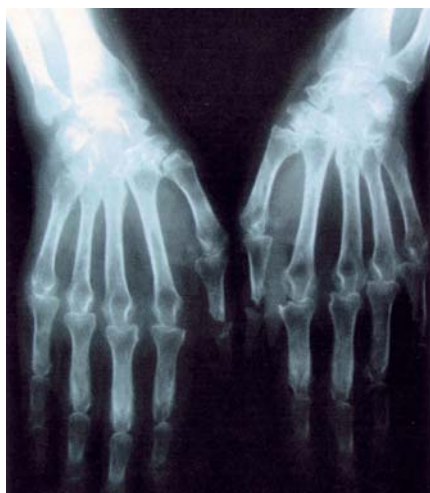

Fig. 3. Bilaterally symmetrical erosions of the wrist and hand joints.

There are a variety of associated diseases reported with MRH including malignancy in up to 25% of cases, diabetes, hypothyroidism, Sjögren's syndrome, primary biliary cirrhosis and also pregnancy (7-9). No underlying disease was detected in our patient.

Primary manifestations of MRH are joint and skin disease. Skin lesions are usually asymptomatic, discrete, firm, skin-colored to reddish-brown nontender nodules, varying in size from several millimeters to several centimeters, occurring most frequently over the face, scalp, dorsum of the hands, ears, neck, forearms and elbow. Small tumefactions around the nail folds, termed coral beads, are characteristic. The skin lesions tend to wax and wane independent of the arthritis (10). Our patient was a middle aged female who presented with arthritis of knees; wrists, proximal interphalangeal joints and shoulders had been subsequently involved. In contrast to other cases, involvement of distal interphalangeal joints was not prominent. She had typical coral beads skin lesions.

Arthritis became severe independent of skin lesions. Apart from the skin and joints, MRH may uncommonly also involve the mucosa, muscles, bones, tendon sheaths, lymph nodes, bone marrow, eyes, salivary glands, larynx, thyroid gland and internal organs. In our patients there was involvement of mucosal surfaces such as gingival and nasal septum but no evidence of visceral involvement was found.

We note the importance of biopsy of unusual cutaneous manifestations in patients with polyarthritis. Histologic findings of skin lesions and synovium are similar and consist of diffuse

infiltration of true histiocytes with ground-glass cytoplasm and numerous multinucleated giant cells (3). The proliferating cells exhibit histologic and immunohistochemical characteristics of histiocytes or macrophages. S100 protein, alpha-1 antitrypsin and CD-1 are negative (2). The main radiologic feature is bilateral, symmetric joint involvement with predilection for the interphalangeal and metacarpophalangeal joints. Osteopenia is mild or absent. Radiography shows disproportionate bone destruction as compared to articular cartilage loss; resorption of subchondral bone can develop over a fairly short period of time leading to striking sharply circumscribed erosions spreading from the margins to the joint surfaces. It has been proposed that liberation of urokinase by activated histiocyte plays a role in the erosion of cartilage and bone in MRH (11). Since in most cases arthritis antedate skin manifestations the disease can be easily confused with rheumatoid arthritis, but in contrast to rheumatoid arthritis, periarticular osteoporosis and early joint space loss are absent in MRH (2). Compared to RA, MRH has the potential to be much more rapidly destructive; characteristic skin lesions and a negative RF also differentiate MRH from RA. In our case, progression of arthritis led to bilaterally symmetrical, sharply circumscribed, erosions spread from the margin to the joint surfaces similar to RA.

There is no effective treatment for MRH, Several treatment regimens have been tried, with variable results (12). The efficacy of different drug therapies is difficult to assess due to disease fluctuations and spontaneous remissions. Therapy with non-steroidal, anti-inflammatory agents and physical therapy may help. Systemic corticosteroids and/or cytotoxic agents in particular cyclophosphamide, chlorambucil, methotrexate, topical nitrogen mustard and also bisphosphonates may affect the inflammatory response and prevent further joint destruction and cause skin lesions to regress (13-15). In review of English-language literature we found only 13 cases of complete or near complete remission (2). The disease may slowly remit after 5-8 yr, leaving the patient with severe articular impairment. In our patient a 6-month course of oral prednisolone, oral methotrexate and monthly bolus of cyclophosphamide had no great effect but resulted

in partial remission. We used monthly bolus cyclophosphamide because of less toxic effects than daily oral cyclophosphamide. Skin lesions only diminished by 60% but destructive polyarthritis was progressive in spite of aggressive therapy with cyclophosphamide. She has only partial improvement in knee joints after injection of nitrogen mustard. Indeed, she had refractory disease in spite of combination therapy with steroids, methotrexate, monthly bolus of cyclophosphamide and chemical synoviorthesis.

REFERENCES

1. Barrow MV, Holubar K. Multicentric reticulohistiocytosis. A review of 33 patients. *Medicine (Baltimore)*. 1969 Jul; 48(4):287-305.
2. Liang GC, Granston AS. Complete remission of multicentric reticulohistiocytosis with combination therapy of steroid, cyclophosphamide, and low-dose pulse methotrexate. Case report, review of the literature, and proposal for treatment. *Arthritis Rheum*. 1996 Jan; 39(1):171-174.
3. Gorman JD, Danning C, Schumacher HR, Klippel JH, Davis JC Jr. Multicentric reticulohistiocytosis: case report with immunohistochemical analysis and literature review. *Arthritis Rheum*. 2000 Apr; 43(4):930-938.
4. Caro MR, Senear FE. Reticulohistiocytoma of the skin. *AMA Arch Derm Syphilol*. 1952 Jun; 65(6):701-713.
5. Uhl M, Gutfleisch J, Rother E, Langer M. Multicentric reticulohistiocytosis. A report of 3 cases and review of literature. *Bildgebung*. 1996 Jun; 63(2):126-129.
6. Joubeh S, Noohpishch MK, Sari Aslani F. [Multicentric reticulohistiocytosis: report of a case from Iran]. *Iran J Med Sci*. 1999; 24(3&4): 158-159.
7. Kocanaogullari H, Ozsan H, Oksel F, Ozturk G, Kandiloglu G, Ustun EE, Doganavsargil E. Multicentric reticulohistiocytosis. *Clin Rheumatol*. 1996 Jan; 15(1):62-66.
8. Mody GM, Cassim B. Rheumatologic manifestations of malignancy. *Curr Opin Rheumatol*. 1997 Jan; 9(1):75-79.
9. Valencia IC, Colsky A, Berman B. Multicentric reticulohistiocytosis associated with recurrent breast carcinoma. *J Am Acad Dermatol*. 1998 Nov; 39(5 Pt 2):864-866.

Multicentric reticulohistiocytosis

10. Zvaifler NJ. Uncommon arthropathies. In: Klippel JH, Dieppe PA, Eds. *Rheumatology*. 2nd edition. Mosby 1998; 5(28): 4-5.
11. Outland JD, Keiran SJ, Schikler KN, Callen JP. Multicentric reticulohistiocytosis in a 14-year-old girl. *Pediatr Dermatol*. 2002 Nov-Dec; 19(6):527-531.
12. Rentsch JL, Martin EM, Harrison LC, Wicks IP. Prolonged response of multicentric reticulohistiocytosis to low dose methotrexate. *J Rheumatol*. 1998 May; 25(5):1012-1015.
13. Cash JM, Tyree J, Recht M. Severe multicentric reticulohistiocytosis: disease stabilization achieved with methotrexate and hydroxychloroquine. *J Rheumatol*. 1997 Nov; 24(11):2250-2253.
14. Franck N, Amor B, Ayrat X, Lessana-Leibowitch M, Monsarrat C, Kahan A, Escande JP. Multicentric reticulohistiocytosis and methotrexate. *J Am Acad Dermatol*. 1995 Sep; 33(3):524-525.
15. Gourmelen O, Le Loet X, Fortier-Beaulieu M, Thomine E, Ledan G, Lauret P, Deshayes P. Methotrexate treatment of multicentric reticulohistiocytosis. *J Rheumatol*. 1991 Apr; 18(4):627-628.