

RECORDING OF VESTIBULAR EVOKED MYOGENIC POTENTIALS

A. A. Sazgar^{*1}, K. Akrami², S. Akrami² and A. R. Karimi Yazdi¹

- 1) Department of Otolaryngology and Head and Neck Surgery, Imam Khomeini Medical Center, School of Medicine, Tehran University of Medical Sciences, Tehran, Iran
- 2) Physical Medicine and Rehabilitation Ward, Imam Khomeini Medical Center, School of Medicine, Tehran University of Medical Sciences, Tehran, Iran

Abstract- It has been shown recently that loud clicks evoke myogenic potentials in the tonically contracting sternocleidomastoid muscles. Studies have suggested that these potentials are of vestibular origin, especially of the saccule and inferior vestibular nerve. A pilot study was undertaken in our hospital to record vestibular evoked myogenic potentials (VEMP) for the first time in Iran. Eighteen healthy volunteers (32 ears) without history of otologic or vestibular disorders were subjected to the VEMP test. Twenty-one patients (26 ears) with unilateral (6 patients) and bilateral (5 patients) high frequency sensorineural hearing loss with unknown etiology, acoustic neuroma (1 patient), Meniere's disease (4 patients) and unilateral low frequency sensorineural hearing loss without vestibular complaint (5 patients) were also enrolled in this study. VEMP response to clicks was obtained from 84.4% of ears of healthy subjects. These subjects demonstrated short latency waves to click stimuli during tonic neck flexor activation. Mean latencies of first positive (p13) and first negative (n23) potentials in healthy subjects were 12.45 ± 1.9 ms and 20.8 ± 3.5 ms, respectively. Median latencies of these two potentials were 12.1 and 19.3 ms, respectively. We could record VEMP in 5 patients with unilateral and all patients with high and low frequency sensorineural hearing loss without vestibular complaint. In the patient with acoustic neuroma VEMP was absent on the affected side. This technique may offer a new method to evaluate otolith and sacculocollic pathways in human.

Acta Medica Iranica, 44(1): 13-16; 2006

© 2006 Tehran University of Medical Sciences. All rights reserved.

Key words: Vestibular evoked myogenic potential, saccule, vestibule

INTRODUCTION

Inner ear composes of two main parts: cochlea and vestibule. Vestibular function is controlled by semicircular canals and otoliths (utricle and saccule). Auditory examinations such as auditory brainstem response (ABR) are clinical tests of the auditory pathway including the cochlea and cochlear nerve and the caloric test and rotatory chair test assess

semicircular canals and superior vestibular nerve activity. However, study of function of the otoliths, especially saccule, and the function of the direct vestibular projections to spinal cord in humans has proved difficult. Recently, it has been shown that loud clicks (85 to 100 dB above our reference) evoke myogenic potentials in the tonically contracting sternocleidomastoid (SCM) muscles (1, 2). Studies have suggested that these potentials are of vestibular origin, especially of the saccule and inferior vestibular nerve (3, 4). These myogenic potentials are called vestibular evoked myogenic potentials (VEMP) now.

For first time in Iran, in this study we attempted to record VEMP of normal subjects and patients with inner ear pathology (cochlear or vestibular).

Received: 31 Oct. 2005, Revised: 6 Dec. 2006, Accepted: 14 Dec. 2006

*** Corresponding Author:**

A. A. Sazegar, Department of Otolaryngology and Head and Neck Surgery, Imam Khomeini Medical Center, School of Medicine, Tehran University of Medical Sciences, Tehran, Iran
Tel: +98 21 66932288,
Fax: +98 21 66434020
E-mail: asazegar@ut.ac.ir

MATERIALS AND METHODS

This prospective study was performed from 2001 to 2003 at an otolaryngology and head and neck surgery referral center and a physical medicine and rehabilitation clinic.

Eighteen healthy volunteers from hospital staff and patients' families (12 woman and 6 men, ages ranged from 20 to 60 years, with a mean of 37 years), without known otologic or vestibular disorders were subjected to the VEMP test. Twenty-one patients (13 men and 8 women, age ranged from 18 to 65 years, with mean of 42 years) with unilateral (6 patients) and bilateral (5 patients) high frequency sensorineural hearing loss of unknown etiology, acoustic neuroma (1 patient), Meniere's disease (4 patients) and unilateral low frequency sensorineural hearing loss without vestibular complain (5 patients) were also enrolled in this study. All of patients with Meniere's disease (3 women and 2 men) had unilateral hearing loss, tinnitus, and vertigo. They weren't tested in the acute phase.

All of our subjects underwent thorough history and physical examination (*i.e.* head and neck and systemic). None of our subjects was taking vestibular suppressant medication. Every patient with unilateral or asymmetric sensorineural hearing loss underwent complementary studies (*i.e.* ABR and/or MRI) to rule out retro cochlear disorders. Air and bone-conducted pure tone audiometry, speech discrimination score (SDS), speech reception threshold (SRT) and tympanometry were performed with standard clinical procedures.

This study has ethics committee approval and has considered the declaration of Helsinki. We obtained informed consent from all patients.

VEMPs evoked by loud monaural clicks were recorded as previously described (1, 3). Briefly, each ear was stimulated twice by clicks. The clicks (0.1 ms rarefactive square waves of 110 dB) were

presented through calibrated head phones. For all of recordings, the subjects were seated and pressed their head against resistant to activated neck flexors.

Resistant force and neck flexor activity were tuned to keep electromyography (EMG) activity of sternocleidomastoid between 50–200 μ v during the study. Surface EMG activity was recorded from symmetrical sites over the upper half of each SCM with a reference electrode over the upper sternum and a ground electrode over central forehead. For each of the trials, the EMC responses were averaged over a series of 512 clicks delivered at a frequency of 10 pps (repetition rate).

VEMPs were recorded with a Medelec/Teca premiere plus with a 4-channel averaging capacity. The EMG from each side was amplified and band pass filtered (20 HZ–10 KHZ). Simultaneous average EMGs was 50 ms. Odd and even traces were stored and averaged separately; the two averaged records were compared at the end of each trail and had to be perfectly coincident to eliminate potential artifacts. As parameters of the latency for clicks, we measured the mean peak latency (in ms) of the two early waves (p13–n23) of the VEMPs as these potentials are of saccular origin. p13 is the first positive peak of VEMP and n23 is the first negative peak.

RESULTS

VEMP response in healthy subjects

VEMP response to clicks was displayed in 84.4% of ears from 32 healthy ears. These healthy controls demonstrated short latency waves to click stimuli during tonic neck flexor activation. Mean latencies of p13 and n23 in healthy subjects were 12.45 ± 1.9 ms and 20.8 ± 3.5 ms, respectively. Median latencies of these two potentials were 12.1 and 19.3 ms, respectively (Table 1, Fig. 1). In 6 subjects we could record some additional waves after n23 (Fig. 2).

Table 1. Mean latency of p13-n23 waves in healthy subjects

	N	Mean	Std.	95% confidence mean	
				Lower	Upper
p13 (ms)	27	12.45	1.952	11.68	13.22
n23 (ms)	27	20.08	3.518	18.69	21.48

Abbreviations: n, number; Std, standard deviation.

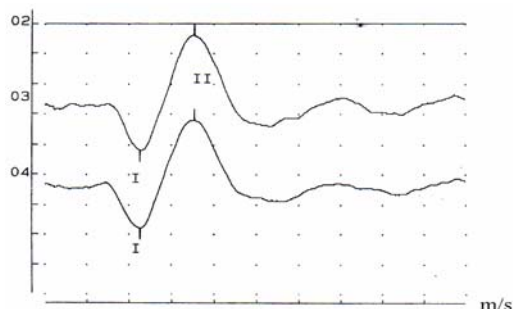


Fig 1. The first positive-negative peak of VEMP was present on both sides of 84% of 32 ears from healthy subjects. I, p13; II, n23.

VEMP response in patients

We could record VEMP in 5 patient with unilateral and all patient with high and low frequency sensorineural hearing loss without vestibular complain (Fig. 3). In the patient with acoustic neuroma VEMP was absent on the affected side. Among patients with Meniere's disease, stimulation of the affected ear evoked no p13–n23 response in SCM in four patients. In one patient there was a prolonged response (Fig. 4).

DISCUSSION

Recent studies have demonstrated that healthy subjects exhibit a burst of activity in the ipsilateral SCM in response to auditory stimulation. These click evoked responses are recorded with EMG and occur at a short latency relative to onset of the click stimulus. VEMP is now a well-established test to explore the sacculo-collic pathways in human. Loud monaural clicks evoke an initial inhibitory potential (p13-n23) in the tonically contracted ipsilateral sternocleidomastoid muscle (1, 2).

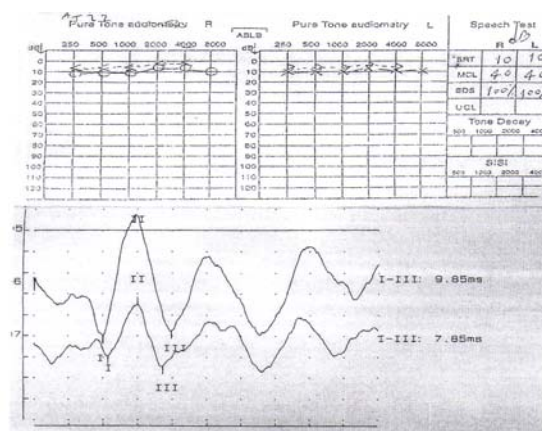


Fig 2. In some healthy subjects we recorded later potentials of VEMP (n34-p44) (pure tone audiometry, SRT and vestibular evoked myogenic potentials were presented).

The saccular origin of these potentials has been suggested in various studies (3, 4). The routine vestibular tests are difficult tasks and probably they can't assess saccular function, therefore the extent of the inner ear abnormality remains indefinite.

Therefore, recently attention is being focussed on VEMP as a potential electrophysiological method to reflect the function of saccule and inferior vestibular nerve. Additional benefits of this procedure is its ease and relative simplicity. Because of the importance of VEMP to screen and diagnose some disorders like Meniere's disease (5, 6), delayed endolymphatic hydrops (7), and acoustic neuroma (8), we must know the effects of various factors (such as age (9), musculoskeletal disorders, hearing loss (2), and so on) on VEMP results. For instance in evaluation of a suspicious Meniere's patient who has noise induced hearing loss or presbycusis, VEMP results can help to find out the effect of these disorders.

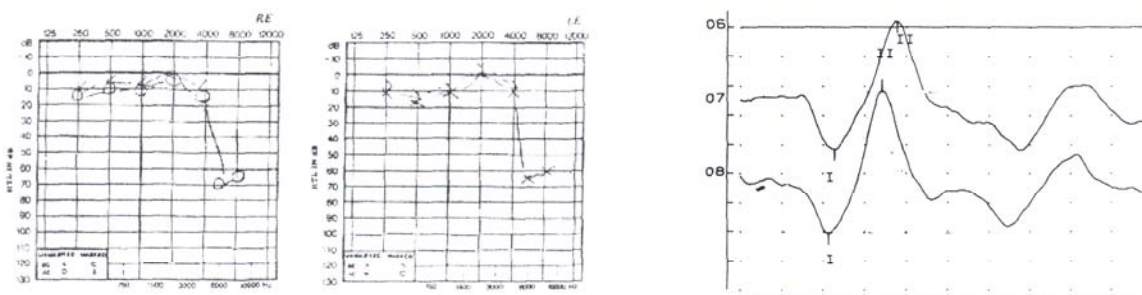


Fig. 3. Patient with bilateral high frequency sensorineural hearing loss and positive VEMP responses.

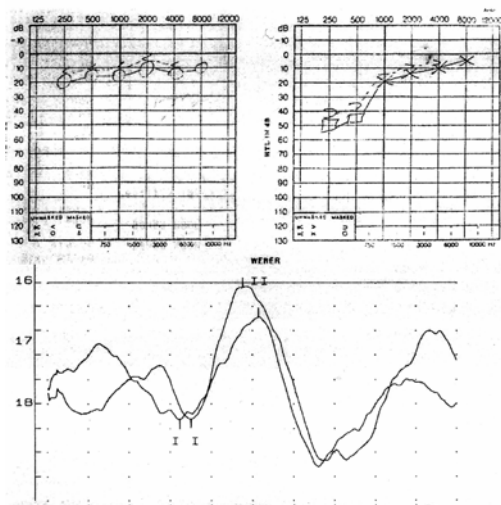


Fig. 4. Prolonged latency of wave in left side of a patient with Meniere's disease (p13, 17.5 ms; n23, 25.7 ms).

In this study, the mean latencies of p13-n23 were 12.45 ± 1.9 ms and 20.8 ± 3.5 ms, respectively, which are approximately similar to studies of Murofushi *et al.* (11.8 ± 0.86 ms and 20.3 ± 2.2 ms) and Welgampola *et al.* (12.0 ± 1 ms and 20.3 ± 1.7 ms) (10, 11). In our study, similar to some other studies, we did not observe VEMP response in all of our healthy subjects. Some reasons have been proposed for this observation (2, 5, 9). We could record additional waves after N23 in some normal cases. Other studies suggested that origin of these extra waves is cochlea (2, 5).

Neurophysiologic studies of guinea pigs showed results consistent with these clinical studies (12). In guinea pigs, primary vestibular afferents respond to loud clicks (60–70 dB) above the ABR threshold. Most click-sensitive primary afferents are saccular afferents. Absent and prolonged responses in Meniere's disease and absence of waves in acoustic neuroma may be related to vestibular pathology of these diseases (5, 8).

This technique may offer a new method to evaluate otolith and sacculocollic pathways in human. Accordingly sacculocollic pathways can be considered impaired when there is delayed or no response to loud clicks in this study.

Conflicts of Interests

We have no conflicts of interest.

REFERENCES

1. Colebatch JG, Halmagyi GM, Skuse NF. Myogenic potentials generated by a click-evoked vestibulocollic reflex. *J Neurol Neurosurg Psychiatry.* 1994 Feb;57(2):190-197.
2. Robertson DD, Ireland DJ. Vestibular evoked myogenic potentials. *J Otolaryngol.* 1995 Feb; 24(1):3-8.
3. Halmagyi GM, Colebatch JG. Vestibular evoked myogenic potentials in the sternomastoid muscle are not of lateral canal origin. *Acta Otolaryngol Suppl.* 1995;520 Pt 1:1-3.
4. Nong DX, Ura M, Kyuna A, Owa T, Noda Y. Saccular origin of acoustically evoked short latency negative response. *Otol Neurotol.* 2002 Nov; 23(6):953-957.
5. de Waele C, Huy PT, Diard JP, Freyss G, Vidal PP. Saccular dysfunction in Meniere's disease. *Am J Otol.* 1999 Mar;20(2):223-232.
6. Young YH, Wu CC, Wu CH. Augmentation of vestibular evoked myogenic potentials: an indication for distended saccular hydrops. *Laryngoscope.* 2002 Mar;112(3):509-512.
7. Ohki M, Matsuzaki M, Sugawara K, Murofushi T. Vestibular evoked myogenic potentials in patients with contralateral delayed endolymphatic hydrops. *Eur Arch Otorhinolaryngol.* 2002 Jan;259(1):24-26.
8. Murofushi T, Matsuzaki M, Mizuno M. Vestibular evoked myogenic potentials in patients with acoustic neuromas. *Arch Otolaryngol Head Neck Surg.* 1998 May;124(5):509-512.
9. Ochi K, Ohashi T. Age-related changes in the vestibular-evoked myogenic potentials. *Otolaryngol Head Neck Surg.* 2003 Dec;129(6):655-659.
10. Murofushi T, Shimizu K, Takegoshi H, Cheng PW. Diagnostic value of prolonged latencies in the vestibular evoked myogenic potential. *Arch Otolaryngol Head Neck Surg.* 2001 Sep;127(9):1069-1072.
11. Welgampola MS, Rosengren SM, Halmagyi GM, Colebatch JG. Vestibular activation by bone conducted sound. *J Neurol Neurosurg Psychiatry.* 2003 Jun;74(6):771-778.
12. Plotnik M, Sichel JY, Elidan J, Honrubia V, Sohmer H. Origins of the short latency vestibular evoked potentials (VsEPs) to linear acceleration impulses. *Am J Otol.* 1999 Mar;20(2):238-243.