

# UTERINE PERIVASCULAR EPITHELIOID CELL TUMOR: A CASE REPORT

G. Iravanlo\* and Z. Nozarian

Department of Pathology, Imam Khomeini Hospital, School of Medicine, Tehran University of Medical Sciences, Tehran, Iran

**Abstract-** Perivascular epithelioid cell tumor (PEComa) is composed of HMB45<sup>+</sup> epithelioid cells with clear to granular cytoplasm and perivascular distribution. We describe a uterine PEComa in a 33 years old woman where tumor cells were positive for HMB45 but negative for epithelial markers and negative or positive for smooth muscles markers.

*Acta Medica Iranica*, 44(1): 63-64; 2006

© 2006 Tehran University of Medical Sciences. All rights reserved.

**Key word:** Uterus. perivascular epithelioid cells Tumor, PECOMA, HMB45, Angiomyolipoma

## INTRODUCTION

Epithelioid mesenchymal tumors of the uterus were previously considered to be either from smooth muscle or endometrial stromal lineage. But recently a new family of lesions have been described including HMB45 positive epithelioid cells with clear to eosinophilic granular cytoplasm and a propensity for a per vascular distribution. These tumors are termed perivascular epithelioid cell tumors (PEComa) (1-3). The major clinical manifestation of such tumors are abnormal uterine bleeding, mass and abdominal pain (1).

Here we report of a uterine PEComa in a 33 years old woman.

## CASE REPORT

A 33 years old woman was referred to cancer institute with a history of a uterine mass which was noticed 3 years ago within a cesarian section and grossly was considered myoma (but no excision was

performed). After one year patient returned with abdominal pain and vaginal bleeding and was operated. The gross examination showed multiple creamy round masses in myometrium with foci of hemorrhage, measuring totally 20×10×8 cm in diameter. On microscopic examination, leiomyosarcoma was reported. Immunohistochemistry (IHC) was performed and findings were as follows: positive HMB45, SMA and negative desmin, myogenin, S100, chromogranin, synaptophysin and EMA. After eight months, the patient manifested colonic and omental seeding and underwent operation.

Histopathologic findings were equal to uterine mass. Second IHC consultation suggested malignant melanoma according to positive S100 and HMB45. During treatment a control sonography was performed and revealed a large hypochoic retroperitoneal mass 99×63×58 mm without para aortic lymphadenopathy. The mass was excised and referred to our center. After routine processing of the specimen, several H&E stained slides were prepared which revealed a tumor composed of pleomorphic large cells arranged in irregular sheets with delicate fibro vascular stroma and vast area of necrosis and high mitotic figure (Fig. 1).

Immunohistochemically, the neoplastic cells were strongly positive for HMB45 and focally expressed SMA and S100. Immunostains for desmin, myogenin and melan-A were negative.

Received: 11 Aug. 2004, Revised: 13 Mar. 2005, Accepted: 13 Apr. 2005

### \* Corresponding Author:

Z. Nozarian, Department of Pathology, Imam Khomeini Hospital, Cancer Institute, School of Medicine, Tehran University of Medical Sciences, Tehran, Iran  
Tel: +98 21 77937847,  
Fax: +98 21 77937847  
E-mail: z\_nozarian@yahoo.com

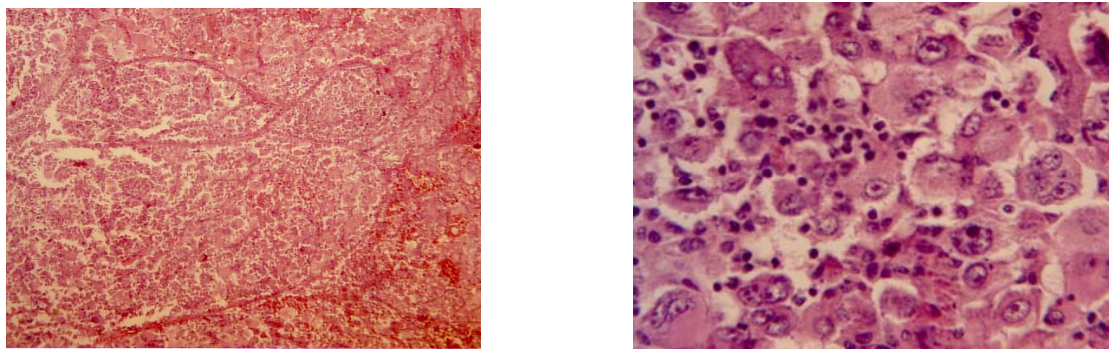


Fig. 1. H&E staining revealed a tumor composed of pleomorphic large cells arranged in irregular sheets with delicate fibrovascular stroma and vast area of necrosis and high mitotic figure.

## DISCUSSION

Recently a subset of uterine epithelioid neoplasm has been shown to be composed of cells that express HMB45<sup>+</sup> similar to perivascular epithelioid cells in angiomyolipoma and lymphangiomyomatosis as well as clear cell sugar tumor (cc- sugar) (1).

Important differential diagnoses include angiomyolipoma, lymphangiomyomatosis, endometrial stromal sarcoma and epithelioid leiomyosarcoma. These distinctions are arguably important because it would appear that PEComa possibly is less aggressive than sarcoma although it is more aggressive than angiomyolipoma (1, 2). Leiomyosarcoma differ from PEComa in that it displays fascicle with more pronounced cytoplasmic eosinophilia and elongated nuclei with small prominent nucleoli. More clear cell changes that characterize clear cell myomelanocytic tumor would not usually be expected in leiomyosarcoma (2). Also leiomyosarcoma has not been reported to be positive for melanosomal protein and unlike PEComa usually are desmin positive (2, 3). PEComa also should be distinguished from angiomyolipoma that usually has triphasic features but monotypic purely epithelioid angiomyolipoma have been described (2). In literature there are two patients with uterine PEComa that their pelvic lymph Nodes by lymphangiomyomatosis (1).

In conclusion, we have presented a case of uterine PEComa which was previously described as malignant melanoma, high grand malignant tumor and epithelioid leiomyosarcoma respectively by

different pathologists. Therefore, melanocytic markers should be investigated in any presumed smooth muscle cell tumor. Although most PEComas behave in a benign fashion, long-term behavior is unknown and a presumed metastasis in many cases suggests some metastatic potential (4, 5).

## REFERENCES

1. Vang R, Kempson RL. Perivascular epithelioid cell tumor ('PEComa') of the uterus: a subset of HMB-45-positive epithelioid mesenchymal neoplasms with an uncertain relationship to pure smooth muscle tumors. *Am J Surg Pathol.* 2002 Jan; 26(1):1-13.
2. Folpe AL, Goodman ZD, Ishak KG, Paulino AF, Taboada EM, Meehan SA, Weiss SW. Clear cell myomelanocytic tumor of the falciform ligament/ligamentum teres: a novel member of the perivascular epithelioid clear cell family of tumors with a predilection for children and young adults. *Am J Surg Pathol.* 2000 Sep; 24(9):1239-1246.
3. Folpe AL, McKenney JK, Li Z, Smith SJ, Weiss SW. Clear cell myomelanocytic tumor of the thigh: report of a unique case. *Am J Surg Pathol.* 2002 Jun; 26(6):809-812.
4. Pan CC, Yang AH, Chiang H. Malignant perivascular epithelioid cell tumor involving the prostate. *Arch Pathol Lab Med.* 2003 Feb; 127(2):E96-8.
5. D'Andrea V, Lippolis G, Biancari F, Ruco LP, Marzullo A, Wedard BM, Di Matteo FM, Sarmiento R, Dibra A, De Antoni E. [A uterine pecoma: a case report] *G Chir.* 1999 Apr; 20(4):163-164. Italian.