

# RADIAL AMNIOTIC FLUID INDEX AS A NEW AND ACCURATE METHOD FOR MEASUREMENT OF AMNIOTIC FLUID VOLUME

M. Pourissa<sup>\*1</sup>, S. Refahi<sup>2</sup>, R. Pezeshky<sup>1</sup> and A. Aghazadeh<sup>1</sup>

1) Department of Radiology, School of Medicine, Tabriz University of Medical Sciences, Tabriz, Iran

2) Department of Radiology, School of Medicine, Ardebil University of Medical Sciences, Ardebil, Iran

---

**Abstract-** Amniotic fluid volume (AFV) is one of the important parameters in the assessment of fetal well-being. The ability of ultrasound measurements to represent the actual AFV is unproven. This study was undertaken to compare correlation of conventional amniotic fluid index (AFI) and radial amniotic fluid index (RAFI) as a new method with actual fluid volume on phantom. As an experimental study, 10 to 100 ml of water with 5 ml intervals was injected to a rubber bladder as a uterus phantom containing a 15 week gestational age fetus. The vertical diameter was measured in largest fluid pouch at each quadrant. Four diameters were summed as conventional AFI. The largest radial diameter perpendicular to uterus and fetus was measured at four quadrants and were summed as RAFI. Databases were analyzed based on correlation and regression methods. RAFI and conventional AFI predicted 91.6% and 65% of variations of fluid volume, respectively ( $P < 0.001$ ). In conclusion, RAFI is more accurate and reliable than conventional AFI in the prediction of injected fluid volume.

*Acta Medica Iranica*, 44(2): 101-104; 2006

©2006 Tehran University of Medical Sciences. All rights reserved.

**Key words:** Amniotic fluid index; amniotic fluid volume; ultrasonography

---

## INTRODUCTION

Amniotic fluid volume (AFV) is one of the important parameters in the assessment of fetal well-being. Abnormalities of amniotic fluid volume are associated with an increased incidence of fetal and neonatal morbidity and mortality (1-3). The prenatal diagnosis of oligohydramnios and polyhydramnios is important in the management of pregnancy. Although invasive methods such as the indicator dilution technique offer quantitative accuracy, they carry the inherent risks of amniocentesis (4). Invasive methods are time consuming, expensive, and not readily available. These methods are favored investigational tools for researchers, but these

techniques are not accepted by patients for routine or repeated measurement of AFV. Conversely, non-invasive sonographic methods of AFV assessment are safe, rapid, cost-efficient, available, accepted, and repeatable; however, the ability of ultrasound measurements to represent the actual AFV is unproven. Currently, the following three semiquantitative ultrasonographic techniques are most often used for evaluating of AFV: amniotic fluid index (AFI) (5, 6), single deepest vertical pocket (7, 8), and two-diameter pocket (9, 10). These methods are poor predictors of actual AFV when compared with dye-dilution method (11). Even though sonographic assessment of AFV has been attempted for more than 2 decades, there is still no consensus on the best method to report the status of AFV in an individual patient. The AFI is probably the best of the semiquantitative methods available for AFV assessment, but it should not be considered to be without its own inherent limitations (12).

Received: 5 Jul. 2004, Revised: 12 Feb. 2005, Accepted: 12 Apr. 2005

**\* Corresponding Author:**

M. Pooreisa, Department of Radiology, School of Medicine, Tabriz University of Medical Sciences, Tabriz, Iran  
Tel: +98 411 3324626, Fax: +98 411 3345591  
E-mail: masoudpe@yahoo.com

In this study we introduce a new method with new indices for assessment of amniotic fluid volume using a uterus phantom containing a 15 week gestational age aborted fetus. Then we compared these new indices with AFI. The purpose of this study was to introduce an accurate and reliable method for measurement of actual amniotic fluid volume.

## MATERIALS AND METHODS

A rubber bladder containing a 15 week gestational age aborted fetus was considered as uterus phantom. In the human being uterus is compressed antero-posteriorly between rectus muscles and spinal column so uterine volume increases superiorly and laterally rather than anteroposteriorly. For obtaining similar effect, the phantom was covered with another rubber band anteroposteriorly. According to our preliminary examination we found 10 ml to 100 ml fluid injection with 5 ml intervals as suitable. We preferred small sizes for comfortable and minute measurements but propagation for larger sizes was available by doubling of diameters and 8 folding of volumes for each database. After injecting of each specific volume fluid to uterus phantom, the fluid indices were measured three times on different situation of fetus by a sonographer who was not aware of injected fluid volume. All sonographies were performed by the same physician with a general electric device. All scans were taken by a 7.5 MHz linear probe.

The indices were measured by two methods as following:

In the first method, the uterus phantom was divided into four quadrants by a midsagittal and a transverse line crossing the middle of mid sagittal line. The radial diameter perpendicular to uterus wall and fetus was measured in largest fluid pouch at each quadrant. Four diameters were summed as RAFI. The probe was applied completely free on the phantom for measurement of radial diameters.

The second method was performed according to AFI method suggested by Phelan *et al.* (5) and then by Moore (13). The uterus phantom was divided into

four quadrants. The transducer was held parallel to the sagittal plan and perpendicular to the coronal plan of uterus phantom. The vertical diameter was measured in largest fluid pouch at each quadrant. Four diameters were summed as conventional AFI.

Fluid was injected with intervals of 5 ml and from 10 to 100 ml and the sonographer obtained indices by two above mentioned methods. Each volume was measured three times on different days and sonographer was not aware of injected fluid volume.

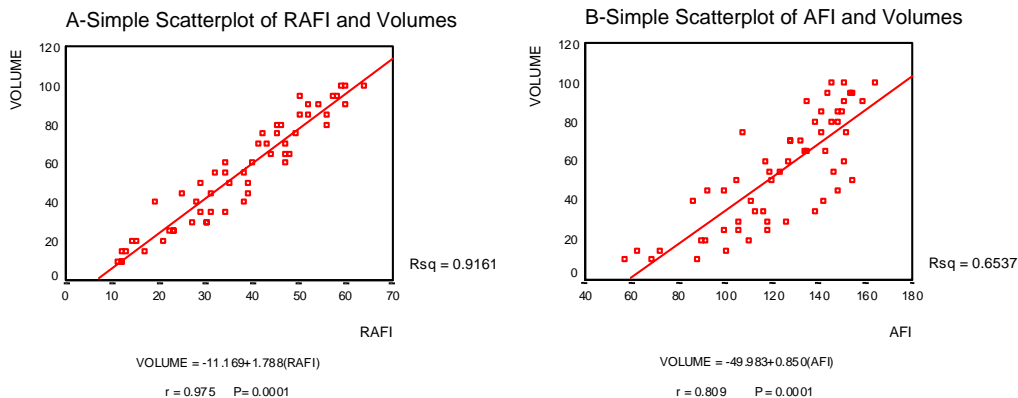
The obtained databases were analyzed based on correlation and regression method as well as reliability with the use of SPSS version 11.

## RESULTS

All three measurement values of AFI for each injected fluid volumes were used in obtaining Pearson correlation. The correlation of AFI with injected fluid volume was 0.809 ( $r = 0.809$ ,  $P = 0.0001$ ). Sixty-five percent of variation of fluid volume was predicted by conventional method ( $r^2 = 65\%$ ,  $P < 0.001$ ). Similar to conventional method, three measurements of RAFI for each injected fluid volume were used for evaluation of predicted variation of fluid volume. The correlation of RAFI with injected fluid volume was 0.975 ( $r = 0.975$ ,  $P = 0.0001$ ). RAFI method predicted 91.6% of variation of fluid volume ( $r^2 = 91.6\%$ ,  $P < 0.001$ ).

For each method simple scatterplot and linear regression line was designed (Fig. 1-A, B). For evaluation of reliability, the results of correlation between times of measurements by new RAFI method are as follows: the correlation of first with second time was 0.90 ( $r = 0.90$ ), the correlation of first with third time was 0.88 ( $r = 0.88$ ) and the correlation of second with third time was 0.95 ( $r = 0.95$ ).

The results of correlation between times of measurements by conventional AFI method are as follows: the correlation of first with second time was 0.53 ( $r = 0.53$ ), the correlation of first with third time was 0.41 ( $r = 0.41$ ) and the correlation of second with third time was 0.88 ( $r = 0.88$ ).

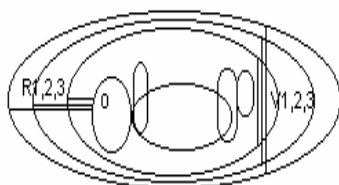


**Fig.1.** Simple scatterplot of RAFI (A) and AFI (B) with injected fluid volume.

### DISCUSSION

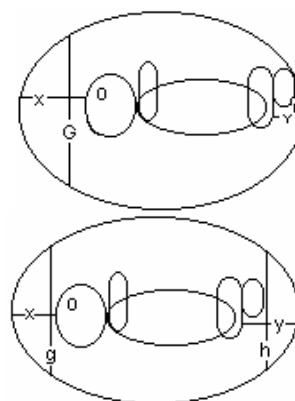
As the results revealed, new RAFI method is more reliable than conventional AFI. The RAFI method is also more accurate than conventional AFI in predicting injected fluid volume. With attention to AFI simple scatterplot (Fig.1-B) it is clear that in lower volumes the amount of volume is overestimated and in higher volumes the amount of volume is underestimated with AFI, a finding in accordance with Dildy’s study (11).

The new technique is more accurate for the following reasons: According to schematic diagram shown in fig. 2, because of compression effects of rectus muscles and spinal column, the expansion of uterus by increasing amniotic fluid volume causes smaller changes in vertical dimension of the largest pocket compared to radial dimension and in this dimension the interval between uterus and fetus is increased proportionately. Therefore by using radial method, the variation of fluid volume is predicted more accurately.



**Fig. 2.** Vertical and radial changes of fluid pouches with increasing amount of amniotic fluid volume.

Two states with the same volume of fluid and different situations of fetus within the uterus are considered in fig. 3. According to upper schematic diagram, at vertical method two measured dimensions of G and H are summed and G + H is obtained. According to lower schematic diagram with another situation of fetus and same volume, two vertical dimensions of g and h are measured and g + h is obtained. It is clear that G + H is < g + h. Therefore with an equal volume of fluid and different situation of fetus, the obtained values by vertical method are not equal. But in radial technique, X + Y, obtained by two measured radius of X and Y, is equal to x + y obtained by two measured radius of x and y at second fetus situation. Therefore the radial method is more accurate than vertical method in prediction of actual amniotic fluid volume and is also more reliable.



**Fig.3.** Different position of fetus with almost the same amniotic fluid volume.

### Conflicts of interests

We have no conflict of interests.

### REFERENCES

1. Blackwell SC, Hassan SS, Berry SM, Treadwell MC, Zador I, Wolfe HM. Abnormal amniotic fluid volume as a screening test prior to targeted ultrasound. *Med Sci Monit.* 2003 Nov; 9(11):MT119-122.
2. Tsatsaris V, Gagnadoux MF, Aubry MC, Gubler MC, Dumez Y, Dommergues M. Prenatal diagnosis of bilateral isolated fetal hyperechogenic kidneys. Is it possible to predict long term outcome? *BJOG.* 2002 Dec; 109(12):1388-1393.
3. Aubertin G, Cripps S, Coleman G, McGillivray B, Yong SL, Van Allen M, Shaw D, Arbour L. Prenatal diagnosis of apparently isolated unilateral multicystic kidney: implications for counselling and management. *Prenat Diagn.* 2002 May; 22(5):388-394.
4. Nikkila A, Valentin L, Thelin A, Jorgensen C. Early amniocentesis and congenital foot deformities. *Fetal Diagn Ther.* 2002 May-Jun; 17(3):129-132.
5. Phelan JP, Smith CV, Broussard P, Small M. Amniotic fluid volume assessment with the four-quadrant technique at 36-42 weeks' gestation. *J Reprod Med.* 1987 Jul; 32(7):540-542.
6. Myles TD, Strassner HT. Four-quadrant assessment of amniotic fluid volume: distribution's role in predicting fetal outcome. *Obstet Gynecol.* 1992 Nov; 80(5):769-774.
7. Moore TR. Superiority of the four-quadrant sum over the single-deepest-pocket technique in ultrasonographic identification of abnormal amniotic fluid volumes. *Am J Obstet Gynecol.* 1990 Sep; 163(3):762-767.
8. Jeng CJ, Jou TJ, Wang KG, Yang YC, Lee YN, Lan CC. Amniotic fluid index measurement with the four-quadrant technique during pregnancy. *J Reprod Med.* 1990 Jul; 35(7):674-677.
9. Magann EF, Nolan TE, Hess LW, Martin RW, Whitworth NS, Morrison JC. Measurement of amniotic fluid volume: accuracy of ultrasonography techniques. *Am J Obstet Gynecol.* 1992 Dec; 167(6):1533-1537.
10. Chauhan SP, Magann EF, Morrison JC, Whitworth NS, Hendrix NW, Devoe LD. Ultrasonographic assessment of amniotic fluid does not reflect actual amniotic fluid volume. *Am J Obstet Gynecol.* 1997 Aug; 177(2):291-296
11. Dildy GA 3rd, Lira N, Moise KJ Jr, Riddle GD, Deter RL. Amniotic fluid volume assessment: comparison of ultrasonographic estimates versus direct measurements with a dye-dilution technique in human pregnancy. *Am J Obstet Gynecol.* 1992 Oct; 167(4 Pt 1):986-994.
12. Callen PW. *Ultrasonography in Obstetrics and Gynecology.* 4<sup>th</sup> ed. Philadelphia: WB Saunders; 2000. p. 638-653.
13. Moore TR. Clinical assessment of amniotic fluid. *Clin Obstet Gynecol.* 1997 Jun; 40(2):303-313.