

# A MODIFIED TECHNIQUE OF INFERIOR ALVEOLAR NERVE REPOSITIONING: RESULTS IN 11 PATIENTS

H. Mahmood-Hashemi\*

Department of Oral and Maxillofacial Surgery, Faculty of Dentistry, Tehran University of Medical Sciences, Tehran, Iran

**Abstract-** Most often in the posterior of the mandible of patients who need implants, the inferior alveolar nerve (IAN) is too high to insert the implants, and the surgeons have to reposition IAN. In conventional techniques (to make the windows in the buccal aspect of the mandible) removal of the corticocancellous bone may cause weakness of the mandible. Here we present a new technique in which the bone is removed to a lesser extent and the IAN is best protected by the curet. This new technique is called the guard technique. As a primary report, evaluation of 11 patients (who were treated by this technique) is reported. There were few complications and IAN function was preserved in all patients. The mean time which the patients had temporary anesthesia was 7.3 days and the mean time that complete function of the nerve was returned was 3.3 months. Meanwhile the surgeon should also make an effort to make surgery and osteotomy far from the IAN. Most of the surgeons always avoid involving the IAN in a mandibular surgery; therefore, sometimes, they have to replace the IAN. Primary results of the new technique are promising.

*Acta Medica Iranica*, 44(4): 273-276; 2006

© 2006 Tehran University of Medical Sciences. All rights reserved.

**Key words:** inferior alveolar nerve, mandible, osteotomy

## INTRODUCTION

The preservation of the inferior alveolar nerve (IAN) in a mandibular surgery depends on the skill of surgeon. The surgeon should make an effort to perform surgery and osteotomy far from the IAN. When it is not possible, they have to reposition the IAN.

Repositioning of IAN is necessary in the following cases: a) in the orthognathic surgeries such as lower border shaving (1) and total mandibular subapical osteotomy (2); b) in the preprosthetic surgery (3), c) inserting implant in the posterior of the mandible (4-6), d) in the anastomosis and repairing of a disrupted IAN (7), and e) the preservation of IAN in the cancer surgery in the

posterior of the mandible (8).

Most of the studies related to the repositioning of IAN are available on inserting implants. If the height of the mandibular body is too low to insert the implant, one of the following procedures must be chosen: first, augmenting the ridge with the bone graft and the vestibuloplasty in the next surgery; second, repositioning of IAN. First method usually is not chosen, because it causes many problems such as hospitalization, taking bone graft, long term treatment and the risks of bone graft. Because it can be performed locally, the second method is an appropriate way and is more acceptable for the patients.

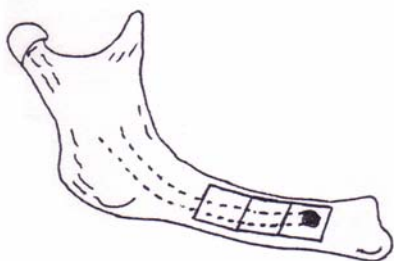
In this regard, most of the techniques that have been presented in the reference books and articles include making windows in the buccal aspect of the mandible, taking it by corticotomy with osteotome and also removing some cancellus bone (Fig. 1).

Here we present a new technique called the guard technique which is easier to perform and has less complications.

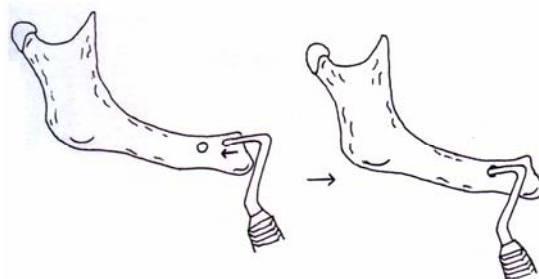
Received: 2 Jan. 2004, Revised: 29 May 2005, Accepted: 6 Aug. 2005

### \* Corresponding Author:

H. Mahmoodhashemi, Department of Oral and Maxillofacial Surgery, Faculty of Dental, Tehran University of Dental Sciences, Tehran, Iran  
Tel: +98 21 22226565,  
Fax: +98 21 22826989  
E-mail: hashemi5212@yahoo.com



**Fig. 1.** Conventional technique to inferior alveolar nerve repositioning.

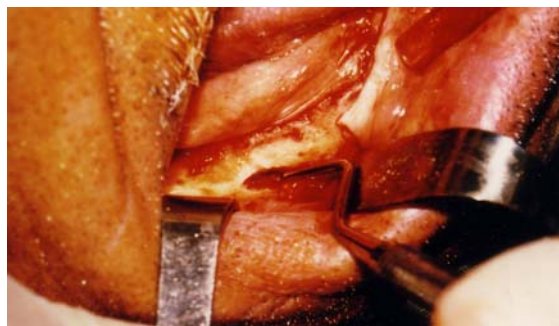

**Fig. 2.** Inserting the curet to the mental foramen in modified technique.

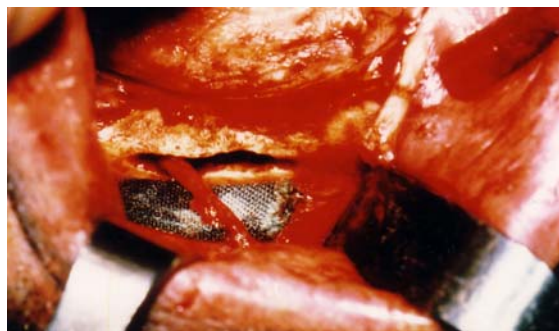
## MATERIALS AND METHODS

After preparing the patient in usual ways and local anesthesia (includes IAN, lingual and long buccal block), a vertical incision is made in the site of the canine tooth; it is followed by the crestal incision and continued to the side of the second molar. If it is necessary, another vertical incision is made in the end of the crestal incision. Then the mental nerve can be separated from the bony foramen by a small current with a width of 1.5-2 millimeter. Then the curet is plunged into the mandibular canal in the proximal direction. In fact, the curette will be put between the bone and the nerve. Above mentioned procedure is done to protect the nerve. When the curette is plunged into the canal, the corticocancellous bone can be removed by a small round bur (Fig. 2, 3).

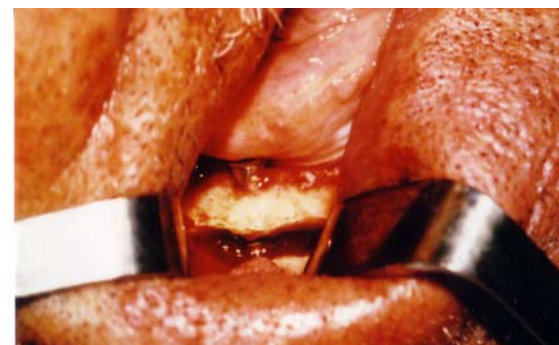In this procedure, the buccal bone can be removed about 2 to 3 mm, then the curette again will be plunged into the canal and this procedure can be repeated along the canal. Even if we want to replace the nerve easily, we can widen the groove more by using a wider curet or by replacing vertically the first curet. Now, the IAN can be separated, therefore, we can bring it cut from canal. If it is necessary to release the IAN completely, we can separate the continuation of the nerve in the distal side of mental foramen (which runs to anterior part of the mandible) (Fig. 4). Then the implants will be inserted, and the IAN can be returned in to this bony groove (Fig. 5). Since the IAN is protected by the curette, this technique was called the guard technique.



**Fig. 3.** Plunging the curet into the canal.



**Fig. 4.** Bony groove and released nerve are seen (A small green cloth is put under the nerve).



**Fig. 5.** Good primary stability for implants will be gained in the guard technique.

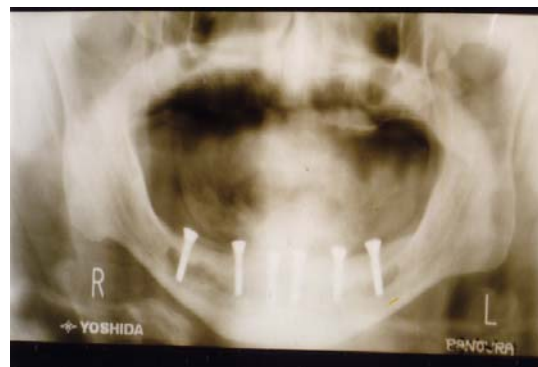## RESULTS

This technique has been used and tried on 11 patients so far (Fig. 6). The mean age of our patients was 45.3 years. Two cases have been done to shave the lower border of mandible and the rest 9 cases have been done to insert implants, as shown in table 1.

There were few complications and IAN function was preserved in all patients. The mean time which the patients had temporary anesthesia was 7.3 days and the mean time that complete function of the nerve was returned was 3.3 months.

## DISCUSSION

As mentioned before, repositioning of IAN has been used more frequently during insertion of implants. In these cases, a technique should be used which is faster and more harmless. In previous techniques, it has been suggested to make the windows in cortical bone and remove the cancellus bone that seems the corticocancellous bone has been removed more than necessary that causes weakness of the mandible, also removing cancellus bone with rongeur and any guard for IAN is dangerous, and always using osteotome and mallet under local anesthesia is unpleasant for patients.



**Fig. 6.** The panoramic image shows the line of radiolucency due to bone removed and position of the fixtures.

In the beginning of the guard technique, surgeon must have patience. But after inserting the curette into the canal, rest of the procedures should be continued rapidly. It is important to protect IAN and avoid it from the curette pressure. Osteotome and mallet are not used in this guard technique and this technique is performed easily under the local anesthesia. The bone removal is less which is one of the basis aims and strategies in the atrophic mandible.

Primary results of the new technique are promising but further studies must be done.

### Conflict of interests

We have no conflicts of interests.

**Table 1.** Demographic data of 6 month evaluation of IAN function in 11 patients treated by the Guard technique

No	Sex	Age	E.L or B.L N.R	Indication	TA (Day)	CF (Month)
1	M	46	B.L	IMP	8	2.5
2	F	53	E.L	IMP	6	3
3	M	64	B.L	IMP	9	3.5
4	F	25	E.L	L.B.S	12	4
5	M	60	E.L	IMP	8	3.5
6	M	39	B.L	IMP	6	3
7	M	38	B.L	IMP	7	3
8	F	49	B.L	IMP	7	3.5
9	M	24	E.L	L.B.S	13	4.5
10	F	57	B.L	IMP	8	3.5
11	F	44	E.L	IMP	7	3

Abbreviations: EL, Epsilateral; BL, Bilateral; NR, Never Release; IMP; Implant L.B.S lower border shaving; TA, Temporary Anesthesia of I.A.N; CF, Time that complete function of the nerve was returned.

## **REFERENCES**

1. Epker BN, Wolford LM. Dentofacial deformities surgical-orthodontic correction. St. Louis: Mosby Company; 1980. p. 172.
2. Bell WH. Modern practice in orthognatic and reconstructive surgery. Philadelphia: W.B. Saunders Company; 1992. p. 2500.
3. Peterson SJ, Indresano AT, Marciani RD, Roser SM. Principles of oral and maxillofacial surgery. Philadelphia: Lippincott Company; 1992. p. 1113.
4. Jensen O, Nock D. Inferior alveolar nerve repositioning in conjunction with placement of osseointegrated implants: a case report. Oral Surg Oral Med Oral Pathol. 1987 Mar; 63(3):263-268.
5. Rosenquist B. Fixture placement posterior to the mental foramen with transpositioning of the inferior alveolar nerve. Int J Oral Maxillofac Implants. 1992 Spring; 7(1):45-50.
6. Friberg B, Ivanoff CJ, Lekholm U. Inferior alveolar nerve transposition in combination with Branemark implant treatment. Int J Periodontics Restorative Dent. 1992; 12(6):440-449.
7. Peterson LJ, Indresano AT, Marciani RD, Roser SM. Principles of oral and maxillofacial surgery. Philadelphia: Lippincott Company; 1992. p. 1072.
8. De Vicente JC, Lopez-Arranz JS. Preservation of the inferior alveolar nerve in the surgical approach to cancer of the posterior oral cavity. J Oral Maxillofac Surg. 1998 Oct; 56(10):1214-1216.