

DIFFICULT AIRWAY MANAGEMENT IN A PATIENT WITH TREACHER-COLLIN'S SYNDROME WITH INTUBATING LARYNGEAL MASK AIRWAY

M. Gharebaghian*

Department of Anesthesiology and Intensive Care, Imam Khomeini Hospital Complex, Tehran University of Medical Sciences, Tehran Iran

Abstract- Treacher Collin's syndrome (TCS) is a rare inherited condition characterized by bilateral and symmetric abnormalities of structures within the first and second bronchial arches. Patients with TCS present a serious problem to anesthetists maintaining their airway as upper airway obstruction and difficult tracheal intubation due to severe facial deformity. Because of retrognathia, airway management of these patients is often challenging. We report the case of a 25-yr-old patient with TCS undergoing microtia repair under general anesthesia twice. In the first time he could not be intubated via direct laryngoscopy and was intubated via blind nasal intubation. In the second time, he was intubated through an ILMA using endotracheal tube.

Acta Medica Iranica, 44(4): 281-284; 2006

© 2006 Tehran University of Medical Sciences. All rights reserved.

Key words: Treacher-Collin's syndrome, difficult intubation, intubating laryngeal mask airway

INTRODUCTION

Treacher Collin's syndrome (TCS) or mandibulofacial dysostosis, is a rare inherited condition characterized by bilateral and symmetric abnormalities of structures within the first and second bronchial arches. The mechanism of inheritance is autosomal dominant with variable expressivity. Because of this variability in expression, some affected individuals exhibit virtually no overt clinical manifestations. However, most patients with TCS present with the following classic facial features: down-sloping palpebral fissures, colobomata of the lower eyelid, scanty lower eyelashes, malar hypoplasia, and micro- or retrognathia (1).

Patients with TCS present a serious problem to anesthetists maintaining their airway as upper airway obstruction and difficult tracheal intubation due to severe facial deformity make such a task difficult (2, 3). Because of retrognathia, airway management of these patients is often challenging (2). Awake fiberoptic intubation, the well-accepted technique for difficult intubation, can be uncomfortable and stressful for the patient and requires expertise, and hence may not be suitable for emergency patients and those who refuse to be intubated awake (4). Intubating laryngeal mask airway (ILMA, commercial name Fastrach) is a novel device for use in cases of difficult or failed intubation (5).

We report the case of a 25-yr-old patient with TCS undergoing microtia repair twice.

In the first time he could not be intubated via direct laryngoscopy and was intubated via blind nasal intubation. In the second time, he was intubated through an ILMA using endotracheal tube (ETT).

Received: 23 Dec. 2004, Revised: 7 July 2005, Accepted: 8 Aug. 2005

* Corresponding Author:

M. Gharebaghian, Department of Anesthesiology and Intensive Care, Imam Khomeini Hospital Complex, School of Medicine, Tehran University of Medical Sciences, Tehran, Iran
Tel: +98 21 66438634
Fax: +98 21 66438634
E-mail: mahin40@yahoo.com

CASE REPORT

A 25-year-old male patient, known case of Treacher Collin's syndrome, presented with bilateral microtia. He needed multiple stages of bilateral auriculoplasty. At the first time in April 2004, the patient was scheduled for procedures to correct microtia of the left side, *i.e.* framework insertion and local correction under general anesthesia. He had no history of previous general anesthesia or difficult tracheal intubation. Protruding upper incisors (Fig. 1), prominent premaxillas, retrognathia, short thyromental (5 cm) and sternomental (12 cm) (Fig. 2) and interincisor distances (4 cm) and Mallampathi class of IV (6) and upper lip bite test (ULBT) class of III (7) were revealed on preoperative airway examination and difficult intubation was anticipated. A difficult intubation tray was made available in the operating room. The patient was connected to EKG, non-invasive blood pressure and pulse oximeter monitors. After premedication with iv fentanyl 1.5 mcg/kg and midazolam 2 mg and preoxygenation, anesthesia was induced with thiopentone 5 mg/kg followed by succinylcholine 1 mg/kg. Face mask oxygen ventilation was easy. The plan was to pass an intratracheal tube (ID 8 mm) via direct laryngoscopy with a Macintosh blade (size 3). On laryngoscopy the patient was classified as Grade 3 Cormack and Lehane view (8) and was not intubated after several attempts. Later, he was intubated via blind nasal way (ETT 7.5) and he labeled as difficult tracheal intubation but with easy face mask ventilation after induction of anesthesia.

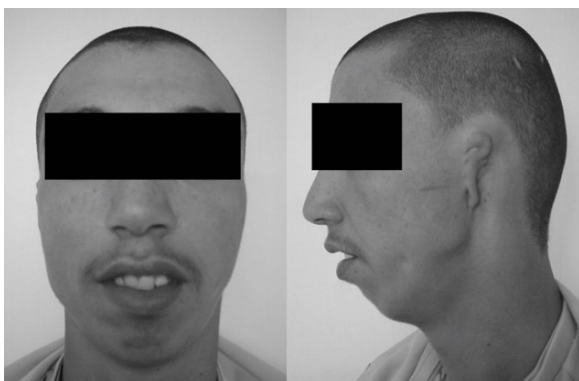


Fig. 1. Treacher Collin's syndrome patient showing protruding upper incisors (front view) and retrognathia (lateral view).

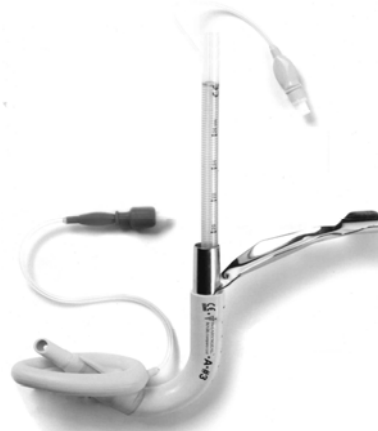

Fig. 3. Intubating Laryngeal Mask Airway showing an ETT inserted through a metal stem of ILMA.

After four months, in another session of right auriculoplasty and framework insertion reconstructive surgery under general anesthesia, because the patient was unwilling to undergo awake intubation, he was planned for intubation of trachea through the ILMA, after induction of anesthesia. He was premedicated and anesthetized as before and patency of the airway was attained. After achieving sufficient jaw relaxation, a size 4 ILMA (ILMA; LMA-Fastrach™, Laryngeal Mask Company, Ltd., Henley on Thames, UK) (Fig. 3) passed with ease. An airtight seal was achieved by inflating the cuff with 30 mL air. The trachea was intubated with a size 7.5-mm internal diameter (ID) silicone-cuffed tracheal tube that was passed through the ILMA (Fig. 4). Correct placement of the tracheal tube was confirmed by auscultation of the chest. The ILMA was removed over the tube. The remainder of the anesthesia management was uneventful.

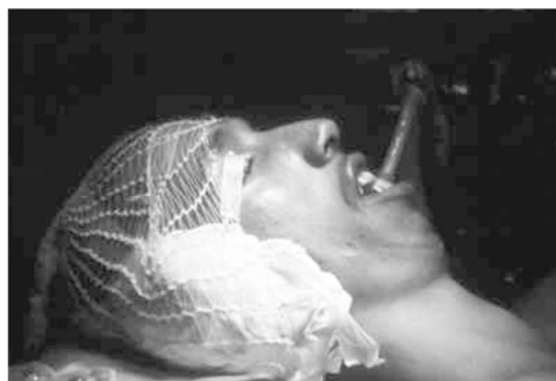

Fig. 4. The trachea was intubated with a size 7.5 mm (ID) silicone-cuffed tracheal tube that was passed through a size 4 ILMA.

DISCUSSION

In the present case, we report a patient with previous history of difficult tracheal intubation but not difficult ventilation. During one of the operative sessions the anesthetist could strenuously intubate the trachea and in the second attempt he was easily intubated using ILMA. Difficult intubation, however uncommon it may be, remains the greatest challenge during the administration of anesthesia (4). TCS is a first-arch congenital defect which often manifests with severe facial deformity (9). Cleft palate is present in up to 35% of patients and an additional 30-40% have congenital palatopharyngeal incompetence. Abnormalities of the ear are very common and vary from minor malformations to severe microtia and hearing loss. (1). The disease offers challenges to the anesthetists during surgical procedures. The challenges are difficulty in maintaining airway as well as difficult tracheal intubation during induction of general anesthesia (9). The alternatives routinely available to an anesthesiologist in a case of difficult intubation include awake fiberoptic intubation, blind nasal intubation, cricothyroidotomy, indirect laryngoscopy with the Bullard laryngoscope, Combitube (The Kendall Co Ltd, Basingstoke, England), blind oral intubation via the Augustine guide, and LMA. Cricothyroidotomy and combitube are emergency procedures for airway maintenance (4). The standard LMA can be used to enable ventilation of the lungs in patients in whom tracheal intubation has failed (4). It has been recognized as a useful adjunct during difficult intubation and appears in the American Society of anesthesiologists' difficult airway algorithm, both as an emergency airway and the conduit of choice for the fiberoptic bronchoscope (10). But it does not prevent aspiration and thus is not recommended for patients in whom the risk of aspiration is high. Blind intubation can be achieved through the standard LMA, but it admits a cuffed tube with a maximum internal diameter of 6.0 mm (4). To improve the success of blind intubation through a laryngeal mask, Brain *et al.* constructed the intubating laryngeal mask airway (ILMA), marketed under the name Fastrach. The new construction allows blind intubation with highly flexible endotracheal tubes up to 8 mm ID with cuff

(straight Woodbridge type), securing the airway around the intubation process and maintaining most of the characteristics of a standard laryngeal mask airway, including contraindications (11). Also its success rate improves from 30% to 97% compared with ILMA, which can be used as a conduit for a tracheal tube of up to 8.0-mm ID with a success rate of 82% to 99.3% (4).

There are several studies reporting that the ILMA is a remarkable device for failed or difficult intubation (12) with no serious complications (4, 13, 14). Joo *et al.* accounts ILMA as a useful device in the management of patients with difficult airways and as a valuable alternative to awake fiberoptic intubation (AFOI) when AFOI is contraindicated or in the patient with the unanticipated difficult airway (5). In one report, a laryngeal mask airway was used successfully to intubate the trachea in Treacher Collin's syndrome patient (2).

Therefore, the ILMA might be helpful for endotracheal intubation in patients with difficult or failed intubation. In addition, it requires minimal mouth opening and does not require head and neck manipulations on insertion and allows ventilation to continue during attempts of intubation. The ILMA could easily be inserted, and subsequent insertion of the tracheal tube through it was accomplished without any difficulty.

Acknowledgment

Author wishes to thank Farkhondeh Foadfar, M.S. of nursing anesthesiology.

REFERENCES

1. Muraika L, Heyman JS, Shevchenko Y. Fiberoptic tracheal intubation through a laryngeal mask airway in a child with Treacher Collins syndrome. *Anesth Analg.* 2003 Nov; 97(5):1298-1299.
2. Ebata T, Nishiki S, Masuda A, Amaha K. Anaesthesia for Treacher Collins syndrome using a laryngeal mask airway. *Can J Anaesth.* 1991 Nov; 38(8):1043-1045.
3. Bucx MJ, Grolman W, Kruisinga FH, Lindeboom JA, Van Kempen AA. The prolonged use of the laryngeal mask airway in a neonate with airway obstruction and Treacher Collins syndrome. *Paediatr Anaesth.* 2003 Jul; 13(6):530-533.

Difficult airway management in TCs

4. Saini S, Hooda S, Nandini S, Sekhri C. Difficult airway management in a maxillofacial and cervical abnormality with intubating laryngeal mask airway. *J Oral Maxillofac Surg*. 2004 Apr; 62(4):510-513.
5. Joo HS, Kapoor S, Rose DK, Naik VN. The intubating laryngeal mask airway after induction of general anesthesia versus awake fiberoptic intubation in patients with difficult airways. *Anesth Analg*. 2001 May; 92(5):1342-1346.
6. Khan ZH, Kashfi A, Ebrahimkhani E. A comparison of the upper lip bite test (a simple new technique) with modified Mallampati classification in predicting difficulty in endotracheal intubation: a prospective blinded study. *Anesth Analg*. 2003 Feb; 96(2):595-599.
7. Samsoun GL, Young JR. Difficult tracheal intubation: a retrospective study. *Anaesthesia*. 1987 May; 42(5):487-490.
8. Cormack RS, Lehane J. Difficult tracheal intubation in obstetrics. *Anaesthesia*. 1984 Nov; 39(11):1105-1111.
9. Tsaor GR, Liaw WJ, Wong CS, Yu FK, Hwang JJ, Chen SG, Ho ST. [Treacher-Collin's syndrome and translaryngeal guided intubation--case report]. *Acta Anaesthesiol Sin*. 1994 Sep; 32(3):223-228. Japanese.
10. Wakeling HG, Ody A, Ball A. Large goitre causing difficult intubation and failure to intubate using the intubating laryngeal mask airway: lessons for next time. *Br J Anaesth*. 1998 Dec; 81(6):979-981.
11. Langenstein H, Moller F. [Intubating laryngeal mask]. *Anaesthesiol Reanim*. 1998; 23(2):41-42. German.
12. Moller F, Andres AH, Langenstein H. Intubating laryngeal mask airway (ILMA) seems to be an ideal device for blind intubation in case of immobile spine. *Br J Anaesth*. 2000 Sep; 85(3):493-495.
13. Thienthong S, Horatanarung D, Wongswadiwat M, Boonmak P, Chinachoti T, Simajareuk S. An experience with intubating laryngeal mask airway for difficult airway management: report on 38 cases. *J Med Assoc Thai*. 2004 Oct; 87(10):1234-1238.
14. Langeron O, Semjen F, Bourgain JL, Marsac A, Cros AM. Comparison of the intubating laryngeal mask airway with the fiberoptic intubation in anticipated difficult airway management. *Anesthesiology*. 2001 Jun; 94(6):968-972.