

# DETECTION OF RARE CONGENITAL TRACHEAL ANOMALIES BY MULTIDETECTOR CT IN AN INFANT

Z. Miabi<sup>1</sup>, A. Alae<sup>2</sup>, M. Midia<sup>3</sup> and H. Hashemi<sup>4</sup>

1) Department of Radiology, School of Medicine, Tabriz University of Medical Sciences, Tabriz, Iran

2) Department of Radiology, School of Medicine, Mazandaran University of Medical Sciences, Mazandaran, Iran

3) Assistant professor of MC Master University Ontario Canada,

4) Department of Radiology, School of Medicine, Medical Sciences/University of Tehran, Tehran, Iran

**Abstract-** A 3 month- old boy was admitted with recurrent severe respiratory distress and refractory to therapeutic options. Patient underwent a helical multidetector CT examination. Axial, coronal and three- dimensional imaging, revealed tracheal bronchus, stenosis, diverticulum and bronchiectasis. In this situation, CT scanning, Perfectly 3D imaging is recommend for rule out congenital tracheobronchial tree anomalies. Therefore, with proper evaluation and therapeutic options we can prevent pulmonary complications and infantile mortality.

*Acta Medica Iranica*, 44(6): 429-431; 2006

© 2006 Tehran University of Medical Sciences. All rights reserved.

**Key words:** Congenital tracheal anomalies, multidetector CT, respiratory distress

## INTRODUCTION

Congenital tracheal anomalies are unusual causes of infantile respiratory distress that lead to recurrent pneumonia, chronic bronchitis and bronchiectasis (1). Tracheal bronchus, stenosis and diverticulum are branching anomalies, which are fairly uncommon (2). These tracheo- bronchial anomalies may be associated with other abnormalities (1). In this report, we present a rare case of three congenital tracheal anomalies in an infant.

## CASE REPORT

A 3 month- old male infant present with chronic recurrent respiratory difficulty, stridor, Cough, wheezing was admitted to our center Serious respiratory distress had begun from first days of life.

Received: 12 Aug. 2006, Revised: 3 Sep. 2006, Accepted: 19 Sep. 2006

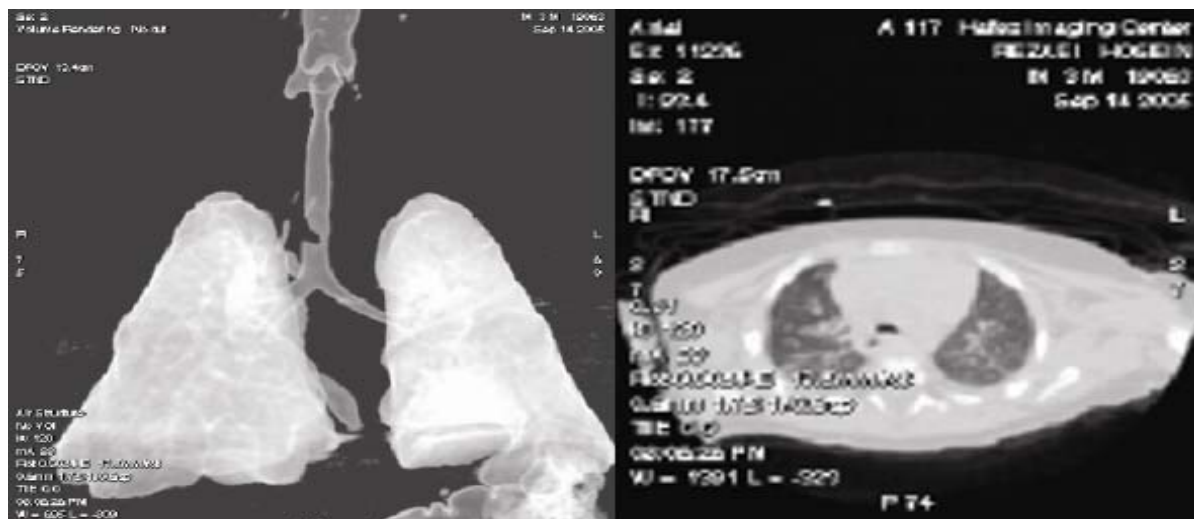
**\* Corresponding Author:**

Z. Miabi, Department of Radiology, School of Medicine, Tabriz University of Medical Sciences, Tabriz, Iran  
Tel: +98 21 88692344, Fax: +98 88962510  
E-mail: miabiz7@yahoo.com

Management was directed at controlling infection with antibiotics and improving drainage with physiotherapy. In spite of conservative treatment, the problem persisted and bronchiectasis occurred. Therefore, baby undergoes a helical multidetector CT examination (16 slices, GE, USA). Contiguous serial axial 1.25 mm images were obtained from thorax. Trans-axial and 3D reconstruction images shows origin of the tracheal bronchus from right posterolateral wall of the trachea above the carina, tracheal stenosis, left diverticulum and bronchiectatic changes (Fig. 1).

## DISCUSSION

Congenital tracheal anomalies are rare (1). Tracheal bronchus is an ectopic or supernumerary bronchus usually arising on the right lateral mid intrathoracic region of trachea and supplies either a segment of the right upper lobe or the whole right upper lobe. Tracheal bronchus (PIG bronchus) is more common in males with prevalence ranging



**Fig. 1.** Tracheal bronchus associated with tracheal stenosis and tracheal diverticulum demonstrated by reformatted coronal three-dimensional CT.

from 0.2- 5% (1). Tracheal bronchus is a normal finding in pig, cattle, camels and sheep (3). This anomaly also may be associated with tracheal, right main bronchus stenosis, infantile lobar emphysema, tracheoesophageal fistula, sling left pulmonary artery, congenital diaphragmatic hernia, trisomy 21 and upper rib anomalies (1, 4, 5).

Tracheal stenosis is a relatively rare disorder, and small series have been reported. Tracheal stenosis is an intrinsic narrowing of the caliber of the trachea and may be due to a continuous complete cartilage ring (no open posteriorly, because of a lack of the normal posterior membranous portion of the ring) or underdevelopment of a short segment of the airway (6).

Tracheal stenosis may occur with sling left pulmonary artery (SLPA) complex, trisomy 21 and craniosynostosis syndromes. Types of tracheal stenosis are focal or segmental (%50), diffuse generalized hypoplasia (%30) and Carrot or Funnel shape (20%) (7). Focal type is often associated with the tracheal bronchus may occur in subglottic, central or carinal regions. Tracheal diverticulum is a very rare anomaly usually arising from the right posterolateral surface of the trachea, and may give rise to symptoms only late in adult life when it become infected. This anomaly may also be associated with tracheal bronchus, esophageal atresia and tracheoesophageal fistula (8, 9).

Recurrent laryngeal nerve paralysis, tracheal deviation (difficult tracheal intubations and ventilation, and difficult lung isolation) is also reported (10-13). One third of patient with a TEF have tracheal bronchus and many of congenital tracheal stenosis have concurrent tracheal bronchus (2).

Many cases of tracheal bronchus are asymptomatic but associated with structural abnormalities such as malacia and stenosis may be found in these bronchi and concomitant tracheal stenosis induce poor drainage of mucosal secretions, that lead to recurrent infection, emphysema, atelectasis.

If these anomalies does not resolve, bronchiectasis occur. This tracheal bronchus is itself more commonly seen in the site of bronchogenic cysts, bronchial adenomas, leiomyoma, carcinoid and carcinoma (14, 15, 3).

Lodge of Foreign body in tracheal bronchus may occur, which mimic bronchogenic tumor (16). Our patient showed tracheal bronchus, the tracheal stenosis and tracheal diverticulum's with bronchiectasis that caused respiratory impairment. Plain films, barium swallow and dynamic fluoroscopic study may be considered, therefore, in cases of recurrent, relapsing respiratory diseases, cross sectional imaging and perfectly 3D CT is indicated.

## REFERENCES

1. Doolittle AM, Mair EA. Tracheal bronchus: classification, endoscopic analysis, and airway management. *Otolaryngol Head Neck Surg.* 2002 Mar; 126(3):240-243.
2. McLaughlin FJ, Strieder DJ, Harris GB, Vawter GP, Eraklis AJ. Tracheal bronchus: association with respiratory morbidity in childhood. *J Pediatr.* 1985 May; 106(5):751-755.
3. Metin M, Sayar A, Turna A, Gurses A. Tracheal bronchus obliterated with bronchial carcinoid. *Eur J Cardiothorac Surg.* 2002 Jan; 21(1): 155.
4. Nose K, Kamata S, Sawai T, Tazuke Y, Usui N, Kawahara H, Okada A. Airway anomalies in patients with congenital diaphragmatic hernia. *J Pediatr Surg.* 2000 Nov; 35(11):1562-1565.
5. Elmaci TT, Guler N, Aydogan U, Onursal E. Infantile lobar emphysema and tracheal bronchus in a patient with congenital heart disease. *J Pediatr Surg.* 2001 Oct; 36(10):1596-1598.
6. Manson D, Babyn P, Filler R, Holowka S. Three-dimensional imaging of the pediatric trachea in congenital tracheal stenosis. *Pediatr Radiol.* 1994; 24(3):175-179.
7. Cotter CS, Jones DT, Nuss RC, Jonas R. Management of distal tracheal stenosis. *Arch Otolaryngol Head Neck Surg.* 1999 Mar; 125(3):325-328.
8. Early EK, Bothwell MR. Congenital tracheal diverticulum. *Otolaryngol Head Neck Surg.* 2002 Jul; 127(1):119-121.
9. Bhatnagar V, Lal R, Agarwala S, Mitra DK. Endoscopic treatment of tracheal diverticulum after primary repair of esophageal atresia and tracheoesophageal fistula. *J Pediatr Surg.* 1998 Aug; 33(8):1323-1324.
10. Ching SL, Chow MY, Ng HN. Difficult lung isolation in a patient with an undiagnosed tracheal diverticulum. *J Cardiothorac Vasc Anesth.* 2003 Jun; 17(3):355-356.
11. Caversaccio MD, Becker M, Zbaren P. Tracheal diverticulum presenting with recurrent laryngeal nerve paralysis. *Ann Otol Rhinol Laryngol.* 1998 Apr; 107(4):362-364.
12. Davies R. Difficult tracheal intubation secondary to a tracheal diverticulum and a 90 degree deviation in the trachea. *Anaesthesia.* 2000 Sep; 55(9):923-925.
13. Dinner M, Ward R, Yun E. Ventilation difficulty secondary to a tracheal diverticulum. *Anesthesiology.* 1992 Sep; 77(3):586-587.
14. Tamura M, Murata T, Kurumaya H, Ohta Y. Leiomyoma of an accessory tracheal bronchus. *Ann Thorac Surg.* 2004 Dec; 78(6):2163-2165.
15. Patrino V, Kourea H, Dougenis D. Bronchial carcinoid of an accessory tracheal bronchus. *Ann Thorac Surg.* 2001 Mar; 71(3):1034-1035.
16. Qureshi RA, Soorae AS. Foreign body in tracheal bronchus simulating bronchogenic cancer. *Eur J Cardiothorac Surg.* 2001 Sep; 20(3):639-641.