

# PERIBULBAR COMPLEX CHORISTOMA IN ASSOCIATION WITH IPSILATERAL NASAL HYPOPLASIA AND NASOLACRIMAL DUCT OBSTRUCTION

S. Z. Tabatabaie, M. T. Rajabi\*, F. Asadi-Amoli, A. Sadeghi-Tari and A. Kasai

Eye Research Center, Farabi Eye Hospital, Medical Sciences/University of Tehran, Tehran, Iran

**Abstract-** Developmental midline perinasal masses in children are rare lesions, specifically in association with choristomas. We encountered a 3-year-old boy with epiphora, a striking mass on the nasal bridge and ipsilateral nasal hypoplasia. CT scan imaging showed multiple calcified areas within the tumor in addition to linear defect in frontal bone, hypoplastic left ethmoidal sinus and left nasal cavity, and absence of left nasal concha. The patient had no history of seizure, no neurologic deficit, and ocular developmental examinations were normal. After performing excisional biopsy of the tumor, histopathologic analysis revealed complex choristoma composed of cartilage and bone. The most appropriate name for this malformation, which to our knowledge has not been described in the literature, seems to be, nasal hypoplasia with complex choristoma and nasolacrimal duct obstruction.

*Acta Medica Iranica*, 45(1): 79-82; 2007

© 2007 Tehran University of Medical Sciences. All rights reserved.

**Key words:** Complex choristoma, nasal hypoplasia, nasolacrimal duct obstruction.

## INTRODUCTION

Developmental midline perinasal masses in children are rare lesions. The incidence has been reported to be 1 in every 20,000–40,000 live births (1-3). The most common masses include nasal dermal sinus cysts, nasal gliomas and nasal encephaloceles. These congenital nasal masses are believed to result from a failure of embryological separation of neuroectodermal and ectodermal tissues during the development of the nose and frontobasis (3, 4). These lesions are embryologically distinct, but all have an actual or potential intracranial extension/connection. The differential diagnosis includes abscesses, hemangiomas, fibromas, lipomas, granulomas and mucoceles (5, 6).

Choristomas are congenital lesions representing

Received: 26 Jun. 2005, Revised: 6 Nov. 2005, Accepted: 30 Nov. 2006

**\* Corresponding Author:**

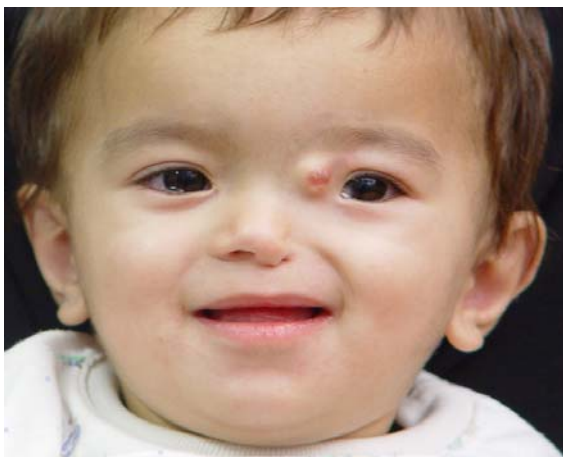M. T. Rajabi, Eye Research Center, Farabi Eye Hospital, School of Medicine, Medical Sciences/University of Tehran, Tehran, Iran  
Tel: +98 21 55410009  
Fax: +98 21 55410005  
E-mail: mt\_rajabi@yahoo.com

normal tissues in an abnormal location; they are the most common epibulbar and orbital tumors in children (7). The association of choristomas with various craniofacial and systemic defects is well documented in the literature. Despite the complex embryological development of the nose and surrounding structures, significant developmental nasal anomalies are rare specifically in association with Choristomas.

Here we present the case of a child with nasal hypoplasia combined with complex choristoma and nasolacrimal duct obstruction.

## CASE REPORT

A 3-year-old boy was referred to the Oculoplastic and Orbital Service, Farabi Eye Hospital, Tehran, Iran, in September 2004 with epiphora and a solid mass on the left nasal bridge combined with nasal hypoplasia. He had this lesion from birth but increasing the size of that instructed his parents for further evaluations.



**Fig. 1.** A firm, non-tender mass 1×1 cm in diameter in left medial canthus. Hypoplastic left nasal bridge and nostril can be seen easily.

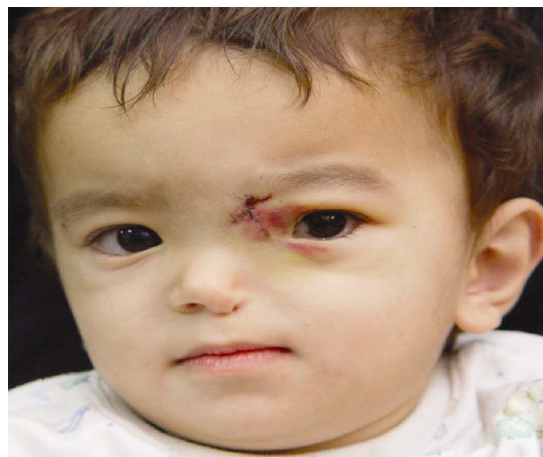He had been the product of full-term, normal delivery without prenatal or intra-partum complications.

On physical examination, an elevated, firm mass 1×1 cm in diameter was visible just medial and superior to the medial canthus on the left nasal bone. By palpation, it seemed to have a stalk extended and fixed on bone (Fig. 1, 2). Ipsilateral to this lesion, nasal bridge was hypoplastic. Inadequate growth of left nostril and cartilaginous ala was seen. On examination under anesthesia nasolacrimal duct was obstructed that probing was done for solving this problem. Results of ocular examination were normal. Other globe examinations (anterior and posterior segments) were unremarkable. The patient had no history of seizure and no neurologic deficit was found in examination. Developmental examinations were within normal range.

He had no familial history, and his mother did not take any suspected medication (such as warfarin, carbimazole, valproic acid, ethanol, and acitretin that cause nasal anomalies) or trauma within pregnancy.

Computed tomography (CT) scan imaging revealed a round lesion with multiple calcified areas within the tumor. In addition to this mass, a linear defect in frontal bone, hypoplastic left ethmoidal sinus and nasal cavity, and absence of left nasal concha were seen on CT scan (Fig. 3).

The patient underwent excisional biopsy. After undermining of the skin, the lesion was revealed

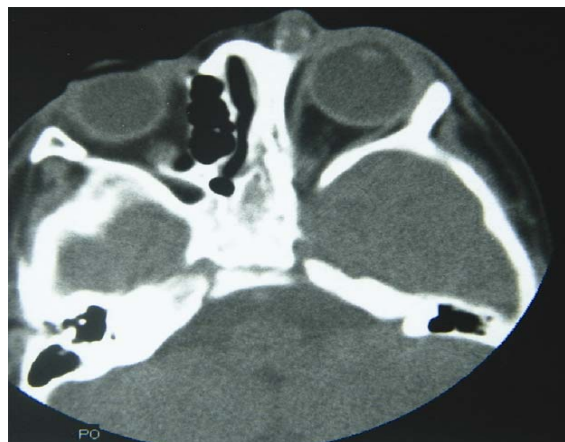


**Fig. 2.** The same boy after excision of the tumor.

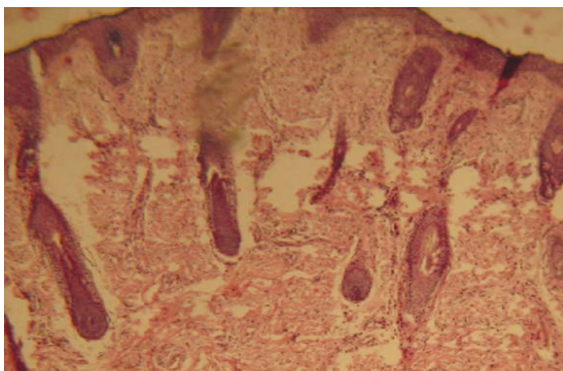
as a cystic lesion. The dense, subcutaneous stalk of the tumor that had extended to the frontoethmoidal suture was difficult to excise. Finally adhesion between the suture and the cyst was cut and a milky material was released from cyst.

Histologic examination of the excised mass revealed multiple cartilages and bony tissue accompanying with keratin and admixture of ectodermal element that was compatible with complex choristoma (Fig. 4, 5). Six months after follow-up the patient was free of tumor and epiphora.

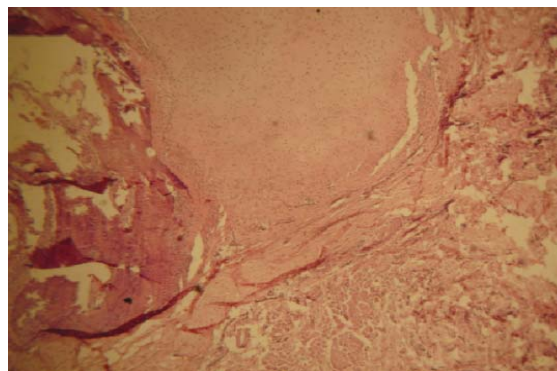
We obtained informed consent from parents to publish details of their son illness and his photographs.



**Fig. 3.** Axial computed tomography showed multiple calcified areas within the tumor. Bony stalk of the lesion extending to fronto-ethmoidal suture can be seen. This view also shows hypoplasia of left nasal cavity and ethmoidal sinus.



**Fig. 4.** Superficial part of the lesion, covered by epidermis, the stroma contains hair follicles, and sweat and sebaceous glands. H&E stain  $\times 50$ .



**Fig. 5.** Deeper part of the lesion that shows fibrovascular stroma contains islands of cartilages and bone tissue. H&E stain  $\times 50$ .

## DISCUSSION

Congenital midline nasofrontal masses are the result of faulty regression of the embryologic dural diverticulum from the prenasal space and occur in one of every 20,000–40,000 births. The type of mass is determined by the nature of the faulty regression. The mass may be intranasal, extranasal, or a combination of the two. Intranasal masses are due to extension of dura mater through the foramen cecum into the prenasal space and nasal cavity. Glabellar masses are due to extension of the diverticulum through the foramen cecum and fonticulus frontalis.

Congenital midline masses are often obvious at birth but can manifest at any age (8). Midface disfigurement, nasal destruction, meningitis, and airway obstruction may occur. Imaging helps to characterize these lesions so that the surgical approach can be planned as extracranial, intracranial, or both. Findings that suggest intracranial extension include widening of the foramen cecum and a bifid or dystrophic crista galli (6). Nasofrontal masses most commonly manifest as dermoid or epidermoid cysts, nasal gliomas (nasal cerebral heterotopias), or encephaloceles (9). Choristomas are the most common type of nasal, epibulbar and orbital tumors in the pediatric age (7).

Choristomas represent congenital overgrowth of normal tissues in an abnormal location. The predominant locations of ocular choristomas include the epibulbar region, the ocular adnexa, and the choroid. They can be divided into four main histopathologic groups: dermoid, lipodermoid, single-tissue choristoma, and complex choristoma.

Single tissue choristomas consist of dermis-like tissue or ectopic tissues of mesectodermal origin (lacrimal and other glands, fat, nerve, brain, cartilage, bone, and teeth). Complex or composite choristomas, contain tissues of different origins.

The association of choristomas with various craniofacial and systemic defects is well documented in the literature. Anderson *et al.* reported degenerative apparent anophthalmia with complex choristoma in the orbit (10). It has been associated with ipsilateral facial nevus of Jadassohn, and Goldenhar syndrome (11, 12). Amir and Dunham reported bilateral choanal atresia associated with nasal choristoma and sinus (13). Choristomas have also been associated with intracranial anomalies (14, 15). Nasal choristoma may be associated with bony cranial defects (as in this case) and intracranial abnormalities, as well as cerebrospinal fluid (CSF) leakage and the potential for fatal meningitis if not handled properly. Preoperative manipulation should be avoided. If intracranial attachments are identified radiologically, or suspected clinically, neurosurgical consultation should be obtained (2).

The finding of a choristoma may signal a simultaneous occurrence of other lesions of an analogous origin in other localities than that of the bulbus or the orbit, which should lead the ophthalmologist to a complex examination of the patient and an interdisciplinary cooperation with the neurologist, oto-rhino-laryngologist, dermatologist, and others. A variety of congenital midface anomalies occur in children. High-resolution CT and magnetic resonance (MR) imaging have proved helpful in determining the nature and extent of

dysplasia, thereby facilitating treatment planning.

A classification system has been developed that groups these anomalies into four categories based on embryogenesis and anatomic location. These categories comprise anomalies that are related to the nasal cavity, nasofrontal region, nasolacrimal apparatus, and craniofacial syndromes. CT is the imaging modality of choice in children with possible choanal atresia, pyriform aperture stenosis, or anomalies of the nasolacrimal duct (*e.g.*, nasolacrimal duct stenosis, dacryocystoceles). MR imaging is the modality of choice in patients with congenital midface masses (*e.g.*, dermoid and epidermoid cysts, nasal gliomas, encephaloceles) and craniofacial syndromes (*e.g.*, Apert syndrome, Crouzon syndrome, Treacher Collins syndrome). In many cases, however, both CT and MR imaging are required to adequately evaluate midface anomalies.

Familiarity with the characteristic imaging features of these anomalies along with knowledge of midface embryogenesis and normal developmental anatomy is essential to prevent misinterpretation of anatomic variations that may simulate disease (5). Here we describe an atypical case which to the best of our knowledge had not been reported previously. The most appropriate name for this malformation seems to be “nasal hypoplasia with complex choristoma and nasolacrimal duct obstruction”. Such cases persist on importance of cooperation of ophthalmologist with other subspecialties.

## REFERENCES

1. Pratt LW. Midline cysts of the nasal dorsum: embryologic origin and treatment. *Laryngoscope*. 1965 Jun; 75:968-980.
2. Hughes GB, Sharpino G, Hunt W, Tucker HM. Management of the congenital midline nasal mass: a review. *Head Neck Surg*. 1980 Jan-Feb; 2(3):222-233.
3. Paller AS, Pensler JM, Tomita T. Nasal midline masses in infants and children. Dermoids, encephaloceles, and gliomas. *Arch Dermatol*. 1991 Mar; 127(3):362-366.
4. Harley EH. Pediatric congenital nasal masses. *Ear Nose Throat J*. 1991 Jan; 70(1):28-32.
5. Morgan DW, Evans JN. Developmental nasal anomalies. *J Laryngol Otol*. 1990 May; 104(5):394-403.
6. Barkovich AJ, Vandermarck P, Edwards MS, Cogen PH. Congenital nasal masses: CT and MR imaging features in 16 cases. *AJNR Am J Neuroradiol*. 1991 Jan-Feb; 12(1):105-116.
7. Mansour AM, Barber JC, Reinecke RD, Wang FM. Ocular choristomas. *Surv Ophthalmol*. 1989 Mar-Apr; 33(5):339-358.
8. Kennard CD, Rasmussen JE. Congenital midline nasal masses: diagnosis and management. *J Dermatol Surg Oncol*. 1990 Nov; 16(11):1025-1036.
9. Fitzpatrick E, Miller RH. Congenital midline nasal masses: dermoids, gliomas, and encephaloceles. *J La State Med Soc*. 1996 Mar; 148(3):93-96.
10. Andersen SR, Wangspa S, Limpaphayom P. Degenerative apparent anophthalmia with complex choristoma of orbit. A clinicopathological case report. *Ophthalmologica*. 1979; 178(6):321-326.
11. Wilkes SR, Campbell RJ, Waller RR. Ocular malformation in association with ipsilateral facial nevus of Jadassohn. *Am J Ophthalmol*. 1981 Sep; 92(3):344-352.
12. Shields JA, Shields CL, Eagle RC Jr, Arevalo JF, DePotter P. Ocular manifestations of the organoid nevus syndrome. *Ophthalmology*. 1997 Mar; 104(3):549-557.
13. Amir R, Dunham ME. Bilateral choanal atresia associated with nasal dermoid cyst and sinus: a case report and review of the literature. *Int J Pediatr Otorhinolaryngol*. 2001 Apr 6; 58(1):81-85.
14. Cheng ML, Chang SD, Pang D, Adler JR. Intracranial nasal dermoid sinus cyst associated with colloid cyst of the third ventricle. Case report and new concepts. *Pediatr Neurosurg*. 1999 Oct; 31(4):201-206.
15. Wardinsky TD, Pagon RA, Kropp RJ, Hayden PW, Clarren SK. Nasal dermoid sinus cysts: association with intracranial extension and multiple malformations. *Cleft Palate Craniofac J*. 1991 Jan; 28(1):87-95.