

# PHEOCHROMOCYTOMA AND RENAL AGENESIS

A. Nickavar<sup>1\*</sup> and M. Razzaghy-Azar<sup>2</sup>

1) Department of Nephrology, School of Medicine, Iran University of Medical Sciences, Tehran, Iran

2) Department of Endocrinology, School of Medicine, Iran University of Medical Sciences, Tehran, Iran

**Abstract-** Pheochromocytomas are catecholamine producing tumor arising from chromaffin cells of adrenal medulla and extra adrenal tissues. Renal anomalies have been reported rarely in this disease. Here we report a rare case of pheochromocytoma associated with renal agenesis. Patient was a boy presented with headache and hypertension. In radiologic examinations, an adrenal mass was detected in the left side, with no renal tissue on that side. It was reported an adrenal pheochromocytoma in histopathology. Renal agenesis confirmed during surgery. All of the patients symptoms alleviated after the resection of tumor. Considering association of renal abnormalities with pheochromocytoma, it is recommended to perform genetic analysis and kidney evaluation in cases with MEN type 2 or each of its components.

© 2008 Tehran University of Medical Sciences. All rights reserved.

*Acta Medica Iranica*, 46(1): 81-83; 2008

**Key words:** Pheochromocytoma, renal agenesis, hypertension

## INTRODUCTION

Unilateral renal agenesis is usually asymptomatic and detected incidentally. It is often associated with anomalies of contiguous (vertebrae, intestine, ...) or non contiguous (limbs, heart, ...) organs (1).

Pheochromocytomas are the most common endocrine tumors in childhood and the leading cause of pediatric hypertension in 1-2% (2). It may be associated with involvement of other organs in specific syndromes, especially MEN type 2. Renal anomalies have been reported rarely in this disease. This is a report of a rare case of pheochromocytoma associated with renal agenesis.

## CASE REPORT

A 14 year old boy was admitted for headache and occasional night sweating. He had no complaint of nausea, vomiting and visual problems. Family history was negative for any significant disease. Physical examination was normal except for hypertension (BP= 160/90).

Laboratory examinations consisted of complete blood count (CBC), serum and urine biochemistry, serum renin and aldosterone level were all normal (Table 1). In abdominal ultrasound and DMSA radioisotope scan, right kidney was larger than normal and left kidney absent. Voiding cystourethrography was normal. Abdominal MRI and MRA of renal arteries showed compensatory hypertrophy of right kidney with multiple main renal arteries and no evidence of left kidney. An adrenal mass (possibly pheochromocytoma) detected in the left side. Therefore, urine VMA and NMN checked, which were both higher than normal (Table 1).

MIBG scan showed increased radiotracer uptake in both adrenals with a photopenic area in the enlarged left adrenal gland. The patient screened for

Received: 8 Nov. 2005, Revised: 28 Feb. 2006, Accepted: 20 May 2006

**\* Corresponding Author:**

Azar Nikavar, Department of Nephrology, Ali Asghar Children Hospital, School of Medicine, Iran University of Medical Sciences, Tehran, Iran

Tel: +98 21 22226468,

Fax: +98 21 22200063

E-mail: anikavar@yahoo.com

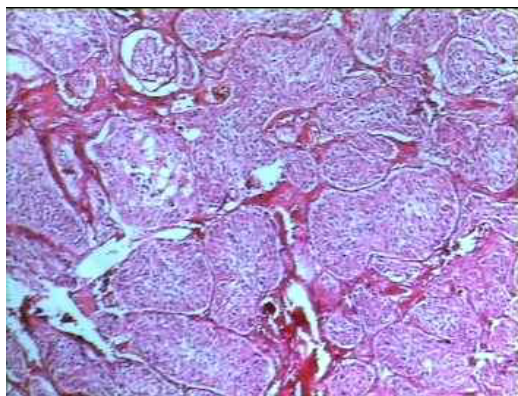
**Table 1.** Laboratory exams

Sodium	146 meq/l
Potassium	4.4 meq/l
Calcium	9.1 mg/dl
Phosph	5.4 mg/dl
Alk Phos	840 U/L
BUN	19 mg/dl
Crea	0.9 mg/dl
SGOT	40 U/L
SGPT	18 U/L
Renin	3 ng/ml/h (normal= ≤4/2 ng/ml/h)
Aldosterone	15 (normal= 2-22 ng/dl)
T3	150 (normal= 80-210 ng/dl)
T4	10 (normal= 4/2-13 microg/dl)
TSH	4 (normal=0/7-6/4 nmol/L)
PTH	30 (normal=9-65pg/ml)
VMA	18 (High)
NMN	4053 (High)

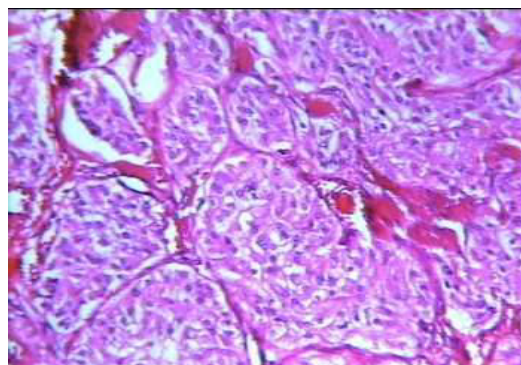
Abbreviations: VMA= Vanillylmandelic acid, NMN= Normetanephrin, DMSA= Dimercapto succinic acid, MRA= magnetic resonance angiography, MIBG= Monoio-dobenzylguanidine

MEN type 2 (parathyroid tumor, medullary carcinoma of the thyroid, and pheochromocytoma) (Table 1) and Von hippel lindau disease which were all negative. He explored surgically for final diagnosis. No renal tissue detected in the left side, except a mass on that side, which was further reported to be an adrenal pheochromocytoma in histopathology (Fig. 1-3).

After tumoral resection, blood pressure became normal without any antihypertensive drug. During follow up, he had no recurrence of previous symptoms or any other disorders.



**Fig. 1.**



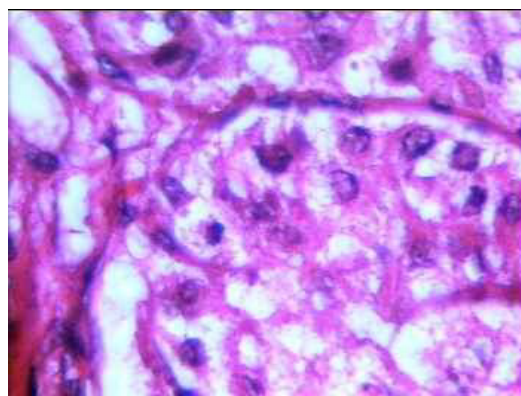
**Fig. 2.**

## DISCUSSION

Pheochromocytomas are adrenal and extra adrenal tumors which may present in the form of bilateral, multifocal, sporadic and familial as a component of MEN type 2, neurofibromatosis and Von hippel lindau disease (3, 4).

There are a few reports of renal abnormalities in patients with pheochromocytoma. It is a part of a rare autosomal dominant disease, von Hippel Lindau, which presents as renal cysts and carcinoma, retinal angioma, central nervous system hemangioblastoma and pancreatic involvement (5). Renal involvement is the most prevalent cause of its mortality (6).

Pheochromocytoma has been reported in some cases of bilateral polycystic kidney disease (7-9), one complicated by spontaneous rupture of tumor (8) and hemorrhage in the renal bed (9), and also in a patient with cystic dysplastic kidney on continuous dialysis. To our literature review, this is the first report of pheochromocytoma associated with renal agenesis.



**Fig. 3.**

Genetically, the significance of RET proto-oncogen gene (10) and its encoding protein related to tyrosin kinase family (11) has been documented in the induction of metanephric blastema and ureteric bud during kidney morphogenesis (10). Mutation of this gene is known to be responsible for developing MEN type 2A (2), renal agenesis or severe dysplasia (10). Lore et al have been suggested non invasive imaging techniques such as ultrasonography for screening renal abnormalities in patients with RET mutations (10).

According to common involvement of this gene in pathogenesis of these tumors and kidney morphogenesis, and the association of renal abnormalities with pheochromocytoma, it is recommended to perform genetic analysis and kidney evaluation in cases with MEN type 2 or each of its components.

## REFERENCES

1. Limwongse C. Syndromes and malformations of the urinary tract. In: Avner ED, Harmon WE. Pediatric nephrology, 5 th edi. Philadelphia: Lippincott, 2004; p. 93-125.
2. Pacak K, Eisenhofer G. Disorders of the adrenal medulla. In: Lifshitz fima. Pediatric endocrinology, Marcel Dekker, 2003; p. 194-9.
3. Ross JH. Pheochromocytoma. Special considerations in children. Urol clin North Am 2000; 27 (3): 393-402.
4. Chernauek SD Pheochromocytoma and the multiple endocrine neoplasia syndromes. In: Sperling. Pediatric endocrinology. Philadelphia: Saunders. 2002; P. 439-450.
5. Sessa A, Bettini G, Meroni M. Multi focal bilateral cell cancer and bilateral agenesis in a patient with de novo von Hippel Lindau disease: identification of a new germ line mutation. J Nephrol. 2005 Mar-Apr; 18 (2): 209-212.
6. Chau reah D, duric C, Chretien Y. Renal involvement in Von Hippel Lindau disease. Kidney Int. 1996 Sep; 50 (3): 944-951.
7. Mansi L, Rambaldi PF, Marino G, et al. Pheochromocytoma diagnosed with I- 123 MIBG scintigraphy in a patient with concomitant bilateral polycystic kidneys. Clin Nucl Med. 1997 Apr; 22(4): 268-270.
8. Quinonero DA, Garcia HJ, Alonso Dorrego JM, et al. Spontaneous rupture of pheochromocytoma in a patient with polycystic kidneys. Arch Esp Urol. 1997 Dec; 50 (10): 1117-1119.
9. Delavierre P, Vayre P. Association of a polycystic kidney and an adrenal adenoma complicated by hemorrhage of the renal bed. Sem Hop. 1976 May; 23: 52 (20): 122304.
10. Lore F, Talidis F, Dicairano G, Renieri A. Multiple endocrine neoplasia type 2 syndromes may be associated with renal malformations. J Intern Med. 2001 Jul; 250 (1): 37-42.
11. Ch appuis FS, Pasini A, De vita G et al. Dual effect on the RET receptor of MEN 2 mutations affecting specific extra cytoplasmic cysteins. Oncogen. 1998 Dec; 17(22): 2851-2861.