

# CONGENITAL ANTERIOR TIBIOFEMURAL SUBLUXATION

A. Shahla

Department of Orthopaedics, Imam Khomeini Hospital, School of Medicine, Urmia University of Medical Sciences, Urmia, Iran

**Abstract-** Congenital anterior tibiofemoral subluxation is an extremely rare disorder. All reported cases accompanied by other abnormalities and syndromes. A 16-year-old high school girl referred to us with bilateral anterior tibiofemoral subluxation as the knees were extended and reduced at more than 30 degrees flexion. Deformities were due to tightness of the iliotibial band and biceps femoris muscles and corrected by surgical release. Associated disorders included bilateral anterior shoulders dislocation, short metacarpals and metatarsals, and right calcaneovalgus deformity.

© 2008 Tehran University of Medical Sciences. All rights reserved.

*Acta Medica Iranica* 2008; 46(3): 283-286.

**Key words:** Anterior subluxation, tibiofemoral, congenital

## INTRODUCTION

Congenital tibiofemoral subluxation is an extremely rare disorder and different from congenital dislocation of the knee (1). Curtis and Fisher reported 5 patients with bilateral congenital tibiofemoral subluxation in 1970. All had features of skeletal dysplasia, spinal defects, and positive family histories. Two had Larsen's syndrome, one had otopalatodigital syndrome, and one had 45, XO karyotype. Anterior tibial subluxation was occurred with active knee extension and reduced spontaneously at about 30 degrees flexion. With extension, the thickened iliotibial band and hypertrophied biceps femoris muscle were shifted anteriorly and acted as extensors. Surgical release of iliotibial band, intermuscular septum, and biceps femoris removed the deforming forces and eliminated unusual subluxation (2). Ferris and Jackson reported findings in 6 knees in 4 cases. The associated conditions were Larsen's syndrome, Catel-Manzke syndrome, and congenital short tibia (3). Here we report a case of congenital anterior tibiofemoral subluxation.

## CASE REPORT

A 16-year-old high school girl 145 cm height, 46 kg weight, unrelated parents, non affected family, 9 healthy brothers and sisters, referred to us with complain of slow, disabling gait. At swing phase both knees were in semi flexion and reduced, at stance phase with extension of the knees, tibial bones were subluxated anteriorly. In supine position both knees were in 45 degrees flexion. Passive extension of the knees required forceful anterior tibial displacement and occurred with audible clicks. Evident genu valgum were appeared at extension of the knees Q angle 17 degrees in right and 15 degrees in left.

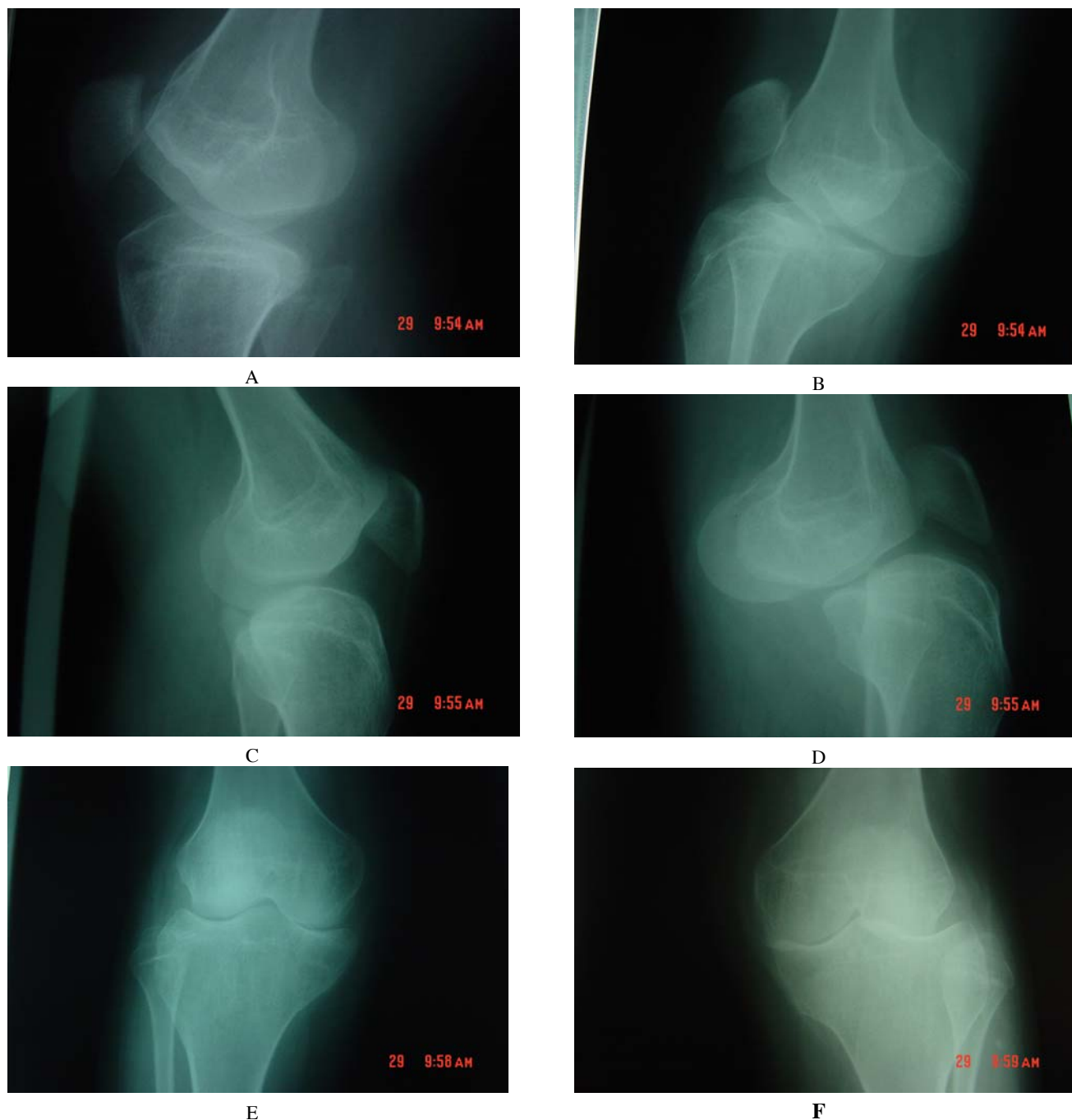
Associated abnormalities were limited abduction and external rotation of shoulders without daily activity difficulty and right foot calcaneovalgus deformity. She was admitted in Orthopaedic department. Chromosome study for probable abnormalities, urine investigation for mucopolysaccharide excretion, MRI of knees, ENT, ophthalmologist, and internist consultation were performed with all normal reports. Skeletal survey revealed Flattening of anterior femoral Condyles, posterior sloping of tibial plateaus, and proximal extension of fibular bones. Knee joints were reduced in 30 degrees flexion and anteriorly subluxated in extension (Fig. 1). Bilateral glenoid dysplasia and anterior shoulders dislocation (Fig. 2), short 4-5<sup>th</sup>

Received: 26 May 2006, Revised: 13 Aug. 2006, Accepted: 22 Oct. 2006

**\* Corresponding Author:**

Ahmad Shahla, Department of Orthopaedic Surgery, School of Medicine, Urmia University of Medical Sciences, Urmia, Iran  
Tel: +98 441 346 9931  
Fax: +98 441 346 9935  
E-mail: a\_shahla@umsu.ac.ir

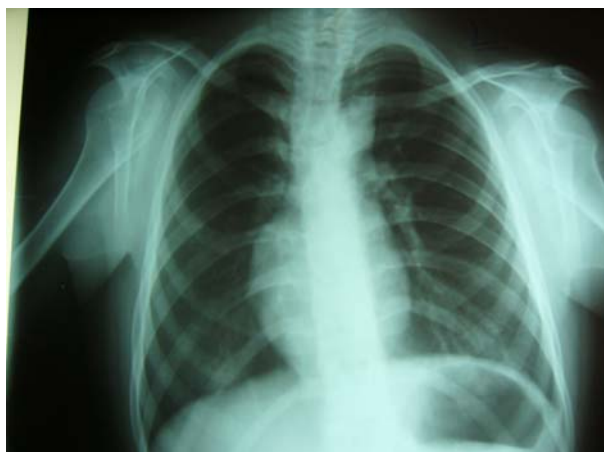## Congenital anterior tibiofemoral subluxation



**Fig. 1.** A, Lat right knee in flexion; B, Lat right knee in extension; C, Lat left knee in flexion.; D, Lat left knee in extension.; E, AP right knee; F, AP left knee.

metacarpals in right hand, short 3-4<sup>th</sup> metacarpals in left hand, and short 4-5<sup>th</sup> metatarsals in both feet. Larsen's syndrome was suggested although patient had not typical accessory calcaneus (4). Patient accepted surgical correction. Arthroscopy and arthrotomy with probing revealed intact ACL and PCL in both knees, tight in extension and partially lax in flexion. The iliotibial tract, biceps femoris

muscle and tendon, and intermuscular septum were large and hypertrophied. Upon full extension of the knees iliotibial band and biceps femoris tendons moved anteriorly and their direction of pull caused subluxation. Knee deformities were corrected with Curtis and Fisher recommended procedure including iliotibial band and biceps femoris tendon release (2).



**Fig. 2.** Shoulders dislocation.

## DISCUSSION

Congenital anterior tibiofemoral subluxation is very rare. All cases have heritable syndromes and skeletal dysplasia. Presenting complaint is a snapping knee (1). The most characteristic clinical finding is the anterior displacement of the tibia which occurs at active knee extension and reduction of displacement which occurs beyond 30 degrees flexion. Subluxation and reduction are visible and audible. Valgus deformity is exhibited. Pathology is due to hypertrophy of the iliotibial band, intermuscular septum, and biceps femoris muscle. With extension, iliotibial band and biceps femoris tendon move anterior to the joint axis and their direction of pull causes anterior subluxation (2). Ligaments status is different in two references. In Curtis and Fisher cases laxity of the cruciate and collateral ligaments is less than expected but always presents in mild to moderate degrees (2). Ferris and Jackson describe complete absence or attenuated incompetence anterior cruciate ligament and suggest that ACL deficiency is an important component of the dysplasia (3).

In patients seen within the first few months of life immobilization in plaster at 90 degrees flexion for about 8 weeks has no effect (3). Surgical sectioning of iliotibial band and distal portion of intermuscular septum with proximal transfer of biceps femoris insertion to the vastus lateralis corrects subluxation. Operative procedure was recommended by Curtis and Fisher (2) and modified

by Macintosh and Darby (5). Early surgery is recommended to prevent altered morphology of tibial and femoral epiphysis. Curtis pointed out normal and asymptomatic gait at 7 years follow up (2).

Anterior tibio femoral subluxation is different from congenital dislocation of knee. Congenital dislocation of the knee is apparent at birth. The knee is hyperextended with limited flexion. Deformity may be isolated or combined with other congenital abnormalities (6). Severity classification includes 3 grades: recurvatum, subluxation, and dislocation. In recurvatum knee is hyperextended more than 15 degrees, may completely flexed, and radiography is normal. Subluxation is presented if the knee is hyperextended 25-45 degrees with restriction of flexion, diagnosis is made radiographically. Dislocation is presented with unstable knee, variable extension/flexion, flexed hip, foot at mandible, and radiography of dislocation (7). Main pathology is quadriceps fibrosis and contracture accompanied by anterior displacement of hamstrings, absence of supra patellar pouch, underdeveloped or absent patella, hypo plastic or absent cruciates. Treatment includes manipulation and surgery before walking (8).

## REFERENCES

1. Herring JA. Tachdjian's pediatric orthopaedics. 3<sup>rd</sup> edition. Philadelphia: W. B. Saunders; 2002. P. 825-827.
2. Curtis BH, Fisher RL. Heritable congenital tibiofemoral subluxation. Clinical features and surgical treatment. *J Bone Joint Surg Am.* 1970 Sep; 52(6):1104-1114.
3. Ferris BD, Jackson AM. Congenital snapping knee. Habitual anterior subluxation of the tibia in extension. *J Bone Joint Surg Br.* 1990 May; 72(3):453-456.
4. Larsen LJ, Schottstaedt ER, Bost FC. Multiple congenital dislocations associated with characteristic facial abnormality. *J Pediatr.* 1950 Oct; 37(4):574-581.
5. Macintosh DL, Darby TA. Lateral substitution reconstruction. *J Bone Joint Surg* 1976; 58 B:142.
6. Johnson E, Audell R, Oppenheim WL. Congenital dislocation of the knee. *J Pediatr Orthop.* 1987 Mar-Apr; 7(2):194-200.

### **Congenital anterior tibiofemoral subluxation**

7. Laurence M. Genu recurvatum congenitum. J Bone Joint Surg Br. 1967 Feb; 49(1):121-134.
8. Ferris B, Aichroth P. The treatment of congenital knee dislocation. A review of nineteen knees. Clin Orthop Relat Res. 1987 Mar; (216):135-140.