

# ENDOLARYNGEAL NEUROFIBROMA

F. Izadi<sup>1</sup>, M. D. Arbabi<sup>1</sup>, M. Ahmadzad-Asl <sup>\*2</sup> and A. Doroudinia<sup>1</sup>

1) Department of ENT-Head and Neck Surgery, ENT-Head and Neck Surgery Research Center, Hazrat-E-Rasoul Hospital, Iran University of Medical Sciences, Tehran, Iran

2) Department of Clinical Researches, Nikan Health Researchers Institute, Tehran, Iran

---

**Abstract-** Neurofibromatosis is a benign neurogenic tumor, originating from Schwann cells of the nerve sheath. This tumor forms a round, white mass on the course of the involved nerve. It occurs sporadically or in association with von Recklinghausen's disease. Laryngeal involvement is a rare occasion that affects women more than men (F/M ratio 3:2). The most common symptoms are hoarseness, dyspnea and dysphagia. The most common sites of origin are arytenoids and aryepiglottic folds. Because of benign nature of this tumor, conservative surgery is recommended as the management of choice. Only few cases of laryngeal involvement have been reported in literature and this article presents two cases of laryngeal neurofibroma with brief review of literatures. Both cases presented with submucosal, non-ulcerated, endolaryngeal mass with signs and symptoms of airway compromise. In both cases surgical approach was endolaryngeal conservative surgery with CO<sub>2</sub> laser.

© 2008 Tehran University of Medical Sciences. All rights reserved.

*Acta Medica Iranica* 2008; 46(4): 345-348.

**Key words:** Neurofibroma, endolaryngeal tumor, neurofibromatosis, CO<sub>2</sub> laser

---

## INTRODUCTION

Neurofibroma is a neurogenic tumor, originating from peripheral nerves (1). It occurs sporadically or in association with von Recklinghausen's disease. This benign tumor arise from the Schwann cells in the nerve sheath (1-3), and forms a round white, mass on the course of the involved nerve. In a study of 303 patients with benign solitary neurogenic tumors, Chen and colleagues reported that 44% of these neoplasms are located in the head and neck (2).

There are two types of neurofibromas: plexiform and non-plexiform in which the difference is at the cytoarchitectural level (4, 5). Most of the tumors are asymptomatic and present as a mass in lateral neck and if symptomatic usually manifest by obstructive airway symptoms (6, 7).

Laryngeal involvement is a rare presentation, reported for the first time in 1952 as an isolated endolaryngeal neurofibromatosis (8). In this rare occasion, the most common symptoms are hoarseness, dyspnea, and dysphagia. The most common sites of origin are arytenoids and aryepiglottic folds and it is extremely rare in the subglottic part. Women are affected more than men (2, 3, 9).

Histologically, neurofibromas are not encapsulated. Nerve fibers traverse and frequently are incorporated into the mass (1). Cystic and degenerative changes are uncommon. Histology shows spindle cell pattern with elongated nuclei (1). Tumors may be multiple when seen with von Recklinghausen's disease. von Recklinghausen's disease (neurofibromatosis) is an autosomal dominant trait (10). The disease may be associated with other neurologic abnormalities or developmental anomalies, such as glioma or spina bifida (1). Cranial nerve (CN) II and CN VIII (optic and acoustic) most often are involved (1). El-Serafy reported a syndrome of mucosal neurofibroma, pheochromocytoma and medullary carcinoma (11).

---

Received: 15 Aug. 2006, Revised: 15 Oct. 2006, Accepted: 17 Feb. 2007

**\* Corresponding Author:**

Masoud Ahmadzad-Asl, Department of Clinical Researches, Nikan Health Researchers Institute, Tehran, Iran

Tel: +98 21 44468646

Fax: +98 21 44476796

E-mail: m.ahmadzad@gmail.com

## Endolaryngeal neurofibroma

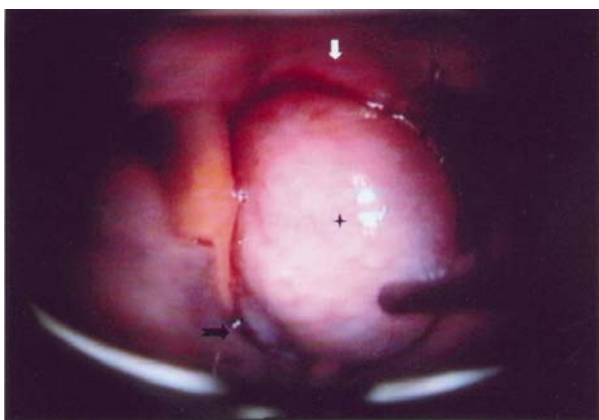
In patients with von Recklinghausen's disease, 4.6% to 16% have shown sarcomatous transformation (1, 12). Chang-Lo presented a review of 19 cases of von Recklinghausen's disease with laryngeal involvement and also reported one new case (13). Supance, Quenelle and Crissman have reported that solitary neurofibromas of the larynx are more common than those associated with von Recklinghausen's disease (10). Because of benign nature of this tumor, conservative surgery is recommended as the management of choice (1).

According to the literature review, only few cases of laryngeal neurofibromas have been reported (1). In this report two cases of laryngeal neurofibroma are presented. Preoperative diagnosis of the first case was not obvious; but in the second case, presence of multiple café-au-lait macules on patient's body implied the diagnosis of neurofibromatosis.

## CASE REPORTS

### Case 1

On April 2000, a 34-year-old man was referred to ENT-Head and Neck Clinic of Hazrat-e-Rasoul Hospital, Tehran, Iran, with chief complaint of gradual deterioration of his voice quality since his early teens. During recent 9 months exertional dyspnea had been superimposed. On indirect mirror laryngoscopic examination a smooth lobulated mass on the right arytenoids and aryepiglottic fold was detected. The mass had completely obscured view of endolarynx and pushed epiglottis to opposite site (Fig. 1). In soft tissue radiographies of the neck, a supraglottic soft tissue mass was revealed.



**Fig 1.** Endolarynx view of mass that completely obscured and pushed epiglottis to opposite site.

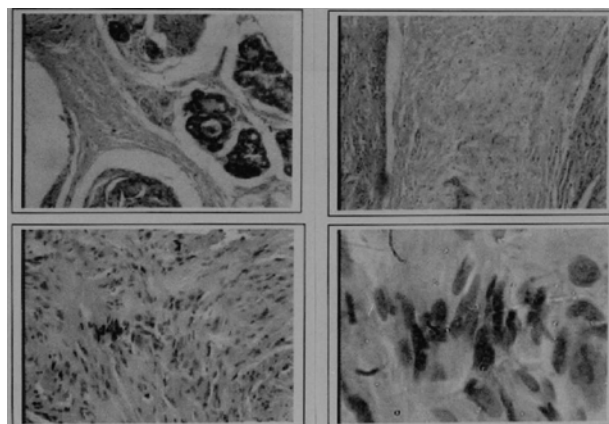
Cervical contrasted CT scanning showed a well-circumscribed soft tissue mass in right posterior glottic region and aryepiglottic fold. The patient was candidate for diagnostic laryngoscopy under general anesthesia with a small-sized orotracheal intubation. On direct laryngoscopy, a submucosal mass on the right arytenoid and aryepiglottic fold was revealed. There was no mucosal ulceration or local inflammation. Because of benign appearance of the tumor, the mass partially excised by CO<sub>2</sub> laser (5 watt, continuous mode). Sections showed stratified squamous epithelium underlined by tumoral lesion composed of irregular cylindrical and fusiform large nervous fascicles, embedded in a cellular matrix containing abundant mucine, fibroblasts and Schwann cells with histopathologic diagnosis of plexiform neurofibroma (Fig. 2).

Complete excision of the tumor was performed. There has not been any recurrence of symptoms or physical findings in regular follow up visits for 3 years.

### Case 2

On April 2000, a 17-month-old boy was referred to ENT-Head and Neck Department of Hazrat-e-Rasoul Hospital, Tehran, Iran. He had a history of mild respiratory distress after birth with gradual deterioration. For the first months, diagnosis of laryngomalacia was suggested by pediatricians and they recommended watchful waiting.

One year later, following an episode of upper respiratory tract infection, a severe respiratory distress occurred and the patient was intubated in another medical center.

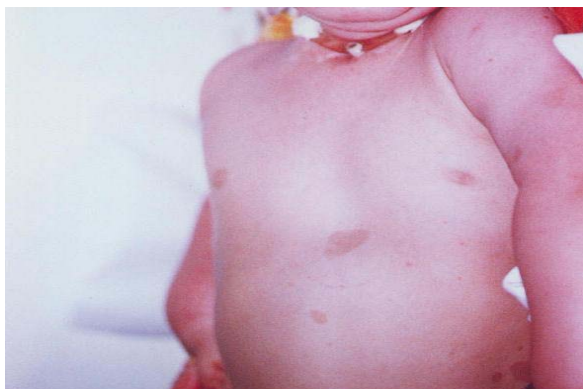

**Fig. 2.** Optical microscope view of case No.1 with the diagnosis of plexiform neurofibroma.

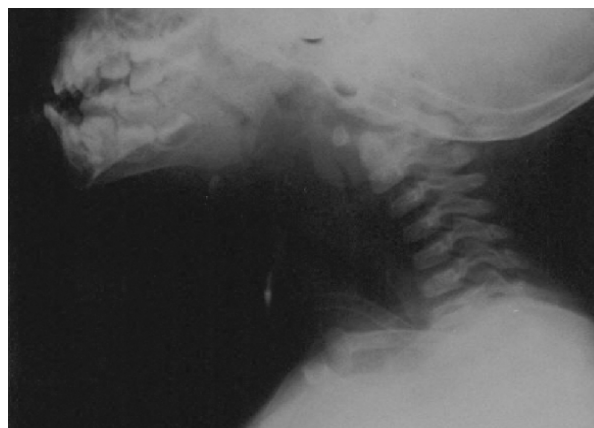
According to his medical file, after several days of oral intubation in ICU, tracheotomy was performed in the same center and finally because of unsuccessful attempt to weaning the tracheotomy, he was referred to our center.

On physical examination, multiple café-au-lait macules were obvious on his body and extremities (Fig. 3). On indirect laryngoscopy, a smooth, lobulated mass was detected on the right arytenoid and posterior glottis, completely obscuring endolaryngeal view. Cervical soft tissue radiographies revealed a supraglottic mass, with near total obstruction of the airway. An stomal granulation tissue was detected on the site of tracheotomy (Fig. 4). According to the history and physical examination, diagnosis of neurofibromatosis was suspected and the patient underwent 3 stages of endolaryngeal mass excision by CO<sub>2</sub> laser (5 watt, continuous mode). These submucosal masses were on the right arytenoids and posterior glottis. The stomal granulation tissue removed in the last stage of the surgeries.

In first operation, sections showed stratified squamous epithelium with multiple nests of spindle shape cells with whorl pattern in a myxoid background in lamina propria. The histopathologic findings reported as compatible with myxoid neurofibroma. In second operation, sections revealed fragments of tissue, including squamous mucosa. The mucosal epithelium was slightly acanthotic, the submucosa was markedly telangiectatic and edematous, containing numerous hypertrophic nerve fibers with plexiform pattern and some degree of degeneration. The histopathologic diagnosis was plexiform neurofibroma.



**Fig. 3.** Multiple café-au-lait macules at the first year of life of case no.2 with laryngeal neurofibroma.



**Fig. 4.** Supraglottic mass, with near total obstruction of the air way in cervical radiography.

Three days after final operation, the tracheotomy tube was weaned successfully. After regular follow up visits for 6 months, there has not been any sign or symptoms of tumor recurrence.

We obtained informed consent to publish details of both patients' history.

## DISCUSSION

Neurogenic tumors of the larynx are very rare, and solitary neurogenic tumors are more common than those associated with multiple neurofibromas (13). These tumors may be indicative of the genetic neurofibromatosis syndrome, which may be associated with severe neurologic problems, as well as risk of malignant transformation of the tumors (1). When a neurofibroma is found, a careful search for other manifestations which include café-au-lait spots and axillary freckling, as well as family history, should be carried out to rule out the syndrome (1).

Histologically, neurofibroma is a benign tumor, originating from Schwann cells of the nerve sheath. This tumor forms a round, white mass on course of the involved nerve and is not encapsulated. It is identified by prominent collagen production and trapped nerve fibers (14). In addition, high concentration of diffusely distributed mast cells is characteristic for neurofibroma (15).

Clinically, women are affected more than men with ratio of 3:2 (9). The most common symptoms are hoarseness, dyspnea (most striking) and dysphagia. The most common site of involvement is supraglottic region (aryepiglottic folds and

arytenoids) (13), as seen in our cases. Because of slow growing nature of the tumor, symptoms can last several months or even years before they interfere with patient's normal life style (13), as seen in the first case. On physical examination, lobulated nodules ranging from 2 to 8 mm in diameter have been reported (9). Interestingly, in literature review less than 30 cases of endolaryngeal neurofibroma have been reported up to 2000 (16); only 2 of them had occurred outside of the most common sites: one of them was limited to vocal folds and the other originated from subglottic region (17).

Definite diagnosis is based on histopathologic report. Imaging studies performed prior to surgical excision may aid in diagnosis (1). As we saw in our patients, the most common sign in plain radiography is a supraglottic soft tissue mass. CT scan also reveals a well-circumscribed mass in glottic or supraglottic region. Some neurofibromas undergo fatty degeneration with fat replacement, and may mimic a lipoma on CT or MRI (1).

The goal of surgery in neurogenic tumors is to separate the mass from the nerve trunk without permanent loss of function. This may be impossible in neurofibromas (1). Therefore, because of benign nature of these tumors, a conservative approach is preferred to extensive radical excision (1). For small tumors, this can be best performed by CO<sub>2</sub> laser excision; but in large tumors, external approaches may be necessary (*e.g.* lateral pharyngotomy, laryngofissure and lateral thyrotomy) (17). Lack of a definite capsule, makes the complete excision difficult and results in postoperative recurrence. To avoid recurrence, complete excision with frozen section control of tumor borders, has also been reported (13). A case of solitary endolaryngeal neurofibroma which recurred after 8 attempts for removal has also been reported in literature (15). After years of follow up visits, there has not been any report of recurrence in our cases.

## REFERENCES

1. Zobell DH. Massive neurofibroma of the larynx. case report. *Laryngoscope*. 1964 Feb; 74:233-240.
2. Chen YW, Fang TJ, Li HY. A solitary laryngeal neurofibroma in a pediatric patient. *Chang Gung Med J*. 2004 Dec; 27(12):930-933.
3. Gstöttner M, Galvan O, Gschwendtner A, Neher A. Solitary subglottic neurofibroma: a report of an unusual manifestation. *Eur Arch Otorhinolaryngol*. 2005 Sep; 262(9):705-707.
4. Osete Albadalejo JM, Díaz Manzano JA, Medina Banegas A, López Meseguer E, Blasco Muñoz PD. [Laryngeal neurofibroma. A case report and literature review]. *An Otorrinolaringol Ibero Am*. 2003; 30(2):171-177. Spanish.
5. Chang-Lo M. Laryngeal involvement in Von Recklinghausen's disease: a case report and review of the literature. *Laryngoscope*. 1977 Mar; 87(3):435-442.
6. Oliver KS, Diab AE, Abu-Jaudeh CN. Solitary neurofibroma of the larynx. *Arch Otolaryngol*. 1948; 47: 177-179.
7. Chen YC, Lee KS, Yang CC, Chang KC. Laryngeal neurofibroma: case report of a child. *Int J Pediatr Otorhinolaryngol*. 2002 Sep 2;65(2):167-170.
8. Hollinger PH, Cohen LL. Neurofibromatosis (von Recklinghausen's disease) with involvement of the larynx: report of a case. *Laryngoscope*. 1950; 60: 193-196.
9. Pearlman SJ, Friedman EA, Appel M. Neurofibroma of the larynx. *Arch Otolaryngol*. 1950 Jul; 52(1):8-14.
10. Supance JS, Quenelle DJ, Crissman J. Endolaryngeal neurofibromas. *Otolaryngol Head Neck Surg*. 1980 Jan-Feb; 88(1):74-78.
11. el-Serafy S. Rare benign tumors of the larynx. *J Laryngol Otol*. 1971 Aug; 85(8):837-851.
12. Abell MR, Hart WR, Olson JR. Tumors of the peripheral nervous system. *Hum Pathol*. 1970 Dec; 1(4):503-551.
13. Isaacson P. Mast cells in benign nerve sheath tumours. *J Pathol*. 1976 Aug; 119(4):193-196.
14. Figi FA, Stark DB. Neurofibroma of the larynx; presentation of five cases. *Laryngoscope*. 1953 Jul; 63(7):652-659.
15. Mevio E, Galioto P, Scelsi M, Re P. Neurofibroma of vocal cord: case report. *Acta Otorhinolaryngol Belg*. 1990;44(4):447-450.
16. Tanaka H, Patel U, Coniglio JU, Rubio A. Solitary subglottic neurofibroma: MR findings. *AJNR Am J Neuroradiol*. 1997 Oct; 18(9):1726-1728.
17. Cummings CW, Montgomery WW, Balogh K Jr. Neurogenic tumors of the larynx. *Ann Otol Rhinol Laryngol*. 1969 Feb; 78(1):76-95.