

THE RESULTS OF RADIAL OPTIC NEUROTOMY FOR TREATMENT OF CENTRAL RETINAL VEIN OCCLUSION

S. A. Tabatabaie, S. A. Rasoolnejad, S. Moghimi, H. Faghihi, A. Mirshahi, M. Riazi-Esfahani, R. Karkhane, M. Nili-Ahmadabadi*, A. Javadian, M. S. Farahvash, M. R. Mansouri, Z. Alami-Harandi, M. Movasat, A. Abdollahi and H. Shams

Department of Ophthalmology, Farabi Eye Research Center, School of Medicine, Tehran University of Medical Sciences, Tehran, Iran

Abstract- Central retinal vein occlusion (CRVO) is the third most common blinding vascular retinal disorder. As there is no proven treatment for CRVO, we performed this study to evaluate the effectiveness of radial optic neurotomy (RON) on visual acuity in eyes with CRVO. This study was designed as an interventional case series. Pars plana vitrectomy with RON was performed in 18 eyes of 16 patients with ischemic CRVO with visual acuities of 20/400 or less. Postoperative and preoperative visual acuities were compared using *t* paired test. Mean preoperative visual acuity was 20/1000 (range, 20/1600 to 20/630). Mean follow-up time was 3.6 months (range, 1 to 9 months). Mean postoperative visual acuity was 20/400 (range, 20/1600 to 20/50) at last follow-up and the difference was significant ($P < 0.01$; *t* paired test). Six patients (33%) improved to 20/200 postoperatively. There were no major complications intraoperatively. Chorioretinal shunts developed in neurotomy site in 9 cases (50%) 4 to 10 weeks after procedure which were associated with faster resolving of hemorrhage and venous dilation. There were no major complications noted with this procedure but vitreous hemorrhage and iris neovascularization was observed in the early postoperative period in 2 (11%) of 18 cases. RON may improve visual acuity in eyes with CRVO. It is a technically feasible and fairly safe procedure but postoperatively it may result in some complications such as vitreous hemorrhage, iris neovascularization and retinal detachment.

© 2008 Tehran University of Medical Sciences. All rights reserved.

Acta Medica Iranica 2008; 46(5): 373-378.

Key words: Central retinal vein occlusion, radial optic neurotomy, vitrectomy

INTRODUCTION

Central retinal vein occlusion (CRVO) is the third most common blinding vascular retinal disorder after diabetic retinopathy and branch retinal vein occlusion (1, 2). Among patients with CRVO, 34% develop capillary nonperfusion and retinal ischemia. Iris neovascularization and neovascular glaucoma may occur in 45% to 85% of the eyes affected

by ischemic CRVO and only in 5% of the nonischemic eyes (2, 3).

The pathogenesis of CRVO is not well understood. Thrombus formation at the cribriform plate may be a primary or secondary event in CRVO (4, 5). It was hypothesized that the anatomy of the optic nerve head may play a role in the pathogenesis of CRVO (6).

The Central Retinal Vein Occlusion Study reported the natural history and visual prognosis of CRVO. In 80% of the eyes with initial visual acuity less than 20/200, visual acuity was unchanged or decreased at the final visit. Eyes with intermediate visual acuity of 20/50 to 20/200 at the initial visit showed only a 19% rate of visual improvement (7).

Received: 28 Sep. 2006, Revised: 29 Apr. 2007, Accepted: 18 Jun. 2007

*** Corresponding Author:**

Mehdi Nili-Ahmadabadi, Farabi Eye Research Center, Quazvin Square, Tehran, Iran
Tel: +98 21 55416134
Fax: +98 21 55416134
E-mail: ma_nili@yahoo.com

Radial optic neurotomy for CRVO

Although pan-retinal laser photocoagulation prevents iris neovascularization (7) and grid macular laser photocoagulation decreases macular edema without visual improvement for patients with CRVO (8), there is no proven treatment that decreases retinal hemorrhage and edema and offers improvement in visual acuity. Although laser-induced chorioretinal venous anastomosis (9, 10) and surgical-induced chorioretinal anastomosis (11, 12) can improve retinal circulation, they may cause severe complications such as vitreous hemorrhage or choroidal neovascularization.

Radial optic neurotomy (RON) was described by Opremcak *et al.* in 2001. They proposed surgical decompression of the scleral outlet using a microvitrectomy blade (MVR) (6). They observed increased perfusion in most cases with no significant complications.

As there is no proven treatment for CRVO, we conducted a prospective study to determine the visual results of patients with CRVO and low visual acuity (VA) treated with radial optic neurotomy and to determine the safety of the surgical technique.

MATERIALS AND METHODS

In an interventional case series study, from June 2002 to March 2004, 18 eyes of 16 patients with CRVO underwent pars plana vitrectomy with RON at the Farabi Eye Hospital. All patients met the following criteria: 1) onset of CRVO less than 12 months; 2) severe hemorrhage in funduscopy; and 3) initial visual acuity worse than 20/400.

Exclusion criteria were presence of optic atrophy or macular scar. Study patients underwent initial ophthalmoscopic evaluation, and fluorescein angiography. Written Informed consent was obtained from all the patients after complete explanation. The review board and ethical committee of Eye Research Center of Tehran University of Medical Sciences approved the trial.

The same surgeon performed all procedures. A standard three-port vitrectomy was performed. If the posterior hyaloid was attached, it was then surgically detached and removed. A site on the nasal edge of the optic disk that avoided the major retinal vessels was chosen using the fluorescein angiogram for

radial optic neurotomy. A standard microvitrectomy blade was used, transecting an equal portion of the lamina cribrosa and adjacent retina without perforating the globe or cutting the major retinal vessels (a single radial cut was made on the nasal aspect of the optic disc to avoid damage to the major nasal retinal vessels).

After performing the radial optic neurotomy, with increasing bottle height, intraocular pressure was increased for about 2 minutes to avoid bleeding. No corticosteroids were injected during the procedure either intraocularly or periorbitally. Laser photocoagulation or gas tamponade was not used in any case. The sclerostomy sites and conjunctiva were closed in the usual fashion.

Postoperatively, patients were evaluated with best-corrected visual acuity, ophthalmoscopic examination and fluorescein angiography. Best corrected visual acuity at baseline and during follow up was checked using standard Snellen chart, and the result was converted to logarithm of the minimum angle of resolution (logMAR) to allow statistical analysis. The relation between preoperative and postoperative VA was calculated using the *t* paired test. Data were analyzed with SPSS 10.5 (SPSS Inc). $P < 0.05$ was considered statistically significant.

RESULTS

Eighteen eyes of 16 patients (8 male, 8 female) underwent RON (Table 1). The average age of the patients was 55 years (range, 20-81 years). There were 12 (67%) left eyes with CRVO. Preoperative duration of symptoms ranged from 1 to 7 months with a mean of 2.5 months.

Preoperative best-corrected VA ranged from 20/1600 (1.9 logMAR) to 20/630 (1.5 logMAR) with mean of 20/1000 (1.75 logMAR). Of the 18 eyes, systemic hypertension was present in 6 (33%), diabetes mellitus in 7 (39%) and open-angle glaucoma in 5 (28%). Fifteen of the 18 (83%) eyes with CRVO had an afferent pupillary defect. In other three afferent pupillary defect could not be evaluated, as either they were one-eyed (eye no 18, Table 1) or the disease was bilateral. None of eyes had iris neovascularization. All of them had macular edema.

Table 1. Characteristics of patients with central retinal vein occlusion

No	Sex	Age (yr)	Risk factors	Duration of symptoms (mo)	Preop APD	Visual acuity		Postop Collateral	Follow Up (mo)
						Preop	Postop		
1	F	81	-	2	1+	20/1000	20/1000	-	2
2	M	60	HTN, DM, Glau	1	2+	20/1000	20/60	+	5
3	M	50	-	7	2+	20/1250	20/250	+	1
4	M	54	-	1	1+	20/1250	20/400	-	1
5	F	22	Glau	3	3+	20/1000	20/50	+	6
6	M	20		1	3+	20/630	20/200	-	4
7	F	74	HTN	4	2+	20/1000	20/400	+	5
8	M	72	-	2	2+	20/1000	20/1000	-	4
9	M	72	-	3	2+	20/1250	20/400	-	5
10	F	64	HTN, DM	3	1+	20/1250	20/200	+	4
11	F	45	DM	4	2+	20/1600	20/1600	-	3
12	F	40	HTN, DM, Glau	1	1+	20/1250	20/500	-	9
13	F	70	HTN, Glau	2	?	20/1250	20/250	+	9
14	M	52	DM	4	+1	20/1250	20/500	+	3
15	M	52	DM	2	?	20/1000	20/200	-	1
16	F	60	-	2	2+	20/1250	20/630	+	1
17	M	53	-	2	2+	20/1000	20/200	+	1
18	M	60	HTN, DM, Glau	2	?	20/1250	20/1000	-	1

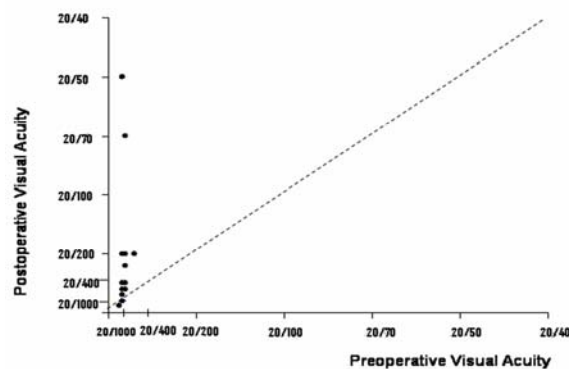
Abbreviations: yr, years; mo, months; APD, afferent pupillary defect; DM, diabetes mellitus; Glau, glaucoma; F, female; HTN, hypertension; M, male; Postop, postoperative; Preop, preoperative.

Radial optic neurotomy was successfully performed in 18 consecutive cases. A small amount of bleeding occurred in 3 of the 18 (17%) cases from the radial optic neurotomy site but stopped with intraoperative elevation of intraocular pressure.

Mean follow-up time was 3.6 months (range, 1 to 9 months). Postoperative VAs ranged from 20/1600 (1.9 logMAR) to 20/50 (0.4 logMAR) with mean of 20/400 (1.32 logMAR). The difference between the preoperative and postoperative VA levels was statistically significant ($P < 0.01$; t paired test). Six of 18 eyes (33%) had a final visual acuity of 20/200 or better. In one eye final visual acuity reached to 20/50 and in another it reached to 20/60 (Fig. 1).

Nine cases (50%) developed postoperative chorioretinal shunts at the site of the RON. These cilioretinal shunts appeared between 4 weeks and 10 months after surgery, with a mean of 8 weeks and were associated with faster resolving of hemorrhage and venous dilation. Iris neovascularization, vitreous hemorrhage and increased IOP was observed in the

early postoperative period in 2 (11%) of 18 cases. One of them underwent photocoagulation and Molteno implantation. The other did not permit us any other surgical intervention and did not return for follow up. One of our patients was complicated by retinal detachment due to a retinal break that situated 1 DD inferior to the optic disk. Pars plana vitrectomy and silicone injection was performed for him immediately (eye no 8, Table 1).

**Fig. 1.** Preoperative and postoperative visual acuities

DISCUSSION

Central retinal vein occlusion (CRVO) is the third most common blinding vascular retinal disorder after diabetic retinopathy and branch retinal vein occlusion (1, 2). The etiology and pathogenesis are not well understood. Hypertension and glaucoma have been associated with CRVO. Histopathologic studies of eyes enucleated for the complications of CRVO have shown a thrombus at the cribriform plate (4, 5).

The Central Retinal Vein Occlusion Study reported the natural history and visual prognosis of CRVO. In 80% of the eyes with initial visual acuity less than 20/200, visual acuity was unchanged or decreased at the final visit. Eyes with intermediate visual acuity of 20/50 to 20/200 at the initial visit showed only a 19% rate of visual improvement (7).

Panretinal photocoagulation is the preferred treatment for resultant neovascularization of the angle or iris, but it is not performed as a prophylactic measure (7). Various experimental treatments for CRVO are currently being studied, including laser-induced chorioretinal venous anastomosis (9, 11), surgical-induced chorioretinal anastomosis (11, 12), intravitreal tissue plasminogen activator (13) and intravitreal triamcinolone acetonide (14). Although laser-induced chorioretinal venous anastomosis and surgical-induced chorioretinal anastomosis can improve retinal circulation, they may cause severe complications such as vitreous hemorrhage or choroidal neovascularization (9-12). Radial optic neurotomy is also an experimental treatment option (6, 15-17).

According to Opremcak and associates, the purpose of RON is to promote decompression of the central retinal vein in the scleral ring and the lamina cribrosa (6). If RON can relax venous compression within the scleral outlet, retinal circulation time can be reduced after the procedure (6, 18).

The scleral outlet is defined as the space confined by the scleral ring containing the cribriform plate (lamina cribrosa), the central retinal artery, central retinal vein, and the optic nerve, and theoretically, release of the pressure via RON would increase the central retinal vein lumen size and thus both increase venous blood outflow and allow for clearing of any venous thrombosis (6, 15, 18).

In our series of 18 consecutive patients with severe CRVO, RON appears to be a surgically feasible and fairly safe procedure. Nevertheless, the improvement in the VA of our patients has not been as high as that reported by others. Only 6 of 18 our cases (33%) had a final visual acuity of 20/200 or better, yet, 45% of Opremcak *et al.* cases (6), 50% of García-Arumí *et al.* cases (15) and 40% of Weizer *et al.* cases (16) had final VA of 20/70 or better. One reason for this may be lower visual acuity of our patients at presentation and positive afferent pupillary defect in most of them. Also two patients in our study developed neovascular glaucoma and vitreous hemorrhage that needed reoperation. This may be another reason for lower final VA in our cases. Because radial optic neurotomy is a relatively straightforward surgical technique, the surgeon's learning curve is not likely to be a major factor (16).

New chorioretinal shunts developed in 9 (50%) of 18 cases at the site of the radial optic neurotomy, creating a new pathway of venous outflow. It was hypothesized (15) that improvement in these patients may occur by the following different mechanisms: 1) by relieving mechanical pressure exerted on the central retinal vein by the distended optic nerve, thereby improving retinal blood flow; more over, 2) by using vitrectomy and posterior hyaloid peeling that have been shown experimentally to decrease macular edema, and 3) by improving of the oxygen exchange between the retina and the vitreous cavity and thus helping decrease macular edema (19). It is also believed that the collaterals formed after the neurotomy are more active in draining the edema and hemorrhages than those achieved after application of argon laser spots (6, 15). In addition, their location close to the optic nerve makes them more effective (15).

RON is performed in close proximity to very delicate and critical structures of the optic nerve head. Potentially serious complications would include laceration of the central retinal artery or central retinal vein, optic nerve damage, globe perforation, and retinal detachment (6). Although Opremcak and coauthors did not report any complication in their cases (6), small bleeding occurred in 3 of the 18 cases from the radial optic

neurotomy site. This stopped with intraoperative elevation of intraocular pressure. Intraoperative bleeding from the radial optic neurotomy site has also been reported by García-Arumí *et al.* (15) and Weizer *et al.* (16).

Two patients in our study developed neovascular glaucoma and vitreous hemorrhage that needed reoperation. Releasing angiogenic factor into anterior chamber has been proposed to be one reason for developing neovascular glaucoma (19). Samuel *et al.* have described a case of peripapillary retinal detachment without break after RON but others have not (20). One of our patients was complicated by retinal detachment due to a retinal break that situated 1 DD inferior to the optic disk. He needed vitrectomy and silicone injection.

In conclusion, radial optic neurotomy may improve visual acuity in eyes with CRVO and low VA. It may be complicated by neovascular glaucoma, vitreous hemorrhage and retinal detachment postoperatively and these complications may question long-term safety of the procedure. We do not suggest RON in nonischemic CRVO due to its good natural outcome. Further studies, including randomized clinical trials, are needed to confirm the effect of RON on anatomic and functional improvement.

Acknowledgements

This study was supported by a grant from Tehran University of Medical Sciences (TUMS).

Competing interests

The authors declare that they have no competing interests.

REFERENCES

- [No authors listed]. Baseline and early natural history report. The Central Vein Occlusion Study. Arch Ophthalmol. 1993 Aug; 111(8):1087-1095.
- [No authors listed]. Risk factors for central retinal vein occlusion. The Eye Disease Case-Control Study Group. Arch Ophthalmol. 1996 May;114(5):545-554.
- Rath EZ, Frank RN, Shin DH, Kim C. Risk factors for retinal vein occlusions. A case-control study. Ophthalmology. 1992 Apr;99(4):509-514.
- Green WR, Chan CC, Hutchins GM, Terry JM. Central retinal vein occlusion: a prospective histopathologic study of 29 eyes in 28 cases. Trans Am Ophthalmol Soc. 1981;79:371-422.
- Hayreh SS. Pathogenesis of occlusion of the central retinal vessels. Am J Ophthalmol. 1971 Nov;72(5):998-1011.
- Opremcak EM, Bruce RA, Lomeo MD, Ridenour CD, Letson AD, Rehmar AJ. Radial optic neurotomy for central retinal vein occlusion: a retrospective pilot study of 11 consecutive cases. Retina. 2001;21(5):408-415.
- [No authors listed]. Natural history and clinical management of central retinal vein occlusion. The Central Vein Occlusion Study Group. Arch Ophthalmol. 1997 Apr;115(4):486-491.
- [No authors listed]. A randomized clinical trial of early panretinal photocoagulation for ischemic central vein occlusion. The Central Vein Occlusion Study Group N report. Ophthalmology. 1995 Oct;102(10):1434-1444.
- McAllister IL, Douglas JP, Constable IJ, Yu DY. Laser-induced chorioretinal venous anastomosis for nonischemic central retinal vein occlusion: evaluation of the complications and their risk factors. Am J Ophthalmol. 1998 Aug;126(2):219-229.
- Browning DJ, Antoszyk AN. Laser chorioretinal venous anastomosis for nonischemic central retinal vein occlusion. Ophthalmology. 1998 Apr;105(4):670-677.
- Fekrat S, de Juan E Jr. Chorioretinal venous anastomosis for central retinal vein occlusion: transvitreal venipuncture. Ophthalmic Surg Lasers. 1999 Jan;30(1):52-55.
- Peyman GA, Kishore K, Conway MD. Surgical chorioretinal venous anastomosis for ischemic central retinal vein occlusion. Ophthalmic Surg Lasers. 1999 Sep-Oct;30(8):605-614.
- Glacet-Bernard A, Kuhn D, Vine AK, Oubraham H, Coscas G, Soubrane G. Treatment of recent onset central retinal vein occlusion with intravitreal tissue plasminogen activator: a pilot study. Br J Ophthalmol. 2000 Jun;84(6):609-613.
- Greenberg PB, Martidis A, Rogers AH, Duker JS, Reichel E. Intravitreal triamcinolone acetate for macular oedema due to central retinal vein occlusion. Br J Ophthalmol. 2002 Feb;86(2):247-248.

Radial optic neurotomy for CRVO

15. García-Arumí J, Boixadera A, Martínez-Castillo V, Castillo R, Dou A, Corcostegui B. Chorioretinal anastomosis after radial optic neurotomy for central retinal vein occlusion. *Arch Ophthalmol*. 2003 Oct;121(10):1385-1391.
16. Weizer JS, Stinnett SS, Fekrat S. Radial optic neurotomy as treatment for central retinal vein occlusion. *Am J Ophthalmol*. 2003 Nov;136(5):814-819.
17. Williamson TH, Poon W, Whitefield L, Strothidis N, Jaycock P. A pilot study of pars plana vitrectomy, intraocular gas, and radial neurotomy in ischaemic central retinal vein occlusion. *Br J Ophthalmol*. 2003 Sep;87(9):1126-1129.
18. Nomoto H, Shiraga F, Yamaji H, Kageyama M, Takenaka H, Baba T, Tsuchida Y. Evaluation of radial optic neurotomy for central retinal vein occlusion by indocyanine green videoangiography and image analysis. *Am J Ophthalmol*. 2004 Oct;138(4):612-619.
19. Musser GL, Rosen S. Localization of carbonic anhydrase activity in the vertebrate retina. *Exp Eye Res*. 1973 Jan 1;15(1):105-119.
20. Samuel MA, Desai UR, Gandolfo CB. Peripapillary retinal detachment after radial optic neurotomy for central retinal vein occlusion. *Retina*. 2003 Aug;23(4):580-583.