

MALIGNANT LYMPHOMA DEMONSTRATING SICK SINUS SYNDROME AND SUPERIOR VENA CAVA SYNDROME

S. K. Forouzannia^{*1}, M. H. Abdollahi¹, S. J. Mirhosseini¹, S. H. Moshtaghion¹, H. Hosseini¹, M.V. Jorat²,
M. Moeeni¹ and M. A. Karimi-Zarchi¹

1) Department of Cardiovascular Surgery, Afshar Hospital, Shahid Sadooghi University of Medical Sciences, Yazd, Iran

2) Department of Cardiology, Afshar Hospital, Shahid Sadooghi University of Medical Sciences, Yazd, Iran

Abstract- Reports which describe sick sinus syndrome due to malignant lymphoma have been rare and only eight cases have been reported until now. This is a case of sick sinus syndrome and superior vena cava syndrome secondary to invasion of occult malignant lymphoma of the lung in a 60 years old male. There were no symptoms or signs of malignancy before the first presentation with sick sinus syndrome. Patient was treated with implantation of a permanent pacemaker. SA node involvement by lymphoma should be considered as an etiological factor when sick sinus syndrome of unknown cause is encountered.

© 2008 Tehran University of Medical Sciences. All rights reserved.

Acta Medica Iranica 2008; 46(5): 437-440.

Key words: Sick sinus syndrome, superior vena cava syndrome, malignant lymphoma

INTRODUCTION

Malignant lymphoma frequently involves the heart. However, it is difficult to detect by clinical examination because of insufficient symptoms (1). Signs suggesting involvement of the heart by malignant tumors are congestive heart failure, arrhythmia, and superior vena cava syndrome (2). Reports which describe sick sinus syndrome due to malignant lymphoma have been rare and only eight cases have been reported until now (3-10).

Here we report a case of sick sinus syndrome and superior vena cava syndrome secondary to invasion of occult malignant lymphoma of the lung in a 60 years old male.

CASE REPORT

A 60 years old male with chief complain of chest discomfort, dizziness and weakness admitted in our department.

The electrocardiograph (ECG) showed frequent sinus arrest (Fig. 1). He admitted with diagnosis of sick sinus syndrome and a permanent pacemaker was implanted. He had positive history for diabetic mellitus, hyperlipidemia, rheumatoid arthritis and amyloidosis. Hemogram and serum chemistry, tests were in normal limit. He was discharged without any problem.

One month later, patient presented with symptoms and signs of superior vena cava syndrome. Physical examination did not reveal any surface lymphadenopathy. Chest X-ray showed (Fig. 2) a mild increase in cardiothoracic ratio, without pleural and pericardial effusion and suspicious mass in the right border of heart. In laboratory tests white blood cell was $4.8/\text{mm}^3$ with normal differentiation, hemoglobin was 12 g/dl and platelets count was $216 \times 10^4/\text{mm}^3$. Erythrocyte sedimentation was 45

Received: 14 Jan. 2008, Revised: 29 Apr. 2008, Accepted: 29 Jun. 2008

* Corresponding Author:

S. K. Forouzannia, Department of Cardiovascular Surgery, Afshar Hospital, School of Medicine, Shahid Sadooghi University of Medical Sciences, Yazd, Iran
Tel: +98 351 5254067
Fax: +98 351 5253335
Email: drforouzan_nia@yahoo.com

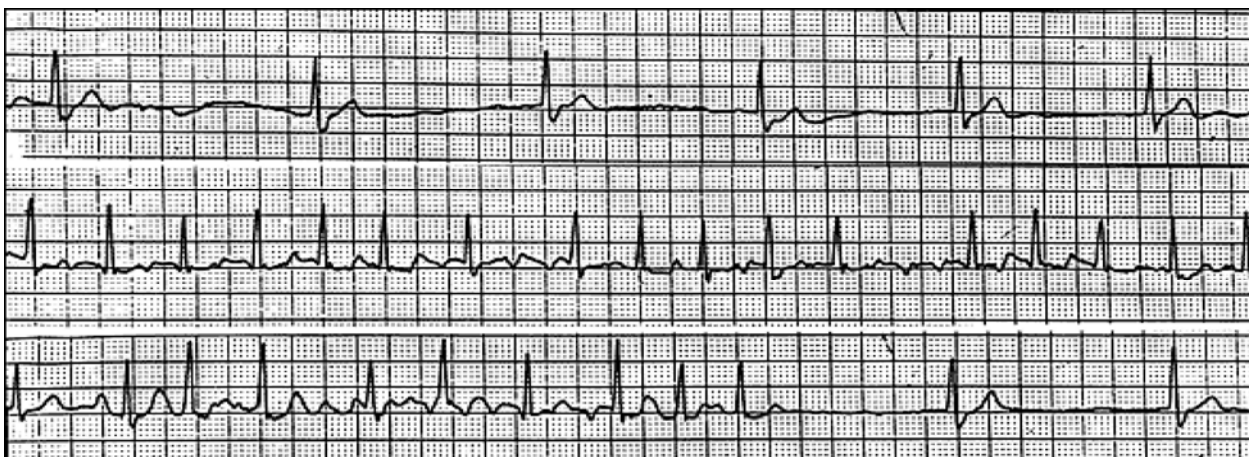


Fig. 1. Electrocardiogram shows frequent sinus arrest.

and CRP was 3+. Echocardiographic findings were clot in right atrium (RA).

Computed tomography scan with contrast showed a hypodense area in distal of superior vena cava (Fig. 3). Initially, patient was candidate for anticoagulant therapy with the diagnosis of thrombosis but because of unresponsiveness to medical management and progressive superior vena cava syndrome, he was selected for surgical management. Angiographic finding was left ventricular enlargement and ejection fraction about 50% and normal coronary arteries.

Surgical finding via media sternotomy was tumor of right lung with invasion to superior vena cava and right atrium. Incisional biopsy of tumor showed malignant lymphoma of diffuse large cell type (intermediate grade) (Fig. 4).

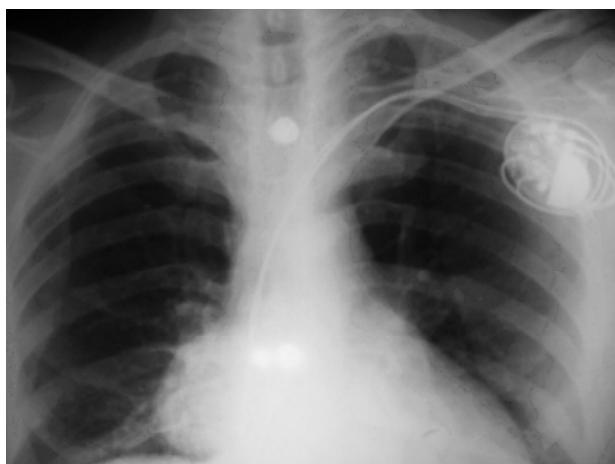


Fig. 2. Chest X-Ray showing suspicious mass on the right heart border.

DISCUSSION

In recent years only eight cases that have been reported to demonstrate sick sinus syndrome by lymphoma involvement including five men and three women with a median age of 63.3 years (range, 51 to 77 years). Three cases have been presented with sick sinus syndrome as the single initial symptom (6, 8, 10). Two cases sick sinus syndrome has not as initial single symptom (3, 6) and three as terminal manifestation (4, 5, 7). All of the three patients who presented sick sinus syndrome as the single initial symptom underwent implantation of a permanent pacemaker, whom was followed by superior vena cava syndrome one to two months later. As in our case, therefore, SA node involvement by lymphoma should be considered as an etiological factor when

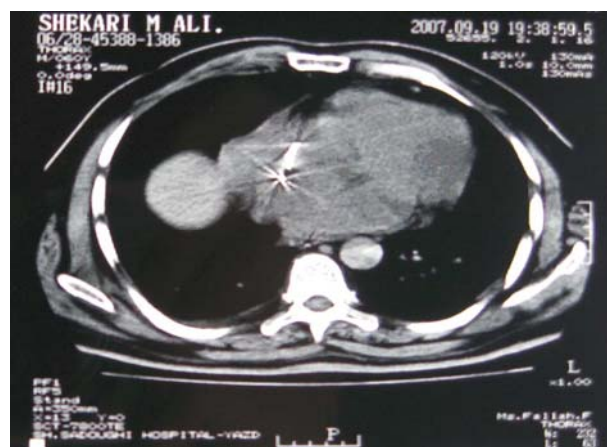


Fig. 3. Computed tomography scan with contrast showed the hypodense area around distal part of superior vena cava and dilatation of proximal superior vena cava.

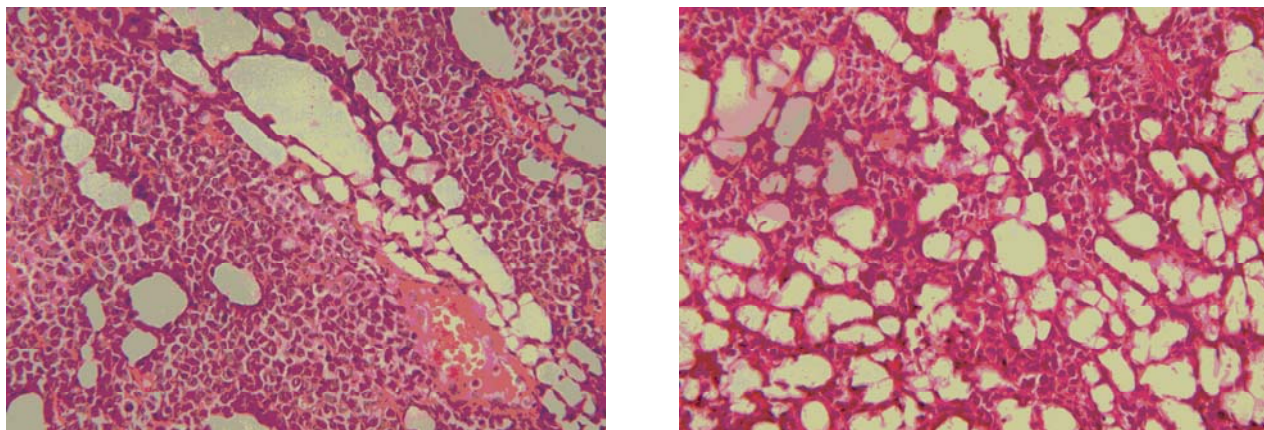


Fig. 4. Cytology and pathological study of biopsy specimen showed diffuse large cell type of lymphoma (intermediate grade).

sick sinus syndrome of unknown cause is encountered and close observation should be paid to detect the emergence of other cardiac involvement or already existing subclinical superior vena cava stenosis or pericardial effusion.

Microscopic findings have shown three types of functional cell: round nodal cells at the central portion, elongated transitional cells and working myocardial fibers at the peripheral regions have been distinguished in the collagenous tissue framework of the SA node (13). The nodal cells are surmised to create sinus rhythm and the transitional cells and myocardial fibers conduct the rhythm to the atrial myocardium. However, it is reported that the collagenous tissue increases with age (14).

In present case there was invasion of malignant lymphoma to superior vena cava and SA node. Therefore, it can be predicted that the conduction of the sinus rhythm from the nodal cells to the atrial myocardium via the transitional cells and working atrial muscle fibers was interrupted by the lymphoma infiltration and sick sinus syndrome can be occurred as a result.

Phenotypes of the lymphomas reported to involve the heart have not been examined fully (1, 2). Four out of eight reported cases showing sick sinus syndrome of unknown cause were demonstrated to be the diffuse large cell type of lymphoma (5, 7-9), and three were described as poorly differentiated lymphoma (4, 6, 10). In present case, lymphoma was of diffuse large cell type (intermediate grade).

REFERENCES

1. Roberts WC, Glancy DL, DeVita VT Jr. Heart in malignant lymphoma (Hodgkin's disease, lymphosarcoma, reticulum cell sarcoma and mycosis fungoides). A study of 196 autopsy cases. *Am J Cardiol.* 1968 Jul; 22(1):85-107.
2. Wilson LD, Detterbeck FC, Yahalom J. Clinical practice. Superior vena cava syndrome with malignant causes. *N Engl J Med.* 2007 May 3;356(18):1862-1869.
3. Martí G, Galve E, Huguet J, Soler Soler J. [Cardiac metastases of malignant melanoma mimicking sick sinus syndrome]. *Rev Esp Cardiol.* 2004 Jun;57(6):589-591. Spanish.
4. Donnelly MS, Weinberg DS, Skarin AT, Levine HD. Sick sinus syndrome with seroconstrictive pericarditis in malignant lymphoma involving the heart: a case report. *Med Pediatr Oncol.* 1981;9(3):273-277.
5. Yoshikawa H, Itoh N, Mizuno K, Itoh T, Hattori Y, Watanabe A, Yoshikawa S, Uno Y, Takamoto S, Nitta M, et al. [Adams-Stokes syndrome following cardiac tamponade in B-cell lymphoma involving the heart: a case report]. *Nippon Naika Gakkai Zasshi.* 1986 Oct; 75(10):1429-1437. Japanese.
6. Yano M, Nagaoka H, Yamada T. [A case of malignant lymphoma of the heart with sick sinus syndrome and superior vena cava syndrome]. *Nippon Kyobu Geka Gakkai Zasshi.* 1987 Feb;35(2):213-217. Japanese.
7. Ishibashi S, Yuo A, Nagai R, Oouchi Y, Imataka K, Yazaki Y, Takaku F, Oka T. [Sick sinus syndrome in malignant lymphoma involving the heart]. *Nippon Naika Gakkai Zasshi.* 1987 Jan; 76(1):100-105. Japanese.

Malignant lymphoma and SSS and SVC syndrome

8. Araki T, Namura M. Right atrial tumor and sick sinus syndrome. *Intern Med.* 2003 May;42(5):450-451.
9. Ishii M, Yamaguchi K, Takatsuki K. [Sick sinus syndrome as an initial symptom of B-cell malignant lymphoma involving the heart]. *Rinsho Ketsueki.* 1990 Jan; 31(1):80-84. Japanese.
10. Lénárd L, Szabados S, Imre J, Pintér O, Fazekas A, Tornai Z, Déczy K, Várady E, Papp L. [Vena cava superior syndrome: surgical treatment of the thrombosis of the superior vena cava after implantation of a hemodialysis catheter--a case report and review of the literature]. *Orv Hetil.* 2008 Jan 6;149(1):29-34. Hungarian.
11. Price LA, Gilkinson TL. Malignant superior vena cava syndrome presenting after trauma. *CJEM.* 1999 Jul;1(2):112-114.
12. Ferrer MI. The etiology and natural history of sinus node disorders. *Arch Intern Med.* 1982 Feb;142(2):371-372.
13. Barshes NR, Annambhotla S, El Sayed HF, Huynh TT, Kougias P, Dardik A, Lin PH. Percutaneous stenting of superior vena cava syndrome: treatment outcome in patients with benign and malignant etiology. *Vascular.* 2007 Sep-Oct;15(5):314-321.
14. Davies MJ, Pomerance A. Quantitative study of ageing changes in the human sinoatrial node and internodal tracts. *Br Heart J.* 1972 Feb;34(2):150-152.