

## Cerebral Vein Thrombosis: Screening of Acquired and Hereditary Thrombophilic Risk Factors

Payam Sarraf<sup>1</sup>, Majid Ghaffarpour<sup>\*1</sup>, Hosein Poormahmoodian<sup>1</sup>, Hosein Harrirchian<sup>1</sup>, and Hasan Hashemi<sup>2</sup>

<sup>1</sup> Department of Neurology, Imam Khomeiny Hospital, School of Medicine, Tehran University of Medical Sciences, Tehran, Iran

<sup>2</sup> Department of Radiology, Imam Khomeiny Hospital, School of Medicine, Tehran University of Medical Sciences, Tehran, Iran

Received: 8 Apr. 2007; Received in revised form: 4 Jun. 2007; Accepted: 18 Aug. 2007

**Abstract-** Cerebral vein thrombosis (CVT) is an infrequent condition with a large variety of causes that can lead to serious disabilities. However, in 20% to 35% of cases, no cause is found. In this study we evaluated the hereditary (P & C Proteins, antithrombin, mutation of prothrombin G20210A and factor V Leiden), other risk factors (hyperhomocysteinemia, factor VIII, ACL-ab, APL-ab, and OCP) and clinical manifestations among a population of Iranian patients with CVT. 18 women and 10 men aged 16 to 50 years with CVT were screened for inherited and acquired coagulation risk factors. No one had an abnormal ACL-ab, APL-ab or antithrombin III deficiency. One had prothrombin G20210A mutation (heterozygot) (3.6%). Hyperhomocysteinemia was observed in 5 patients (17.9%). APC-R was decreased in 3 (10.7%). 2 had positive factor V Leiden mutation (heterozygot) (7.1%). 17 had an increased of factor VIII (60.7). PS and PC deficiencies were each detected in two cases (7.1%). Conclusion: Our study suggests that screening for inherited thrombophilia may be an integral part in the diagnostic workup and duration of treatment in patients with CVT.

© 2009 Tehran University of Medical Sciences. All rights reserved.

*Acta Medica Iranica* 2009; 47(3): 197-202.

**Key words:** Cerebral vein thrombosis, thrombophilia, risk factors

### Introduction

Cerebral vein thrombosis is a relatively rare but severe thrombotic manifestation with a high mortality rate, the potential to cause disability, and the tendency to recur (1). One or more risk factors for thrombosis were seen in over 80% of 1100 patients with CVT reported in the last 10 years. Although this is an improvement over previous decades, when 25% to 50% of CVT was labeled as "idiopathic," in some 20% of patients with CVT the risk factors for CVT still go undetected. In addition to acquired risk factors for thrombosis, 10% to 15% of patients with CVT may also have a congenital form of thrombophilia (2). Numerous infective or noninfective conditions can cause CVT or predispose to it. They include all surgical, gynecologic-obstetric, and medical causes of leg vein thrombosis, as well as a number of local causes such as head injury, tumors, infusion into the internal jugular vein, and intracranial and regional infections (abscess, otitis, meningitis, etc). Hematologic disorders are infrequent but well-established causes; they include leukemias, thrombocythemias, red blood cell disorders and congenital or acquired coagulation disorders (3).

The prognosis of CVT varies from recovery to death. Underlying thrombophilia may have important practical consequences for the patient and his or her family interims of prevention (4). Objectives of our study were to perform screening thrombophilic tests of a consecutive series of patients with CVT and to search for a large variety of acquired and hereditary prothrombotic conditions, and its effect on anticoagulant therapy duration.

### Patients and Methods

Twenty-eight patients (women, men) diagnosed with CVT were admitted to our stroke unit between June 2004 and Sep. 2006. Patients having either of the following symptoms were suspected to CVT:

- 1-Altered consciousness
- 2-Focal neurological deficit
- 3-Seizure
- 4-Raised intracranial pressure (RICP) signs and symptoms such as headache, nausea, vomiting, diplopia and blurred vision.

Diagnosis was finally made on both magnetic resonance imaging with and without contrast and magnetic resonance venography

**\*Corresponding Author:** Majid Ghaffarpour

Department of Neurology, Imam Khomeiny Hospital, School of Medicine, Tehran University of Medical Sciences, Tehran, Iran  
Tel: +98 21 66948899, Fax: +98 21 66591319, E-mail: icnr@sina.tums.ac.ir

## CVT and thrombophilic risk factors

**Table 1.** Normal values of risk factors

APL	<10
ACL	<10
APC-R	>120
Antithrombin III	80-120
PS	65-140
PC	70-130
Plasma factor VIII	%50-%150
Homocystein	5-15

### Selected abbreviation and acronyms

ACL-ab	Anticardiolipin Antibody
APL-ab	Antiphospholipid Antibody
APC-R	Activated protein C-resistance
CVT	Cerebral venous thrombosis
PC	Protein C
PS	Protein S
OCP	Oral contraceptive pills

### Laboratory findings

Blood sample was taken of confirmed cases (before starting anticoagulant therapy) and checked for the following thrombophilic factors:

1. Evaluation of prothrombin G20210A gene mutation.
2. Activated protein C resistance measurement, if elevated evaluation of factor V Leiden.
3. Evaluation of plasma homocystein, in case of hyperhomocysteinemia despite normal levels of folic acid and B12, MTHFR test for C677T mutation was performed.

4. Measuring of antiphospholipid and anticardiolipin antibodies

5. Measuring of protein C and S and antithrombin III. If the level of these factors were decreased, a second recheck was performed 3 month later (after anticoagulant therapy was discontinued for at least 1 week.)

6. Measuring of coagulating factor VIII

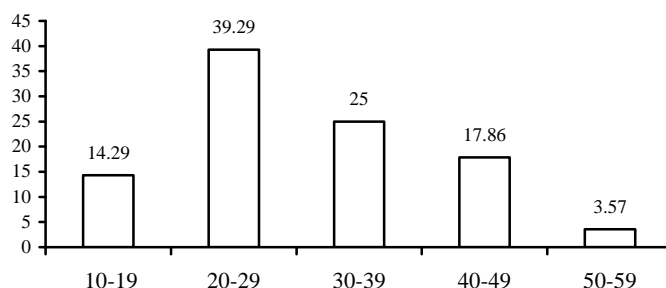
7. Performing Ham Test.

Anticoagulant therapy for each patient included heparin infusion, 1000 u/h, followed by warfarin for at least 6 month. (The duration of treatment was depended on the associated thrombophilia). Normal values for these factors were considered as table 1.

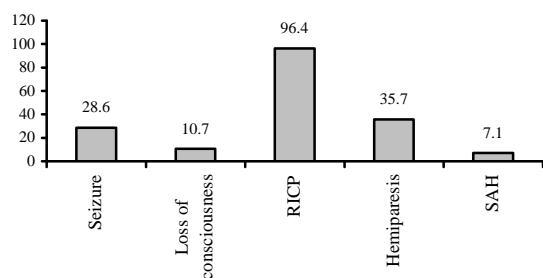
## Results

Thrombosis was mostly occurred in ages between 20-29 and was twice more in female than male, i.e. 64.3% versus 35.7% (Figure 1). Raised intracranial pressure was the most common clinical presentation. Other presenting symptoms, in order of decreasing frequencies were hemiparesis, seizure, loss of consciousness and SAH or subarachnoid hemorrhage (Figure 2).

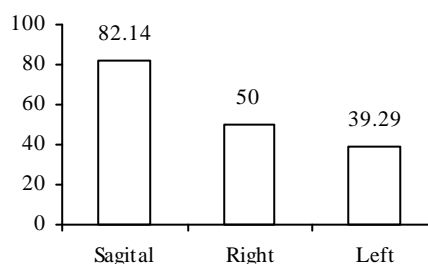
MRI imaging showed the combination of superior sagittal and right lateral sinuses to be the most common site of involvement; however the overall incidence of CVT in superior sagittal sinus was the highest (Figure 3).



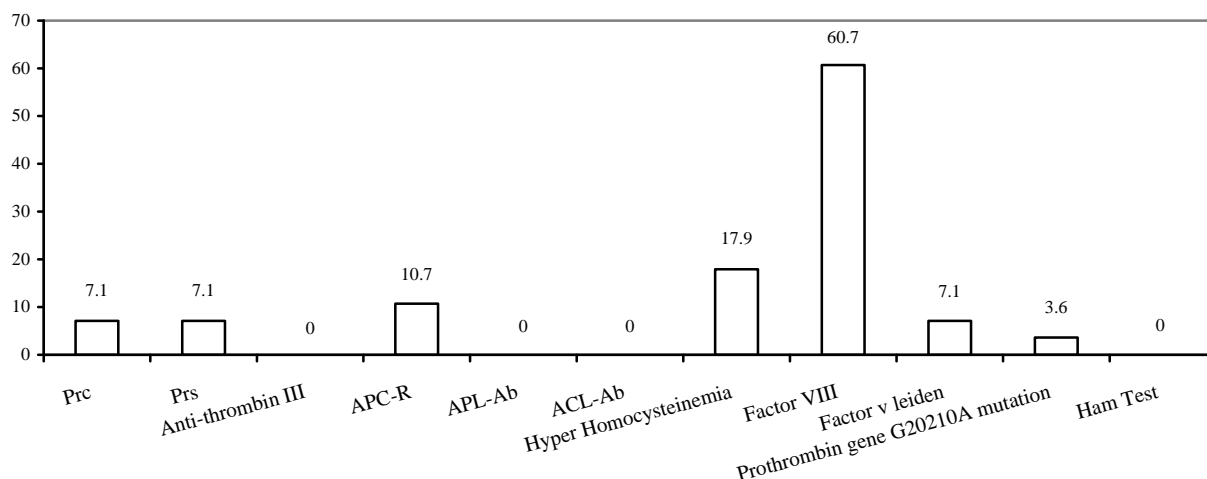
**Figure 1.** Frequency of age



**Figure 2.** Frequency of clinical presentation



**Figure 3.** Frequency of different sinus involvement



**Figure 4.** Frequency of coagulopathies

Evaluation of prothrombotic factors revealed that none of our cases had an abnormal anticardiolipin antibody, antiphospholipid antibody, and positive Ham test. One patient had prothrombin G20210A mutation (heterozygote) (3.6%). Hyperhomocysteinemia was observed in 5 patients (17.9%). Two patients had positive factor V Leiden mutation (heterozygote) (7.1%). Activated protein C resistant (APC-R) was decreased in 3 patients (10.7%). Seventeen patients had an increased factor VIII (60.7) (Figure 4).

At initial measurement, antithrombin III was decreased in 3 patients, protein C in 4 patients and protein S in 8 patients, but rechecking 3 months later (at least one week after discontinuation of anticoagulant therapy) showed only C and S proteins deficiencies, each occurring in two patients (7.1%).

## Discussion

The estimated annual incidence of cerebral vein thrombosis is 3 to 4 cases per one million and up to 7 cases per one million among children. About 75% of the adult patients are women (5). In our study the incidence of cerebral vein thrombosis, among our center admissions during the last 2 years was 4/10000.

Martinelli and his coworkers reported the median age of cerebral vein thrombosis to be 31 (ranging from 15 to 64 years). In our study this was found 28 years.

In a recent review study of thrombosis (Jan Stam 2005), severe headache reported to be the most frequent, but least specific symptom of sinus thrombosis, which occurred in more than 90% of adult patients. (5) In another study by Biousse et al (2003) focal signs such as focal deficit or partial seizures were the first and most com-

mon findings (6). In this study patients mostly had RICP symptoms (especially headache).

Some authors reported that cerebral vein thrombosis occurs most commonly in the superior sagittal sinus (7). Cakmak et al (2003) in a comprehensive review article about thrombosis reported the most frequent site of cerebral venous thrombosis as the superior sagittal sinus (81%)(4). Terazi et al (2005) in a retrospective multicenter study found that sagittal and transverse sinuses are the most common site of involvement (8). We found the most site of involvement to be the superior sagittal sinus (82.14%). Most of our patients had a combined superior sagittal and right lateral sinuses thrombosis (39.29%).

Two case-control studies have shown an increased risk of sinus thrombosis in women who use oral contraceptives (6,7) especially third generation contraceptives that contain gestodene or desogestrel(9). More recently, there has been a significant female predominance among young adults with sinus thrombosis, so that 70 to 80% of cases were women of childbearing age (10,11).

Laboratory findings support the evidence that oral contraceptives have a prothrombotic effect. The use of OCP is associated with an approximately 14-fold increased risk of CVT in the subgroup women >15 years. The risk is even larger if there is an additional hereditary prothrombotic factor (protein C, S, or antithrombin deficiency, factor V Leiden mutation). The association between oral contraceptives, thrombophilia, and deep vein thrombosis is also valid for cerebral sinus thrombosis, thus in women who have a history of venous thrombotic disease, including sinus thrombosis, use of OCP should be avoided, especially in women with a hereditary prothrombotic disorder (12). For example in one study the combination of mutations in the prothrombin and

## CVT and thrombophilic risk factors

factor V genes and the use of oral contraceptives, probably enhances their individual effects on coagulation (13). Dulli found that association of using OCP and the presence of APC-R increases the risk of CVT by 30-50 folds (14).

The presence of prothrombin polymorphism in combination with OCP increases the odd ratio of CVT by nearly 150 (15). However women do not need to stop using of oral contraceptives because the absolute risk of cerebral sinus thrombosis is very small (12). As mentioned by other studies women may need not stop using contraceptives unless there is an additional hereditary prothrombotic condition (13). In our study CVT occurred most commonly in women, most of which were using oral contraceptives (72%). This might indicate oral contraceptives as an independent factor predisposing thrombophilia, however a large number of these women also had an additional prothrombotic factor, thus the use of oral contraceptives seemed to provoke their thrombophilia. On the other hand prothrombotic factors seem to be higher in male patients than females (With the exception of prothrombin gene G20210A mutation).

Plasma level of factor VIII over 150% has already been considered a significant risk factor for deep vein thrombosis. The molecular basis of factor VIII plasma level is only partially known and depends on genetic and acquired factors. These may include chronic inflammation and acute phase reactions. A new locus on chromosome 18 has recently been shown to influence variation in factor VIII levels and susceptibility to thrombosis. In a review study by Cakmak, this factor was the most prothrombotic risk factor in CVT patients (4). The elevation of plasma factor VIII level seemed to be the most common coagulation disorder in our study (60.7%).

High plasma levels of total homocystein (tHcy) results from the interaction between genetic and acquired determinants. The latter are deficiencies of vitamins such as folic acid, pyridoxine and cobalamin, which are involved in the metabolic pathways of homocystein. Among genetic determinants is a mutation of the gene encoding 4-methylene tetra hydrofolate-reductase (MTHFR). A recent study by Martinelli and his coworkers (2003) found that hyperhomocysteinemia is associated with a 4 fold increased risk of CVT and in these cases vitamin therapy has the potential to decrease the risk of recurrence (1). Five patients in our study had positive tHcy (17.9%) 3 of these patients were man, and 2 women. MTHFR mutation was positive in 2 of them.

Protein C is a vitamin-k-dependant plasma protein and is probably one of the most important inhibitors of blood coagulation. In studies of CVT of sufficient size, protein

C and S deficiencies were found in a total of 160 reported cases in 2.5% and 1.9% respectively. Kuwahara et al (2000) in a study about C protein, reported: "thromboembolic diseases tend to occur during early adulthood when risk factors such as a history of malignancy, cigarette smoking, oral contraceptive use, pregnancy, purpura, trauma or surgery are present. Therefore life long anticoagulant therapy should be continued for patients with cerebral venous thrombosis caused by protein C deficiency and a history of thromboembolic diseases" (16). Four of our patients were detected with decreased protein C at initial test, but after 3 month recheck Protein C stayed abnormal in only two of them (7.1%).

Protein S deficiency has been reported in isolated cases of CVT, in 2 of 46 patients in Mexican series, and in 3 of 40 patients from Saudi Arabia; in one of these 3 patients, the low protein S level was transitory, and no information was given concerning the methods used for assays. Deschiens (1996) in a study on 40 cases of CVT suggests that it is important to confirm protein S deficiency long enough after the CVT because acquired deficiencies may be present during the acute phase of thrombosis, possibly related to excessive binding to C4b binding protein or because patients are pregnant or taking contraceptive pills. In her study no other cause or associated factor was present in the patient with PS deficiency. In her study six cases of thrombophilia (15%) were found: 1 protein C deficiency, 1 protein S deficiency, and 4 activated protein C resistance with heterozygous factor V Leiden mutation (10%) (3). Our 3 patients with abnormal protein S declined to two after second recheck (3 month later).

The molecular basis for the thrombophilia in many, but by no means all patients with APC-R, is the presence of a modified factor V Leiden that is resistant to cleavage by protein C. The evidence that persons with APC-R who do not have the factor V Leiden mutation also have a degree of thrombophilia is compelling, but the mechanism of the APC-R is unknown. Dulli and his coworkers (1996) performed a case study and suggested that APC-R should be looked for in all patients with CVT.

Functional APC-R is a highly prevalent coagulopathy, but the reasons for this abnormality are diverse. Abnormal and borderline functional APC-R results should be supplemented by DNA analysis for the presence of factor V Leiden (14).

In a case control study by Zuber et al, 19 unselected patients with CVT and 57 healthy control subjects were tested for the mutation in factor V Leiden (17). He found that in patients with CVT, the prevalence of factor V

mutation ranged from 12% to 20%, a rate significantly higher than in the general population (3% to 6%). He concluded that factor V mutation may be the most common inherited coagulopathy associated with CVT (17). In another study the frequency of this factor was about 10% (3). In our study three of the patients had abnormal APC-R; mutation in factor V Leiden (heterozygote) was detected in two of them, (both male).

CVT occasionally has been reported with ACL-ab, but other predisposing factors such as pregnancy, nephritic syndrome or postpartum were also frequently present. This suggests that factors other than ACL alone are important to induce CVT. In study by Deschiens.M on 40 patients with CVT, Three patients (8%) had increased anticardiolipin antibodies: 1 with systemic lupus and 2 with primary antiphospholipid syndrome (18). In our study this factor was not detected in any of the cases.

A 21 KB gene located on chromosome 11p11 to q12, encodes prothrombin. Patients with the mutation (20210A) have higher plasma prothrombin concentrations than controls with the normal genotype (20210G), suggesting that hypercoagulability is due to hyper activity of the common coagulation pathway resulting in increased thrombin production (19). The prothrombin polymorphism is found at a rate of about 2 to 3% in the healthy population. This polymorphism increases the relative risk for venous thrombosis about 8-fold and is found in about 6% of patients with a first ever episode of venous thromboembolism. A similar prevalence is found in CVT patients (20). G20210A mutation in the prothrombin gene represents a risk factor for CVT, making it the second most common hereditary thrombophilia after the factor V Leiden mutation (19). However the mutation obviously does not increase the risk for acute ischemic stroke or TIA (21). In a study by Stolz et al (2000) the frequency of prothrombin mutation G20210A was found about 8.7% (15). Karl (1998) reported that this mutation increases the relative risk for CVT approximately 5-fold (21). The frequency of 1 patient (3.6%) identified in our study may comply with these data's.

Despite improved diagnostic capabilities, about 30% of CVT were classified as idiopathic (22). 36% of the patients were found to have an inherited coagulopathy and the prevalence of other risk factors was high with 74% (15). In our study 25 % of the patients seemed to have an inherited coagulopathy whereas no underlying etiologic factor was detected in 35%. The frequency of other risk factors was about 65% supporting the impression of a multipotential process. Isolated hereditary thrombophilias as a cause of CVT seem to be rare in the absence

of other factors. In study by Deschiens et al (1996) and other occasional cases, only the patient with protein S deficiency having no other predisposing factor (18). In our study, any patient had isolated hereditary thrombophilia.

In conclusion our study suggests that, coagulopathies have a major role in dural sinus thrombosis and detection of various derangements can be an important determinant in decision about duration of treatment.

## References

1. Martinelli I, Battaglioli T, Pedotti P, Cattaneo M, Mannucci PM. Hyperhomocysteinemia in cerebral vein thrombosis. *Blood* 2003; 102(4): 1363-6.
2. Dulli DA, Luzzio CC, Williams EC, Schutta HS. Cerebral venous thrombosis and activated protein C resistance. *Stroke* 1996; 27(10): 1731-3.
3. Deschiens MA, Conard J, Horellou MH, Ameri A, Preter M, Chedru F, et al. Coagulation studies, factor V Leiden, and anticardiolipin antibodies in 40 cases of cerebral venous thrombosis. *Stroke* 1996; 27(10): 1724-30.
4. Cakmak S, Derex L, Berruyer M, Nighoghossian N, Philippeau F, Adeleine P, et al. Cerebral venous thrombosis: clinical outcome and systematic screening of prothrombotic factors. *Neurology* 2003; 60(7): 1175-8.
5. Stam J. Thrombosis of the cerebral veins and sinuses. *N Engl J Med* 2005; 352(17): 1791-8.
6. Biousse V, Tong F, Newman NJ. Cerebral Venous Thrombosis. *Curr Treat Options Cardiovasc Med* 2003; 5(3): 181-192.
7. Bradley WG, Daroff RB, Fenichel GM, Jankovic J. *Neurology in Clinical Practice*. 4<sup>th</sup> ed. Philadelphia: Butterworth Heinemann; 2004.
8. Terazzi E, Mittino D, Rudà R, Cerrato P, Monaco F, Sciolla R, et al. Cerebral venous thrombosis: a retrospective multicentre study of 48 patients. *Neurol Sci* 2005; 25(6): 311-5.
9. de Bruijn SF, Stam J, Vandenbroucke JP. Increased risk of cerebral venous sinus thrombosis with third-generation oral contraceptives. Cerebral Venous Sinus Thrombosis Study Group. *Lancet* 1998; 351(9113): 1404.
10. Ferro JM, Canhã P, Stam J, Boussier MG, Barinagarrementeria F; ISCVT Investigators. Prognosis of cerebral vein and dural sinus thrombosis: results of the International Study on Cerebral Vein and Dural Sinus Thrombosis (ISCVT). *Stroke* 2004; 35(3): 664-70.
11. deVeber G, Andrew M, Adams C, Bjornson B, Booth F, Buckley DJ, et al. Cerebral sinovenous thrombosis in children. *N Engl J Med* 2001; 345(6): 417-23.

## CVT and thrombophilic risk factors

12. de Bruijn SF, Stam J, Koopman MM, Vandenbroucke JP. Case-control study of risk of cerebral sinus thrombosis in oral contraceptive users and in [correction of who are] carriers of hereditary prothrombotic conditions. The Cerebral Venous Sinus Thrombosis Study Group. *BMJ* 1998; 316(7131): 589-92.
13. Martinelli I, Sacchi E, Landi G, Taioli E, Duca F, Mannucci PM. High risk of cerebral-vein thrombosis in carriers of a prothrombin-gene mutation and in users of oral contraceptives. *N Engl J Med* 1998; 338(25): 1793-7.
14. Dulli DA, Luzzio CC, Williams EC, Schutta HS. Cerebral venous thrombosis and activated protein C resistance. *Stroke* 1996; 27(10): 1731-3.
15. Stolz E, Kemkes-Matthes B, Pötzsch B, Hahn M, Kraus J, Wirbartz A, et al. Screening for thrombophilic risk factors among 25 German patients with cerebral venous thrombosis. *Acta Neurol Scand* 2000; 102(1): 31-6.
16. Kuwahara S, Abe T, Uga S, Mori K. Superior sagittal sinus and cerebral cortical venous thrombosis caused by congenital protein C deficiency: case report. *Neurol Med Chir (Tokyo)* 2000; 40(12): 645-9.
17. Zuber M, Toulon P, Marnet L, Mas JL. Factor V Leiden mutation in cerebral venous thrombosis. *Stroke* 1996; 27(10): 1721-3.
18. Deschiens MA, Conard J, Horellou MH, Ameri A, Preter M, Chedru F, et al. Coagulation studies, factor V Leiden, and anticardiolipin antibodies in 40 cases of cerebral venous thrombosis. *Stroke* 1996; 27(10): 1724-30.
19. Kellett MW, Martin PJ, Enevoldson TP, Brammer C, Toh CM. Cerebral venous sinus thrombosis associated with 20210A mutation of the prothrombin gene. *J Neurol Neurosurg Psychiatry* 1998; 65(4): 611-2.
20. Lane DA, Mannucci PM, Bauer KA, Bertina RM, Bochkov NP, Boulyjenkov V, et al. Inherited thrombophilia: Part 1. *Thromb Haemost* 1996; 76(5): 651-62.
21. Karl H. Prothrombin gene G20210A transition is a risk factor for cerebral venous Thrombosis. *Stroke* 1998; 29: 1765-69.
22. Ameri A, Bousser MG. Cerebral venous thrombosis. *Neurol Clin* 1992; 10(1): 87-111.