

## Phenotypic and Cytogenetic Variety of Pure Partial Trisomy of Chromosome 16p

Mehrdad Noruzinia<sup>\*1</sup>, Genevieve Lefort<sup>2</sup>, Anne Marie Chaze<sup>2</sup>, Jacques Puechberty<sup>2,3</sup>, Franck Pellestor<sup>3</sup>, Patricia Blanchet<sup>2</sup>, Valerie Cacheux<sup>2</sup>, and Pierre Sarda<sup>2</sup>

<sup>1</sup> Department of Hematology, School of Medicine, Tarbiat Modares University of Medical Sciences, Tehran, Iran

<sup>2</sup> Service de Génétique médicale, CHU Arnaud de Villeneuve, Montpellier, France

<sup>3</sup> IGH-CNRS, UPR1142, Montpellier, France

Received: 3 Aug. 2007; Received in revised form: 13 Nov. 2007; Accepted: 13 Jan. 2008

**Abstract-** Duplications of chromosome 16p are often the products of unbalanced maternal reciprocal translocations and consequently the phenotype of patients is not typical of pure partial trisomy 16p. R-banding and fluorescence in situ hybridization (FISH) in our patients were in favour of *de novo* pure partial trisomy of 16p. Further clinical and paraclinical analysis of our three cases in addition to a review of literature and analysis of published clinical and cytogenetic data on five cases of pure partial duplications of chromosome 16p reported until now lead to the delineation of three groups of duplications. Patients with short proximal 16p11~p12 euchromatic duplication considered as "silent" duplication and no clinical anomaly are included in the first group. The second group with a larger 16p11-p12~p13 duplication is characterised by a particular phenotype including severe mental retardation, dysmorphism, variable malformations and recurrent infections. The third group has terminal 16p13-pter duplication and is not well defined to date. Based on our cases and reported cases of pure partial trisomy of 16p in the literature we propose diagnostic measures in case of an elongated 16p chromosome encountered in prenatal chromosome analysis.

© 2009 Tehran University of Medical Sciences. All rights reserved.

*Acta Medica Iranica* 2009; 47(3): 233-240.

**Key words:** Chromosome 16, pure partial trisomy, interstitial duplication

### Introduction

Complete trisomy 16 is one of the most common chromosomal anomalies found in first trimester spontaneous abortions but has never been reported in liveborns (1).

However, mosaic trisomy 16 and partial duplication of chromosome 16 [dup(16)] have been reported in liveborns (2, 3). Most of the cases described are unbalanced products of maternal reciprocal translocations and the specific phenotypes reported for pure dup16p concern only a limited number of patients. To date only five cases of *de novo* trisomy 16p with abnormal phenotype have been reported (3-7). We report the clinical and cytogenetic data of three new cases of pure trisomy 16p, and in the light of these observations discuss the phenotypes of these chromosomal anomalies.

### Case Reports

#### Case one

The proposita is the second child of healthy, unrelated parents with an unremarkable family history. The

mother and the father were aged 29 and 36 years respectively at the time of the infant's birth. The pregnancy was uneventful until 24 WG (weeks' gestation) when ultrasonographic examination suspected Intrauterine growth retardation (IUGR) which was not confirmed at birth. At 39 WG a baby girl was delivered. Weight was 2900g, length 49cm and occipitofrontal circumference (OFC) 33.5 cm.

At birth the baby was hypotonic and showed dysmorphic traits. Later on seizures occurred and early psychomotor developmental delay was apparent.

The child sat at the age of 2 years and did not walk and had no language at the age of 28 months. At the age of 8 months ventricular and atrial septal defects were noted as well as right vesicoureteral reflux. She had recurrent otitis. At the age of 28 months the child is hypotrophic with *ertelorism*, retrognathia, small nose with broad nasal bridge, everted upper lip, long philtrum, posteriorly rotated and dysplastic ears with short neck and excess of skin, low set and inverted breast nipples, large hands with arachnodactyly and adducted thumbs.

\*Corresponding Author: Mehrdad Noruzinia

Department of Hematology, School of Medicine, Tarbiat Modares University of Medical Sciences, Tehran, Iran  
Tel: +98 21 82883860, Fax: +98 21 88013030, E-mail: Mehrdad.noruzinia@modares.ac.ir

## Pure partial 16p duplication

The proposita has mild hearing loss and ophthalmologic examination revealed bilateral strabismus, bilateral excavations of optic nerves' head due to coloboma anomaly, left eye amblyopia and severe loss of visual acuity on the right side.

Magnetic Resonance Imaging (MRI) reveals an increased pericerebral space and ventricular dilatation.

### Case two

The proposita is the first child of healthy unrelated parents. The father and mother were aged 26 and 27 years respectively at the time of her birth. Pregnancy was uneventful and a baby girl was born at term. Weight was 3180 g, length 48 cm and OFC 34.5 cm. During the first weeks the baby was hypotonic and had difficulty breast-feeding. Submucous cleft palate and micrognathia were noted at the age of one month. Later she developed psychomotor retardation. She sat at the age of 1 year and began to walk unaided at the age of 2 years. Umbilical hernia required surgical intervention at the age of 4 months and submucous cleft palate was repaired at the age of 1 year. Meckel's diverticulum was noted during abdominal surgical intervention. The proposita had frequent episodes of otitis and pulmonary infection.

At the age of 16 years she has no language and presents severe mental retardation and behavioral disorders including hyperactivity and autoaggressivity. Weight, height and OFC are normal (measurements between mean and -1 SD). Dysmorphic traits include: scaphocephaly, narrow forehead, hypertelorism with upslanting palpebral fissures, broad and prominent nasal bridge with broad nasal tip, big mouth with a thick upper lip, long philtrum, micrognathia and large ears. Brachydactyly, spindle shaped fingers and 3-4 cutaneous syndactyly were present.

She has mild hearing loss secondary to recurrent otitis and no visual impairment.

Sexual development is normal. cerebral CT (computerized tomography) scan shows no malformation.

### Case three

This boy is the first infant of a young couple. The mother is a healthy G5P2 woman with a history of two miscarriages and one neonatal death. She had been adopted as an infant and we thus have no information regarding her family history. However we do know that she was dyslexic during infancy.

The father is healthy but has a heavy family history of severe psychotic disorders. Bipolar mood disorder

and schizophrenia have been found in his mother as well as 4 other maternal family members.

The mother and father were aged 33 and 30 years respectively at the time of pregnancy. The pregnancy was uneventful and led to the term birth of a boy with weight 3300 g, length 50 cm and OFC 34 cm.

The newborn had no problem except for difficulty breast-feeding. Mild hypotonia was noted at the age of 1 year and the propositus walked unaided at 18 months. Acquisition of language was delayed and diagnosis of mutism was suspected at the age of 4 years. However after this age, the boy progressively acquired language skills.

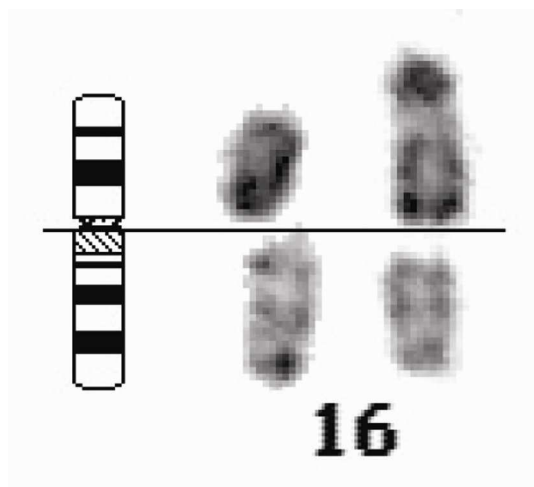
At 12 years he has psychoaffective disorder with a high level of anxiety and depression. These traits are accompanied by scholastic learning disability. He has no abnormal movements or tics.

Motor performance is normal and he presents no specific dysmorphic traits except for a long face and mild strabismus. Height and weight are in the normal range but OFC is 52cm (-1.5SD).

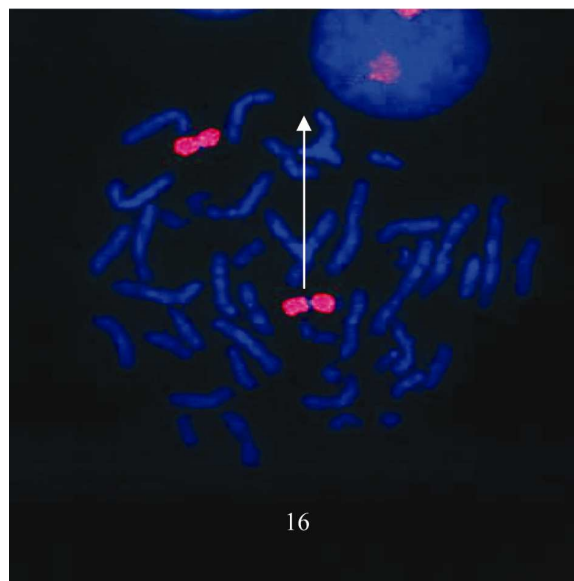
### Cytogenetic studies

Peripheral blood samples of the patients and their parents were used for cytogenetic studies. R-banding and fluorescence in situ hybridization (FISH) using painting and specific subtelomeric probes were performed according to standard protocols and probe suppliers' recommendations on all samples (8). For patient one and his father C-banding (8) was also performed. FISH slides were visualized on a Zeiss Axioplan 2 fluorescence microscope and analyzed with an image processor (Imstar, Paris, France). In case one, karyotype analysis on banded chromosomes showed an elongated short arm for one chromosome 16. FISH with wcp (whole chromosome paint, Q-Biogene, Illkirch, France) 16 painted the entire elongated chromosome 16. FISH with subtel 16p probe (Vysis, Downers Grove, IL.) was positive for the elongated 16p. Parents chromosome studies with R-banding and FISH (wcp16 and tel 16p) showed normal chromosomes 16. The combined results from R-banding pattern and FISH studies were in favor of a "de novo" interstitial 16p duplication. The duplicated region was interpreted as 16p11-p13 (Figure 1).

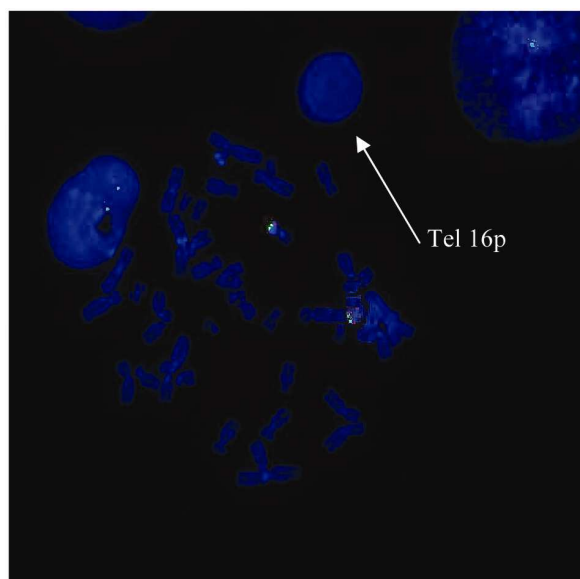
In addition, R-banding pattern suggested an abnormal chromosome 4q in the patient and his father. Further studies by C-banding and chromosome 4 painting was in favor of a satellited chromosome 4q inherited through the father.



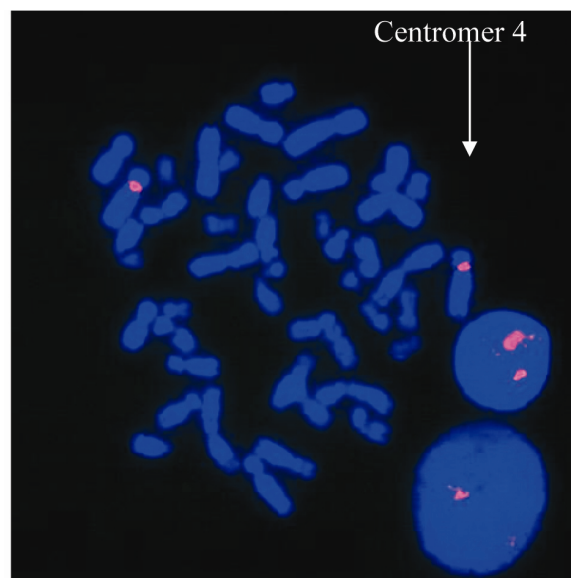
a



b



b



c

**Figure 1.** First patient

a : Partial R-banded karyotype showing chromosomes 16

b : FISH with whole chromosome 16 paint

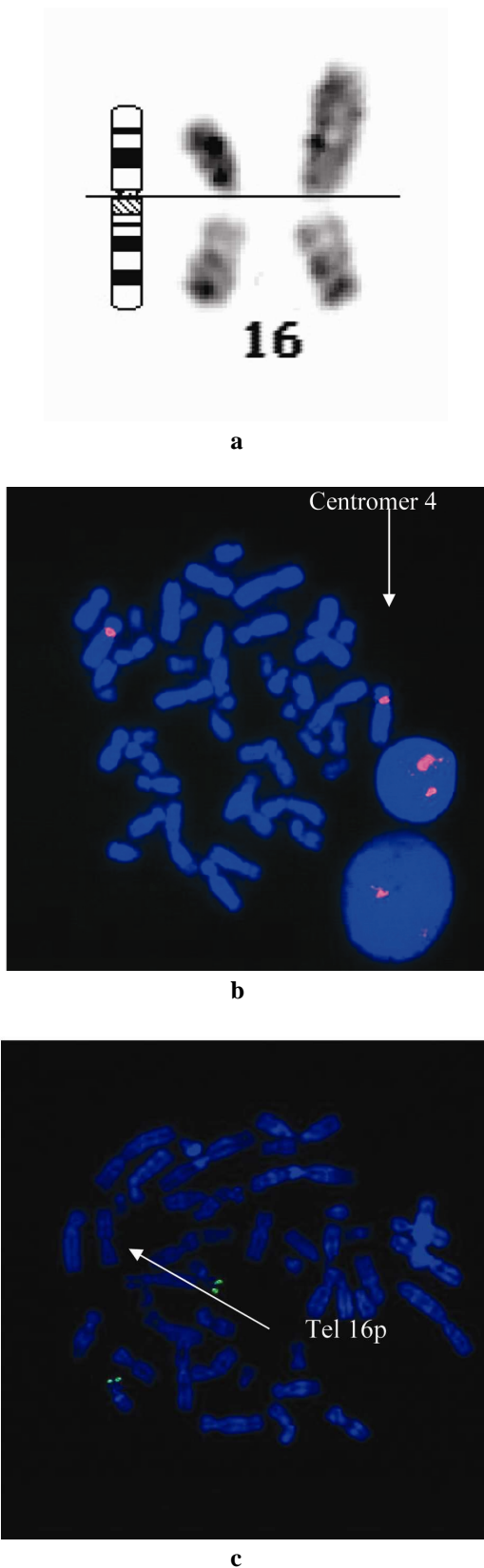
c : FISH with tel 16p probe

d : FISH with centromeric chromosome 4 probe

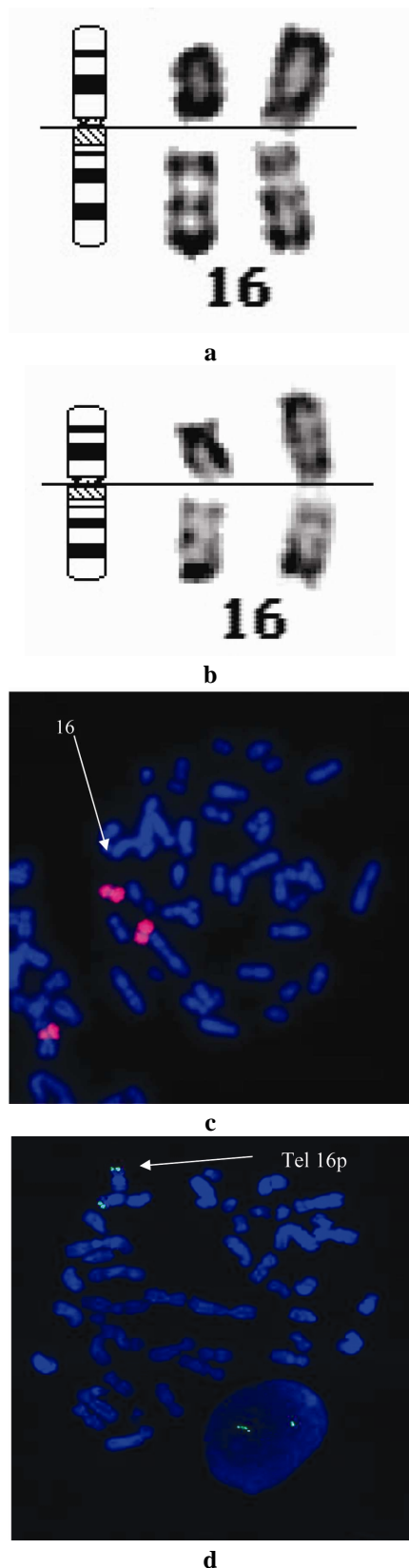
In case two, karyotype analysis of chromosomes 16 in the patient and her parents showed the same results as

in case one. The proposita was diagnosed as having a "de novo" 16p11-p13 duplication (Figure 2).

Pure partial 16p duplication



**Figure 2.** Second patient  
 a : Partial R-banded karyotype showing chromosomes 16  
 b : FISH with whole chromosome 16 paint  
 c : FISH with tel 16p probe



**Figure 3.** Third patient (a,c and d) and his mother (b)  
 a and b: Partial R-banded karyotype showing chromosomes 16  
 c: FISH with whole chromosome 16 paint  
 d : FISH with tel 16p probe

In case three, chromosome analysis with R-banding showed an elongated chromosome 16 short arm in the patient and his mother. FISH with wcp 16 painted the entire chromosome 16 and subtel 16p probe was positive in the patient and his mother. The father's karyotype was normal. According to the R-banding pattern and FISH studies the anomaly was interpreted as a proximal 16p11-p12 duplication inherited through the mother (Figure 3).

## Discussion

Partial trisomy 16p is a rare chromosomal anomaly. One of the difficulties in the cytogenetic diagnosis of 16p anomalies is the precise determination of the duplicated region. To date at least thirty two cases of this anomaly have been reported (2-6,9-10). Twenty seven of these duplications are not pure but are the unbalanced products of a parental reciprocal translocation (2,3).

Only five cases of pure partial trisomy 16p with phenotypic anomalies have been reported (3-6,7).

"Silent" euchromatic duplications of proximal 16p have also been reported. All cases were inherited (7,9,11-13). Our third case which concerns a 16 year-old-boy with a proximal 16p duplication inherited through his mother, seems to fall into this category. The boy has no malformations or dysmorphisms. Although he presents major psychoaffective disorder associated with scholastic learning disabilities, the relationship between this phenotype and dup16p inherited through his normal mother is not evident. The psychoaffective disorder in this patient might be at least partially related to the psychiatric history in the father's family.

Recently Engelen (2002) reported a proximal 16p duplication (p11.2-p12.1) with developmental retardation and psychiatric symptoms in a 40-year-old mother and her 6-year-old daughter. These patients presented microcephaly and short stature (3<sup>rd</sup> percentile) which was postnatal in the daughter (unknown for the mother). The daughter also had upslanting palpebral fissures. After a review of literature, the authors propose that proximal 16p duplication is accompanied by psychomotor retardation and developmental delay and seems to be responsible for mild facial dysmorphism. F.Natacci (2002) report an interesting case of pure partial proximal 16p (p11.2-p12.2) duplication in a 23-year-old dysmorphic patient with severe mental retardation and autistic behaviour.

Our cases one and two have interstitial 16p11-p13 duplication. As R and G-banding are not always sufficient to differentiate interstitial and terminal duplications, FISH with wcp16 and specific subtelomeric 16p

probes were performed in our patients and confirmed interstitial duplication.

The comparison of these two cases with the four cases of 16p duplication including the p11-p12~p13 region reported in the literature (Table 1) allows to delineate a recognizable phenotype including severe mental retardation, dysmorphism, variable malformations and recurrent infections. At birth the infants are mostly eutrophic. Dysmorphic features include: craniosynostosis, large prominent forehead, hypertelorism, prominent glabella, small palpebral fissures, prominent maxilla, long philtrum, thin upper lip. Ears may appear prominent and dysplastic with a prominent anthelix. The neck is short. Most infants have umbilical or inguinal hernia or diastasis recti. Fingers are spindle shaped with variable minor deformations. Other malformations can be present: cerebral, digestive, renal and genital. Most patients present recurrent infections notably respiratory and ear infections. Severe mental retardation is a constant finding and seizures can occur.

In addition to 16p duplication, case one presents with a satellited chromosome 4q which was inherited through the father. To date six cases of satellited chromosome 4q have been reported (14-19). Two cases had an abnormal phenotype (one case with craniorachischisis and one case with cerebellar ataxia and mental retardation). However in both cases the authors suggest a fortuitous association between the physical abnormality and the chromosomal abnormality. It is probable that in our patient the inherited satellited chromosome 4q does not contribute to the phenotype.

Only two patients of a suspected terminal 16p duplication (16p13-pter duplication) have been reported (6,10).

The first patient presented an autistic disorder and Tourette's syndrome. A de novo 16p13-pter duplication was detected through an elongated chromosome 16p. The banding pattern was abnormal and compatible with distal 16p13.1-pter duplication. The report of this patient with autistic disorder and Tourette's syndrome associated with dup16p is unique. However linkage studies and systematic gene scan in Tourette patients have to date never shown a linkage with chromosome 16. Moreover, a gene implicated in Tourette's syndrome has been located on chromosome 11q23. The second patient presented multiple congenital anomalies.

Based on our three observations and a review of the literature we propose that three categories of trisomy 16p be defined. The first group commonly called silent euchromatic proximal 16p duplication is generally inherited and has no specific dysmorphic feature. Some cases

**Pure partial 16p duplication**

**Table 1.** Anomalies in patients with pure 16p11-p12~p13 duplication

	Dallapicola 1979 <sup>4</sup>	Llamas 1981 <sup>5</sup>	Corrasco 1997 <sup>3</sup>	Natacci 2002 <sup>7</sup>	Engelen 2002 <sup>8</sup>	Case 1	Case 2
Chromosomal abnormality	q11-pter	q11-pter	p11.2-p12	P12.1-12.2	P11.2-12.1	p11-p13	p11-p13
Birth weight	2800	3300	3700	?	4050	2900	3180
Birth length	48	51	?	?	51	49	48
Psychomotor delay	+	+	+	+	-	+	+
Round face	+	+	+	-	-	-	-
Frontal bossing	+/-?wide frontal bone	+/-?	+	+	-	+	-
Hypertelorism	+	+	+	+	-	+	+
Short palpebral fissures	+	+	+	-	-	-	+
Strabismus	-	-	+		-	+	-
Nystagmus	+	+	-		-	-	-
Broad nasal bridge	+	+	+	-	-	+	+
Anteverted nostrils	+	+	?	+	-	-	+
Prominent maxilla	+	+	?	+	-	+	+
Thin upper lip	+	+	?	-	-	+	-
Long philtrum	-	+	+	-	-	+	+
Low set ears	+	+	+	+	-	-	-
Dysplastic ears	+	+	+/-	+	-	+	+
Short neck	+	+	+	-	-	+	-
Excess skin of neck	?	?	?	-	-	+	-
Spindle shaped fingers	- tapered	?	?	?	-	+	+
Cerebral atrophy	?	+	?	+	-	+	-
Ocular malformation	Glaucoma	?	Microphthalmia		?	Coloboma	-
Cleft hard palate	-	-	+	+	?	-	+
Craniosynostosis	+	+	-	-	-	-	+
Cardiac malformation	-	-	-	-	-	+	-
Umbilical or inguinal hernia	+	+	?	-	-	-	+
Ureteric abnormalities	?	?	?	-	-	+	-
Single umbilical artery	?	?	+	?	-	?	?
Hypospadias	-	+	-	-	-	-	-
Mental retardation	+	+	+	+	mild	+	+
Seizures	+	-	+	+	-	+	-
Truncal hypotonia	?	?	+	-	-	+	+
Peripheral hypertonia	+ spastic	+	?	-	-	-	-
Recurrent infections	?	?	+	+	-	+	+

reported in the literature and our third case show a constellation of psychiatric or mood disorders.

The second group includes the larger 16p11-p12~p13 duplication. Patients have severe mental retardation, dysmorphism, and recurrent infections (Table 1). All show variable malformations but these malformations could be difficult to detect on foetal ultrasound.

The third group pure terminal 16p13-pter duplication is not well defined to date because of small number of reported cases.

Duplication of chromosome 16p can cause MR/MCA. When an elongated 16p is discovered at prenatal diagnosis, the primary concern is to differentiate between a silent euchromatic variant 16p and a 16p duplication with clinical manifestations. This necessitates parental chromosomal studies and should include FISH studies with painting and subtelomeric 16p probes.

The report of Engelen et al. of an isolated mild MR in dup 16p11-p12.1 points to the persistent difficulty in defining a precise phenotype. However, in case of a de novo duplication involving p11-p12, the apparent silent region, one must remain prudent concerning prognosis until the precise distal limit of the silent euchromatine duplication has been defined. When chromosome studies are performed post-natally, the MCA phenotype described above should suggest the possibility of 16p duplication.

## Acknowledgments

This study was supported by a grant from CHU Arnauld de villeneuve.

## References

- Schinzl A. Catalogue of unbalanced chromosome aberrations in man. New York: Walter de Gruyter; 1984.
- Preis W, Barbi G, Liptay S, Kennerknecht I, Schwemmler S, Pohlandt F. X/autosome translocation in three generations ascertained through an infant with trisomy 16p due to failure of spreading of X-inactivation. *Am J Med Genet* 1996; 61(2): 117-21.
- Carrasco Juan JL, Cigudosa JC, Otero Gómez A, Acosta Almeida MT, García Miranda JL. De novo trisomy 16p. *Am J Med Genet* 1997; 68(2): 219-21.
- Dallapiccola B, Curatolo P, Balestrazzi P. 'De novo' trisomy 16q11 to pter. *Hum Genet* 1979; 49(1): 1-6.
- Gabarrón Llamas J, Cabrerizo Portero D, Montserrat Bernal F, Rodríguez Costa T, Cabrerizo Merino C, Rodríguez López F. "De novo" partial trisomy 16p (author's transl). *An Esp Pediatr* 1981; 15(6): 587-91.
- Hebebrand J, Martin M, Körner J, Roitzheim B, de Braganca K, Werner W, et al. Partial trisomy 16p in an adolescent with autistic disorder and Tourette's syndrome. *Am J Med Genet* 1994; 54(3): 268-70.
- Natacci F, Finelli P, Gottardi G, Zuccarini C, Giardino D, Sala M, et al. FISH characterization of 16p11.2-p12.2 tandem duplication in a dysmorphic patient with severe mental retardation and autistic behaviour. [online] 2002 May 25-28; European Society of Human Genetics Posters: P 15 Mental Retardation. Available from: URL:<http://www.medacad.org/eshg/abstracts/posters15.htm>
- Rooney DE, Czepulkowski BH, editors. *Human Cytogenetics: A Practical Approach: Constitutional Analysis*. 2<sup>nd</sup> ed. New York: Oxford University Press; 2001.
- Engelen JJ, de Die-Smulders CE, Dirckx R, Verhoeven WM, Tuinier S, Curfs LM, et al. Duplication of chromosome region (16)(p11.2 --> p12.1) in a mother and daughter with mild mental retardation. *Am J Med Genet* 2002; 109(2): 149-53.
- Tschernigg M, Petek E, Leonhardtsberger A, Wagner K, Kroisel PM. Terminal tandem duplication of 16p: a case with "pure" partial trisomy (16)(pter-->p13). *Genet Couns* 2002; 13(3): 303-7.
- Stéphane P, Geneviève L. Prenatal supernumerary r(16) chromosome characterized by multiprobe FISH with normal pregnancy outcome. *Prenat Diagn* 1999; 19(2): 181-2.
- Jalal SM, Day DW, Garcia M, Benjamin T, Rogers J. Familial transmission of 16p trisomy in an infant. *Hum Genet* 1989; 81(2): 196-8.
- Barber JC, Reed CJ, Dahoun SP, Joyce CA. Amplification of a pseudogene cassette underlies euchromatic variation of 16p at the cytogenetic level. *Hum Genet* 1999; 104(3): 211-8.
- Arn PH, Younie L, Russo S, Zackowski JL, Mankinen C, Estabrooks L. Reproductive outcome in 3 families with a satellited chromosome 4 with review of the literature. *Am J Med Genet* 1995; 57(3): 420-4.
- Babu VR, Roberson JR, Van Dyke DL, Weiss L. Interstitial deletion of 4q35 in a familial satellited 4q in a child with developmental delay. *Am J Hum Genet*; 41(Suppl): A113.
- Mihelick K, Jackson-Cook C, Hays P, Flannery DB, Brown JA. Craniorachischisis in a fetus with familial satellited 4q. *Am J Hum Genet Suppl* 1984; 36: 105S.
- Miller I, Songster G, Fontana S, Hsieh CL. Satellited 4q identified in amniotic fluid cells. *Am J Med Genet* 1995; 55(2): 237-9.
- Shah HO, Verma RS, Conte RA, Chester M, Shklovskaya TV, Kleyman SM, et al. Fishing for the origin of satellite on the long arm of chromosome 4. *Am J Hum Genet Suppl* 1997; 61: A375.

### **Pure partial 16p duplication**

19. Faivre L, Radford I, Viot G, Edery P, Munnich A, Tardieu M, et al. Cerebellar ataxia and mental retardation in a child with an inherited satellited chromosome 4q. *Ann Genet.* 2000; 43(1): 35-8.